

COMPLETE CASE HISTORIES FROM TEXTBOOK: *INTEGRATED NEUROSCIENCES*
PART IV. CASES; CEREBRUM VISION, DISEASES, MEMORY

CHAPTER 23: VISUAL SYSTEM

The following case is an example of a lesion involving the optic nerve, anterior to the optic chiasm.

Case History 23-1 (Fig 23-8).

This 53-year-old white right-handed housewife was referred for evaluation of progressive right-sided supraorbital headache of 23 years duration and decreasing acuity in the right eye. The loss of acuity had progressed to the point of almost total unilateral blindness. During the 3 years before admission, intermittent tingling paresthesia had been noted in the left face, arm, or leg. About 1 year before admission the patient had a sudden loss of consciousness and was amnesic for the events of the next 48 hours. She was hospitalized, but no explanation for the episode was clearly established, although cerebrospinal fluid protein was reported to be elevated (230 mg/dl).

The patient and her family reported some personality changes over a period of several years, including a loss of spontaneity and increasing apathy.

General Physical Examination: Unremarkable except for a minor degree of proptosis (downward protrusion of the right eye).

Neurologic Examination:

1. *Mental Status*: The patient was, in general, alert but at times would become lethargic. Her affect was flat. At times, she would laugh or joke in an inappropriate manner.
2. *Cranial Nerves*: There was anosmia for odors, such as cloves, on the right and a reduced sensitivity on the left.

Marked papilledema (increased intracranial pressure with protrusion of the optic disk and venous engorgement due to obstruction of the normal flow of CSF) was present in the left eye.

Pallor of the right optic disc was present, indicating optic atrophy. Visual acuity in the right eye was markedly reduced. The patient had only a small crescent of vision in the temporal field of the right eye, where only vague outlines of objects could be seen. A slight left central facial weakness was present.

3. *Motor Systems*: Intact although movements on the left side were slow.

4. *Reflexes*: A release of grasp reflex was present on the left side.

5. *Sensory system*: Intact

Clinical diagnosis: Subfrontal meningioma arising from olfactory groove or inner third sphenoid wing.

Laboratory data:

1. *Skull x-rays* demonstrated erosion of the dorsum sellae. Special lamniograms demonstrated hyperostosis of the sphenoid bone (planum sphenoidale) suggesting a meningioma originating from the sphenoid bone.

2. *EEG* demonstrated focal 2-4 Hz slow waves in the right anterior temporal and anterior lateral frontal area.

3. *Brain scan (H_g 197)* revealed a heavy uptake of isotope in the right posterior subfrontal area.

4. *Arteriograms* indicated that the anterior cerebral arteries were shifted backwards, posteriorly and the left. A tumor blush was present on the venous phase in the right subfrontal area extending back to the optic nerve groove (Fig 23-8). These findings were felt to be most consistent with an olfactory groove meningioma.

Hospital course: Dr. Samuel Brendler performed a bifrontal craniotomy which exposed a well-encapsulated smooth tumor attached to the medial third of the sphenoid wing. After intracapsular removal of 90 to 95% of the tumor, the right optic nerve could be visualized. The small portion of the tumor attached to the bone could not be removed because of considerable bleeding from the bone. Examination 4 months after surgery, indicated right anosmia and right optic atrophy were present.

Comment

If one considered only the patient's primary complaint, decreasing vision in the right eye, and the findings of right optic atrophy and left-sided papilledema (Foster-Kennedy syndrome), then the most probable diagnosis was inner-third sphenoid meningioma. The preservation of a small crescent of vision in the temporal field is consistent with compression of the optic nerve on its lateral surface. By the time of hospitalization, the lesion was quite large and had extended into the subfrontal area, producing anosmia on the right and some changes in personality. At this point, the various diagnostic studies suggested only a subfrontal mass and did not clearly differentiate between an olfactory-groove meningioma and a sphenoid-wing meningioma. One might suggest, in retrospect, that the degree of involvement of the right optic nerve was much more pronounced than the changes in prefrontal functions, and therefore, the inner-third sphenoid-wing location was more likely.

The surgical approach in any case was the same. The eventual recovery of vision in such cases is uncertain because the effects of compression often are not reversible.

The following case 23-2 provides an example of a macroadenoma of the pituitary producing a bitemporal adenoma..

Case 23-2. Patient of Dr. Martha Fehr. This 45-year-old man had an 18-month history of a progressive alteration in vision. He was unable to see objects in the right or left periphery of vision. He was concerned that in the process of driving he might hit pedestrians stepping off the sidewalks in the periphery of vision. He had also experienced over 6-8 months, progressive headaches, loss of energy and libido.

Neurological examination: Normal except for a bitemporal hemianopia.

Clinical diagnosis: Pituitary adenoma compressing the optic chiasm.

Laboratory data:

1. *Endocrine studies:* all were normal including prolactin, am cortisol, and thyroid functions.

2. *MRI:* A large macroadenoma measuring 3 cm in diameter extended outside of the sella turcica to compress the optic chiasm (fig. 23-11).

Subsequent course: Dr. Gerald McGuillicuddy performed a gross total trans sphenoidal resection of the tumor, with a significant improvement in vision. Three years later, the patient again had visual symptoms and eye pain. MRI scans indicated regrowth of tumor with possible impression on the right optic nerve. He was treated with radiotherapy.

Comment: Note that males are more likely to present with large pituitary adenoma compressing the optic chiasm. Women are more likely to present with microadenomas or small macroadenomas since they are more likely to be seen at an earlier stage due to an initial complaint of amenorrhea. Thus complaints of decreased libido in men are likely to be mentioned only in retrospect and not as an early presenting complaint.

The following case illustrates the effects of a space-occupying lesion in the occipital lobe. One should compare these findings to those reported earlier in Case 23-1, in which there was a lesion in the visual system anterior to the optic chiasm.

Case 23-3: This 47-year-old white, right-handed, real estate salesman was referred for evaluation of headache and visual disturbance. One month before admission the patient had a cough with some blood present in the sputum (hemoptysis). Five days before admission the patient developed a generalized headache, which was

precipitated by coughing or straining and which awakened him or prevented him from sleeping.

Two days before admission, the patient noted blurring in the left inferior quadrant of his field of vision.

The day before admission, he noted complete loss of vision in this quadrant. On the day of admission, the headache increased, and the patient was unable to see anything in the left visual field.

He had experienced no weakness, no disturbance of memory, and no language disturbance.

Past history was significant. The patient had multiple pulmonary infections, treated with antibiotics.

Neurologic examination:

1. Mental status: Intact

2. *Cranial nerves* were intact, except that blurring of disc margins was present bilaterally, with venous engorgement, indicating early papilledema.

A left non congruous homonymous hemianopia was present (Fig. 23-14A).

3. Motor system: Intact

4. Reflexes: *Deep tendon reflexes were slightly more active on the left. The plantar response on the left was extensor that on the right was flexor*

Laboratory data:

1. *Electroencephalogram* was abnormal because of frequent focal 3 to 4 cps, slow waves in the right occipital area and to a lesser degree, in the right posterior parietal area, consistent with focal damage in the right occipital area.

2. *Cerebrospinal fluid* pressure was elevated to 210 mm H₂O. The number of white blood cells was increased to 97 lymphocytes (upper normal limit is 5 to 7 lymphocytes). Protein was increased to 75 mg/dl (upper normal limit is 45 mg/dl). Glucose was 75 mg/dl (normal when compared to blood sugar of 95 mg/dl).

3. *Imaging* (radioactive brain scan Hg 197) demonstrated an enhanced region in the posterior and medial aspect of the right hemisphere (occipital and adjacent parietal lobes).

Subsequent course: The patient was treated with antibiotics (cephalothin sodium, penicillin, and streptomycin). Visual fields, EEG, and spinal fluid findings improved. Within 3 weeks the field defect had resolved to a non congruous left inferior quadrantanopia (Fig. 23-14B).

Ten days later the patient was readmitted to the hospital with a three-day history of right eye pain, sweats, and chills. Neurologic examination now revealed a recurrence of blurred optic-disc margins, a left homonymous hemianopia and a slight increase in deep tendon reflexes on the left. Imaging studies now revealed a large space-occupying lesion in the right parietal/occipital region, displacing the right lateral ventricle forward and downward.

After 10 days treatment with antibiotics (penicillin and streptomycin), a craniotomy was performed by Dr. Bertram Selverstone. A mass could be palpated medially in the right occipital and adjacent posterior parietal area. The abscess and a large surrounding area of hard granulomatous cortex and white matter were removed. (The etiologic organism was subsequently found to be a *microaerophilic streptococcus*.)

Postoperatively, the patient continued on treatment with penicillin. Follow-up examination 6 months after surgery was normal, except for the left homonymous hemianopia (Fig. 23-14C).

Comment: The rapid evolution of neurologic signs and symptoms in this case; the early development of papilledema, and the progressive changes in the electroencephalogram and brain scan; is consistent with the diagnosis of brain abscess. The primary infection in this case was probably in the lung.

The initial visual symptoms of inferior field involvement (quadrantanopia) suggested that the abscess, in its early stages, involved predominantly the superior portion of the optic radiation in the posterior parietal/occipital area or the superior bank of the calcarine fissure. With progression of the lesion, the entire optic radiation or the entire calcarine cortex was involved. The lesion found at surgery had destroyed or damaged both these areas.

The treatment of a brain abscess requires appropriate pre- and postoperative use of antibiotics. Many of these patients develop focal seizures at some time after successful surgical treatment of the abscess. Although prophylactic anticonvulsant medication, such as diphenylhydantoin (Dilantin), has been routinely administered, the value of such treatment remains unclear.

Note an important negative finding in this case: at no time did the patient experience any language disturbance. Reading and writing remained intact, as did the capacity for to construct drawings. This case involving the right occipital lobe should be compared with Case History 21-2, in which a focal lesion of the left occipital lobe was present.

The following is another example of the effects of a lesion in the occipital lobe with very different consequences than those seen in the previous case. The lesion clearly involved the cerebral cortex producing focal seizure activity.

Case 23-4. (Fig 23-15): This 18-year-old left-handed single white female restaurant employee was referred for reevaluation of a seizure disorder. While living in the south western United States, the patient had the onset of her seizures at age 14 when she had a sequence of five seizures in less than 12 hours. Each began with flashing lights, “like Christmas tree lights,” all over her visual field, plus the sensation that peoples’ faces were moving. She then would have an apparent grand mal seizure.

She was hospitalized. The neurological examination was reported as normal. An electroencephalogram report noted occasional focal sharp and slow waves in the left hemisphere. The CT scan was interpreted as essentially within normal limits. In retrospect, there was a question of some mottled hypodensity in the left occipital area, not clearly distinguished from artifact. The patient was treated with carbamazepine (Tegretol), 400 mg in the morning, and 230 mg at hour of sleep. In the interim, she apparently had done quite well with no additional grand mal seizures. She had rare episodes of “fear attacks,” which would last 23 to 25 minutes. The last attack had occurred 2 years ago, but as recently as two months ago, she had had one episode of flashing lights. A recent EEG was normal.

Past history was negative, except her birth weight was ten pounds, three ounces, and there was a problem of breathing at birth. She had always done poorly in school. Her family history did not suggest possible causes for a seizure disorder.

Neurologic examination: Normal.

Clinical diagnosis: Seizures of focal origin occipital cortex, (flashing lights and movement of the lights) probably left hemisphere based on the reports received of the EEG. There was subsequent spread of discharge into the temporal lobe based on the report of “fear attacks”

Subsequent course

The patient did well for 3 years then had a recurrence of a generalized convulsive seizure possibly related to omission of medication. Six weeks later, she reported two additional episodes characterized by flashing lights, then movement of the lights away from a center circle, then dizziness, then a

sensation of unreality. She also had other episodes of feeling unreal accompanied by fear. There were no olfactory hallucinations and no other visual or auditory hallucinations. The neurologic examination now demonstrated a minor right central facial weakness not present previously.

Laboratory data:

1. *EEG*: remained normal.
2. *MRI scan*: now revealed a small tumor at the left occipital pole with surrounding edema (Fig. 23-15). On CT scan, this tumor appeared partially calcified but did show enhancement. Angiograms suggested tumor vascularity of a type seen with meningiomas.

Subsequent course: Dr. Bernard Stone removed a discrete encapsulated tumor that appeared to be a meningioma. Subsequent microscopic examination, however, indicated a rare type of indolent follicular adenocarcinoma of the thyroid, which sometimes spreads as a single lesion to brain and remains quiescent for many years. In the postoperative period, a non-congruous right-inferior-field defect was present (partial quadrantanopia). The blood level of thyroid-stimulating hormone (TSH) was elevated. A thyroid nodule was found. A thyroidectomy was performed, and thyroid replacement medication was prescribed. No additional seizures were observed over the next 18 months. A metastatic lesion in the lumbar vertebral body subsequently appeared.

Comment: This patient presented many of the features of focal seizures arising in the occipital cortex: flashing lights, movement of objects and secondary generalization. Some of the seizure phenomenology such as “fear attacks,” dizziness, and “feeling unreal” suggested that spread into the temporal lobe was sometimes occurring. The student should now compare and contrast the cases presented in the previous chapter on the limbic system to this case to be able to note the differences seen after lesions in these adjoining cortical regions.

CHAPTER 24: SPEECH, LANGUAGE FUNCTION, APHASIAS, AGNOSIAS, APRAXIA

The following case, 24-1 presents an example of a selective non fluent aphasia of aphasia. An embolus to the superior division of the left middle cerebral artery produced marked weakness of the face tongue and distal right upper extremity and a severe selective nonfluent aphasia. The

hand weakness rapidly disappeared, the right central facial weakness, an apraxia of tongue movements and some expressive difficulties persisted.

Case 24-1: This 55-year-old, right-handed white housewife while working in her garden at 10:00 a.m. on 04-15-69, the day of admission suddenly developed a weakness of her right side and was unable to speak. Apparently, the right-sided weakness affected predominantly the face and arm since the patient was able to walk. The past history was significant. In 1960, nine years previously, the patient had been admitted to the hospital with a three-year history of progressive congestive heart failure secondary to rheumatic heart disease (mitral stenosis with atrial fibrillation). An open cardiectomy was performed with a mitral valvuloplasty (the valve opening was enlarged). A thrombus found in the left atrial appendage was also removed. Postoperatively, the patient was given an anticoagulant, bishydroxycoumarin (Dicumarol). Although atrial fibrillation continued, she did well until the day of admission. Prothrombin time at the time of admission was close to normal; that is, the patient was not in a therapeutic range for anticoagulation.

General physical examination: Blood pressure was moderately elevated to 170/80. Pulse was 110 and irregular (atrial fibrillation). Examination of the heart revealed the findings of mitral stenosis: a loud first sound, a diastolic rumble and an opening snap at the apex as well as the atrial fibrillation.

Neurological examination:

1. Mental status and language function:
 - a. The patient was alert.
 - b. She had no spontaneous speech and could not use speech to answer questions and could not even use yes or no to provide answers. She could not repeat words.
 - c. The patient was, however, able to indicate answers to questions by nodding (yes) or shaking her head (no), if questions were posed in a multiple choice situation. In this manner it was possible to determine that she was grossly oriented for time, place and person.
 - d. The patient was able to carry out spoken commands and simple written commands, such as, "hold up your hand, close your eyes." However, she had significant difficulty in performing voluntary tongue movements (such as "wiggle your tongue"; "stick out your tongue") on command.
2. Cranial nerves:
 - a. The patient tended to neglect stimuli in the right visual field.
 - b. She was unable to look to the right on command although the head and eyes were not grossly deviated to the left at rest.
 - c. A marked right supranuclear (central) type facial weakness was present.
 - d. The patient had difficulty in tongue protrusion. When the tongue was protruded it deviated to the right. The patient was unable to wiggle the tongue.
3. *Motor system:* Strength: there was a marked weakness without spasticity in the right upper extremity, most prominent distally. Some shoulder movements were possible; no hand or finger movements could be made. There was a minor degree of weakness involving the right lower extremity (75 percent of normal).
4. Reflexes:
 - a. Deep tendon stretch reflexes were increased on the right in the arm and leg.
 - b. Plantar responses were both extensors; more prominent on the right.
 - c. The abdominal reflex was absent on the right; present on the left.
5. Sensory:
 - a. Pain, touch and vibration were intact.
 - b. It was difficult to test other modalities but tactile localization appeared to be intact.

Clinical diagnosis: Embolus from heart to left middle cerebral artery

Laboratory data:

1. *Skull X-rays* were normal.
2. *EEG* was normal (48 hours after admission).
3. Cerebrospinal fluid was normal.
4. *Electrocardiogram* revealed atrial fibrillation

Hospital course: Within 24 hours a significant return of strength in the right hand had occurred; independent finger movements could be made. Within 48 hours after admission the patient was able to

repeat single words but still had almost no spontaneous speech. She appeared aware of her speech disability and would manifest some frustration. She was able to carry out two- or three-stage commands although tongue movements and perseveration remained a problem. Within 6 days of admission the patient used words, phrases and occasional short sentences spontaneously. She was better able to repeat short sentences. At this time strength in the right arm had returned to normal, but a right central facial weakness was still present. More detailed language evaluation two weeks after admission indicated the persistence of expressive disabilities consisting of word-finding and apraxic components. The apraxic components were evident on tongue placement and alternating tongue movements. Although complete sentences were used, sentence formulation in spontaneous speech was slow and labored with word finding difficulties. Repetition was better performed. In reading sentences aloud, substitutions or word omissions were made. The patient did well in naming common pictures and in matching printed words to spoken words or printed words to pictures. She could write from dictation and would often respond preferentially in writing when difficulty in speaking was encountered. No left-right confusion was present. Minor difficulties with simple arithmetic were reported. A right central facial weakness was still present.

Comment: There would appear little doubt that this patient had the sudden passage of an embolus (presumably from the left atrial appendage) into the left middle cerebral artery. In view of the selective face and arm weakness with a predominant expressive aphasia, the involved vessels must have been cortical branches such as the prerolandic and rolandic originating from the superior division of the middle cerebral artery. From the onset, it was clear that although some receptive components might be present, these were minor. The major problem was a severe nonfluent aphasia. As the hand weakness disappeared, the only other residual neurological findings were those of a right central facial weakness and an apraxia of tongue movements. Such findings would, of course, be consistent with a relatively selective involvement of Broca's area in the inferior frontal gyrus.

Why did such a rapid improvement occur in motor function and of the visual field? Most likely, the embolus fragmented and passed into the cortical branches supplying Broca's area.

With the passage of time, this type of patient would continue to show some degree of improvement (Mohr, 1973). Improvement could continue to occur over a two-year period. Although lesions of Broca's area may produce the acute onset of a nonfluent aphasia, rapid amelioration of the deficit occurs even when the acute lesion involves underlying white matter, as well as the superficial cortex.

In the following case 24-2, a more persistent anterior aphasia is demonstrated.

Case 24-2: On May 30, 1985, at midday, this 37-year-old right-handed woman with a past history of rheumatic fever, rheumatic heart disease and "an irregular pulse"(atrial fibrillation) had the sudden onset of loss of speech, central weakness of right face, an inability to protrude the tongue and a right hemiparesis. Although hemiparesis, face and tongue problems disappeared within a week, recovery of speech was slower and limited. At one week, she could produce some two syllable words.

Neurological examination at 17 months revealed the following residual findings:

1. *Language function:* Spontaneous speech was slow and relatively scanty. She could name objects slowly without difficulty, could do some simple repetitions and could write from dictation. She could carry out two and three stage commands. She could read slowly aloud but had little comprehension of what she read.
2. *Reflexes:* A residual right Babinski sign and right-sided hyperreflexia were present.

Clinical diagnosis: Anterior aphasia: embolic infarct of superior division of middle cerebral artery.

Laboratory data:

Although initial CT scans in May 1985 had been reported as negative; the MRIs in November 1986 and June 1990 demonstrated the infarct which included Broca's area, as well as adjacent frontal areas with predominant involvement of frontal operculum (inferior frontal gyrus) and adjacent middle frontal gyrus. In addition, a minor independent infarct was present in right occipital area (presumably embolic to the calcarine artery).

Subsequent course: Similar findings were present at 5 years, June 1990).

A brain section from a patient (Case 24-3) with a persistent nonfluent aphasia (is presented in Figure 24-4.

Case 24-3: This 69-year-old, right-handed male expired in 1965. In 1961 and 1963, The patient, had experienced transient episodes of right hemiparesis and aphasia, both followed by complete recovery. In 1964, a more persistent right hemiparesis and aphasia had developed.

General physical examination: No left carotid pulsation was present.

Neurologic examination(1965):

1. **Language functions:** Speech was nonfluent with only a small verbal output. A significant nominal aphasia with paraphasias was present. Reading was limited. Comprehension of spoken language was good. A marked apraxia was present for movements of tongue, lips and hands.
2. **Motor system:** Right hemiparesis with associated reflex findings.
Post mortem findings: Left carotid occlusion with old infarction, predominantly of left middle cerebral territory with lesser involvement of anterior cerebral territory. Note that minor cortical infarcts are also present involving cortex of right hemisphere.
(Courtesy of Dr. John Hills,; and Dr. Jose Segarra.)

Case 24-4 provides an example of a patient with a Wernicke's type aphasia

Case 24-4: This 40-year-old, right-handed white male had experienced a series of myocardial infarctions beginning 10 months prior to consultation. Angiographic studies indicated occlusion of the right coronary artery and the left anterior descending coronary artery with stenosis of the circumflex artery. The patient was subsequently admitted and a coronary artery bypass procedure was performed using extracorporeal circulation. Although the patient was stated to have tolerated the procedure well, the anesthetist noted that the patient was nonreactive 15minutes after the last administration of halothane anesthesia. When the patient did wake up, he was quite agitated requiring the use of agents to reduce agitation. Throughout the postoperative period, the patient continued in a disoriented and combative manner. Because of the patient's acutely psychotic state, transfer to the psychiatry service was actively planned. Because there were certain organic features to the patient's illness, a neurological consultation was obtained. The neurology resident in reviewing the progress notes discovered a notation that shortly after surgery the patient had transient difficulty in using his right arm.

Neurological examination:

1. **Mental status:**
 - a. The patient was an alert but agitated white male. Additional inquiries indicated that his agitation related to his inability to write a letter to his mother.
 - b. The patient's speech was fluent and usually grammatical. He made use of many paraphasias and neologisms (nonsense words). He often appeared unaware of his errors.
 - c. The patient was unable to name single objects such as pencil, cup, and spoon though he could recognize and demonstrate their use.
 - d. The patient could read occasional individual words; for example, cat, house. He could not comprehend or carry out, either spoken or written commands.
 - e. His attempts at spontaneous writing produced only a few letters. He was unable to write words or phrases from dictation. He did significantly better when asked to copy a printed sentence or phrase.
- f. Repetition of spoken phrases or sentences was poor.
- g. Calculations of even a simple nature were poorly performed.
2. **Cranial nerves:** II-XII was intact.
3. **Motor system:** No actual weakness was present. Gait was intact.
4. **Reflexes:**
 - a. A minor increase in deep tendon stretch reflexes was present on the right side.
 - b. The plantar response on the right was equivocal. The left was flexor.
5. **Sensation:** Pain, touch and vibration were intact.

Clinical diagnosis: Wernicke's type of fluent aphasia probably secondary to an embolus to the inferior division of the middle cerebral artery.

Comment: This patient who was seen before the era of modern neuroimaging provides an example of the clinical picture described by Wernicke. The use of the heart pump for open-heart surgery was associated with a high incidence of cerebral

emboli. The incidence of this complication has decreased as technical advances have been made and as “time on the pump” has decreased. As we have stressed, for solving neurological problems, the details of the history are important if the appropriate diagnosis is to be made. In the patient who is unable to provide a history, the careful review of progress notes and of nurses notes will often provide the clue that allows diagnosis.

The following case history 24-5 demonstrates such a sequence of involvement in a tumor infiltrating the posterior temporal inferior parietal area starting with a conduction aphasia.

Case 24-5: This 42-year-old right handed truck driver noted fatigue and irritability 6-8 weeks prior to admission. Three to four weeks prior to admission, he noted he was using words which he did not mean to use and certain words would not come to him. He had two generalized convulsive seizures; each proceeded by a ringing sensation in the ears, during the week prior to admission.

Neurological examination:

1. Mental status and language function

- a. The patient was alert and oriented to time, place and person.
 - b. He was cooperative and able to carry out the four-step command: “stick out your tongue, close your eyes, hold up your hand and touch the thumb to your ear”. There was however evidence of a significant left-right confusion when laterality was introduced e.g. “left hand to right ear”.
 - c. The ability to do even simple calculations was markedly impaired with or without paper e.g. $100-9=99$.
 - d. Memory was impaired; with immediate recall object recall limited to 2/5 objects and delayed recall in 5 minutes limited to 0/5. Digit span was limited to 2 forward and 0 in reverse. (normal would be 7 forward and 6 in reverse).
 - e. There was little evidence of an expressive aphasia. Flow of speech was slow with only minor mispronunciations. Reading was slow but with few errors. The patient’s did have minor difficulty in naming objects-a mild nominal aphasia. The patient’s greatest difficulty was in repetition of simple test phrases. There were moderate defects in drawings of a house and a clock but few errors in copying simple figures. There was a significant dysgraphia with marked difficulty in writing a simple sentence spontaneously or in writing from dictation. On the other hand, the patient was much better able to copy a simple sentence. Significant errors were made in spelling.
2. **Cranial nerves:** All were intact except for a mild right central facial weakness.
 3. **Motor system:** Strength, gait and cerebellar functions were all intact.
 4. **Sensory system:** Pain, touch, vibration, stereognosis, simultaneous stimulation, graphesthesia, and position sense were all intact, but point localization was impaired on the right side.

Clinical Diagnosis: Fluent posterior aphasia, disconnection syndrome plus elements of Gerstmann’s syndrome (left right confusion, dyscalculia, dysgraphia) plus seizures of focal origin (Heschl’s gyrus posterior temporal lobe) with secondary generalization. All suggested a lesion in the left posterior temporal-posterior parietal area.

Etiology was uncertain but tumor (glioma) or embolus to inferior division of left middle cerebral artery possible.

Laboratory data:

1. Skull and chest x-rays were normal.
2. **EEG:** Focal 4-5 Hz slow wave activity was present in the left parietal and posterior temporal areas.
3. **Brain scan (radioactive Hg 197):** Increased up take of isotope in the left posterior temporal –parietal area measuring 4x5 cm.
4. **Left carotid arteriogram:** Vascular mass in the region of the angular gyrus with tumor stain in the area.

Subsequent course: Papilledema soon developed and Dr. Robert Yuan performed a craniotomy. Although the cortex appeared externally normal, a firm mass could be palpated

slightly above and posterior to the angular gyrus. At 2 cm below the surface, firm yellow tumor tissue was encountered. All visible tumor and adjacent cortex of the angular and supramarginal gyri were removed and a partial left temporal lobectomy was performed. Histologic examination indicated a highly malignant glial tumor with active mitosis and necrosis (a glioblastoma multiforme). Post operatively, the patient had a marked expressive and receptive aphasia. By 30 days after surgery, the patient had a significant improvement in fluency, he continued to have a severe posterior type of aphasia. He was unable to carry out simple commands. His speech was incoherent, with nonsense words and neologisms. He appeared unaware of his errors and did not appear frustrated by his failure to follow commands. In addition to this Wernicke's type aphasia, the patient was unable to repeat words of two syllables. He could do no calculations, had severe difficulties in copying drawings and was unable to even write his name. The patient received radiotherapy but his condition continued to worsen with the development of a progressive expressive and receptive aphasia and hemiparesis all suggesting the spread of a rapidly growing glioblastoma. Coma, pupillary changes and respiratory changes then intervened suggesting the effects of herniation of the residual temporal lobe. Death occurred 7 months after onset of symptoms, and 5 months following surgery.

Comment: The early language and mental status disturbances in this patient were most severe in those tasks requiring repetition. Thus the patient could repeat no more than two digits, was unable to repeat any of the test phrases and was unable to write from dictation at a time when he could copy a sentence. Any expressive aphasia was minor, and he was fluent. He had no evidence of Wernicke type aphasia, since he could carry out a four-stage command without difficulty. Reading was relatively well preserved compared to writing, calculations and drawing construction. All of these findings suggest (1) the speech reception Wernicke's area was disconnected from the motor association areas for speech and writing Broca's areas 44,45 and the related areas of the premotor cortex and (2) the inferior parietal areas associated with writing, calculations, drawing, and the ability to distinguish left and right were damaged. The lesion found at surgery was deep to the angular and supramarginal gyri, the location of the arcuate sulcus. The seizures that finally brought the patient to neurological attention were originating in Heschl's gyrus of the temporal lobe, which would be adjacent to the area of the tumor.

The clinical state at 30 days following surgery reflected the additional effects of ablation of the Wernicke's area as well as the accentuation of the preoperative state. There had been the transient appearance of an expressive aphasia probably reflecting minor effects of the procedure on Broca's area.

The neurosurgical approach to the management of a glioblastoma particularly those involving the speech areas of the dominant hemisphere have changed in 35 years since this patient was seen. A limited stereotaxic biopsy under CT scan guidance would be undertaken and the patient would then be treated with dexamethasone and radiotherapy. The end results would have been similar and actually may even have occurred earlier. The postoperative quality of language function may have been transiently better. Unfortunately this patient had a very malignant and aggressive tumor. The median survival of glioblastomas with surgery alone is 26 weeks, with the addition of radiotherapy; 52-60 weeks. Median means that 50% of patients are going to survive less than these median figures.

The following case (24-6) provides a case of posterior aphasia with the lesion documented with CT scan.

Case 24-6: This 57-year-old female, with a long history of hypertension in the summer of 1985, had a brief episode of difficulty in word finding and a more prolonged episode in December 1985 with confusion, "visual problems", "inappropriate speech and difficulty finding the appropriate words". Following an additional episode in March 1986, she had persistent problems in reading and apraxia of the right hand.

Neurological examination (May 1986): The following abnormalities were present:

1. *Language function:* Spontaneous speech was usually quite fluent. She described the room, the environment and her friend. In contrast, capacity for repetition was very poor both as regards spoken and written speech. Spontaneous writing was very poor except for name and address

Reading to herself aloud was poor with little comprehension. She was able, however, to follow single one stage spoken or written commands but unable to do a sequence of commands. Naming of objects was well performed.

2. *Cranial nerves*: Extinction occurred in the right visual field for bilateral simultaneous stimuli.
3. *Motor system*: No hemiparesis was present.
4. *Reflexes*: Right-sided hyperreflexia and a right Babinski sign were present.

Clinical diagnosis: Posterior aphasia, infarction left posterior temporal and parietal areas, probably due to embolic occlusion of inferior division of the left middle cerebral artery.

Laboratory data:

1. *CT scan*: Infarct left posterior temporal and parietal areas (Fig. 24-6).
2. *Angiograms*: Occlusion of the left internal carotid artery. All anterior and middle cerebral artery branches filled from the right carotid. An artery to artery embolus was presumed.

The following case 24-7 would suggest this type of unilateral lesion producing a transient and partial but selective type of dyslexia.

Case 24-7: Seven days prior to admission, following a period of athletic activity, this 15-year-old, right-handed white male high school student had the onset of a 48-hour period of sharp pain in the left jaw and the supraorbital area. The next day the patient began to complain of blurring of vision and the following day had the onset of vomiting. Four days prior to admission, the patient noted that he was unable to read and to translate his Latin lessons. No definite aphasia was apparent. Two days prior to admission, the patient had the sudden onset of severe left facial pain, accompanied by tingling paresthesias of the right leg. The patient became stuporous and then unresponsive for approximately 90 minutes. An examination of spinal fluid at that time revealed pressure elevated to 290 mm of csf with 250 fresh blood cells.

Neurological examination:

1. *Mental status*: All aspects, including language function were intact.
2. *Cranial nerves*:
 - a. Examination of the fundus showed several small flame shaped hemorrhages. Visual fields were intact.
 - b. A slight, right, supranuclear-type (central) facial weakness was present.
3. *Motor system*: Intact
4. *Reflexes*: Deep tendon reflexes and superficial reflexes were symmetrical and physiologic.
5. *Sensory system*: Primary and cortical modalities were intact.
6. *Neck*: A slight degree of resistance was present on flexion of the neck (nuchal rigidity) consistent with the presence of blood in the subarachnoid space.

Clinical diagnosis: Subarachnoid hemorrhage of uncertain etiology. In view of age and the transient dyslexia, and the transient paresthesias of the right leg, an arteriovenous malformation in the left parasagittal parietal-occipital area might be suspected.

Laboratory data:

Arteriograms: An arteriovenous malformation was present in the left occipital region. The main arterial supply was the posterior temporal branch of the left posterior cerebral artery. The malformation drained into the lateral sinus. The posterior portion of the anterior cerebral artery was shifted across the midline, indicating a hematoma as well as the malformation.

Subsequent course: On that evening after his admission, the patient had the sudden onset of a bifrontal headache. For a 2- to 3-minute period, the patient was unconscious with deviation (repetitive driving) of both eyes to the right, and with sweating and slowing of the pulse rate. Over the next two days an increase in blurring of the optic disc margins was noted (early papilledema). Four days after admission, the patient suddenly complained of being unable to see from his right eye. He became restless and agitated. Additional headache and neck pain with numbness of right arm and leg were reported. Examination now disclosed a dense right visual field defect (homonymous hemianopsia). The deep tendon reflexes were now slightly more active on the right. Funduscopy suggested that

recent additional subarachnoid bleeding had occurred since new retinal hemorrhages were present. The next day (five days after admission), the patient was noted to have a significant reading disability (dyslexia), although other language functions were intact.

Because of the progressive evolution of neurological findings due to an expanding intracerebral hematoma, Doctor Robert Yuan performed a craniotomy. Blood was present in the subarachnoid space. The left lateral occipital cortical surface had numerous areas of bluish discoloration indicating an intracerebral clot. The main arterial vessel was a lateral and inferior branch of the posterior cerebral artery, bearing no relationship to the calcarine region. The draining vein was located in the occipital-temporal area, close to the tentorium. At a depth of 1 cm, a hematoma of 50 cc of clot was found. The clot extended down to the occipital horn of the lateral ventricle but did not enter the ventricle. The malformation, hematoma and related cerebral tissue of the lateral occipital area were removed. The calcarine area remained intact at the end of the procedure. Over a period of several days, the visual field deficits disappeared.

Detailed language and psychological testing approximately two weeks after surgery indicated that language function was intact except for reading. Oral reading was very slow (4 times slower than normal for a test paragraph), halting and stumbling. Comprehension of the material read was good. Minor errors were made in the visual recognition of letters. This was reflected in occasional errors in spelling. Visual recognition and naming of objects was intact. Auditory and tactile recognition of sounds, words, letters, sentences, questions, commands and so forth was intact. Calculations were intact. No right-left confusion or finger agnosia was present. Writing and drawing were intact but slow. Repetition of speech and spontaneous speech were intact.

Follow-up evaluation at 20 and 30 months indicated that, although the patient was doing well in school, receiving A's and B's with excellent grades in mathematics, he still was described as slow in reading compared to his level prior to illness. No actual errors were made in reading when this was tested.

Comment: The arteriovenous malformation in this case had involved and eventually required surgical removal of the lateral occipital area of the dominant hemisphere. The hematoma in the occipital lobe extending in from the lateral surface to the occipital horn was so located as to compress the optic radiation passing to the calcarine cortex or perhaps even to indirectly compress the calcarine cortex. Such a hematoma would also interfere with association fibers passing from left occipital areas to temporal parietal areas and with callosal radiation fibers passing from the occipital region (area 18) of the right hemisphere to the occipital and parietal areas of the dominant hemisphere. Following surgery, the patient had a relatively good recovery with the minor difficulties in reading; (a selective dyslexia) as perhaps the only indication of any damage to these fiber systems.

The complaint of the patient at the time that the right homonymous hemianopsia appeared was of blindness in the right eye. It is not uncommon for patients to localize field defects in this manner to the eye of the same side. The same may sometimes be true of patients with discharging lesions in the occipital area; the flashing lights and lines may be localized to the contralateral eye rather than to the contralateral visual field.

The episode on the night of admission is of interest because it suggests a focal adverse seizure, in this case presumably originating from areas 18 and 19 of the left hemisphere.

Geschwind (1965) has reviewed many of the previously reported cases of selective dyslexia. It is uncertain whether the information from area 18 of the non-dominant hemisphere passes to the non-dominant angular gyrus and then crosses to the dominant temporal parietal areas or whether these fibers pass instead directly to area 18 of the dominant hemisphere with information then conveyed to the dominant temporal parietal areas. He finally concludes that both pathways are probably operative. The relatively minor nature of the final residual deficit in the present case would be consistent with such multiple pathways. In addition, non-fatal hemorrhages always produce less damage than infarcts of comparable size. Finally, Coslett (2000) has reviewed various recovered pure cases of dyslexia where the right hemisphere may have played a role in reading. Such patients do better with concrete nouns than abstract nouns, verbs and functors (pronouns, prepositions, conjunctions and interrogatives). It should be noted that a relatively selective dyslexia in the absence of a severe general visual agnosia might occur. Geschwind has suggested that whether a general visual agnosia or dyslexia occurs may depend on the degree of disconnection of the dominant speech areas from the parietal and occipital areas of the non-dominant hemisphere. In the patient who already has left occipital cortex damage, dyslexia may require only damage to the splenium of the corpus callosum, whereas visual agnosia may require more extensive damage to the posterior body of the corpus callosum as well. As noted bilateral

visual association lesions (areas 18 and 19) would also produce a visual agnosia. (See also Coslett and Saffran 1989 and Friedman and Albert 1985).

In addition there are patients who have acquired dyslexia which is unrelated to the processing of the visual information input. These patients have a central (rather than the peripheral dyslexia of the pure alexia syndrome discussed above). The central dyslexic patient has an impairment of the “deeper” or “higher” reading functions by which visual word forms mediate access to meaning or speech production mechanisms. This problem is reviewed in detail by Coslett (2000).

Feinberg and Farah (2000) review the general topic of agnosias.

CHAPTER 26: VASCULAR SYNDROMES OF THE CEREBRAL HEMISPHERES

The following case history presents a young adult with severe carotid stenosis and infarction of the territories of both the anterior and middle cerebral arteries.

Case 26-1: This 23 year old right handed female on birth control pills, smoking one pack of cigarettes per day, on June 15, 1985 shortly after intranasal “snorting” of cocaine complained of gradually increasing right sided headache and then fell to the floor with a flaccid left hemiplegia with the head and eyes deviated to the right **Neurological examination:**

1. *Mental status:* The patient denied any illness and could not explain why she was in the hospital.
2. *Cranial nerves:* There was a left homonymous hemianopsia, deviation of head and eyes to the left and a left central facial weakness.
3. *Motor system:* A flaccid left hemiparesis was present.
4. *Reflexes:* deep tendon reflexes were initially depressed on the left side. Plantar responses were extensor bilaterally.
5. *Sensory system* a severe left hemisensory deficit, with a neglect of the left side of space and body was present.

Clinical diagnosis: Total right middle cerebral artery territory infarct.

Laboratory data:

1. *Initial CT Scan* demonstrated hypodensity (infarction in right frontal and parietal areas).
2. *Right carotid angiogram* demonstrated severe stenosis of the supraclinoid segment of the right internal carotid artery with severe stenosis of the M-1 segment of the right middle cerebral artery and multiple areas of narrowing of the remainder of the right MCA. *Left carotid angiogram* indicated only limited cross filling of the distal right middle and anterior cerebral arteries.

Subsequent course: On 6-21-85, 6 days after admission the previously alert patient suddenly developed a decreased level of consciousness and a fixed, dilated right pupil suggesting that tentorial herniation had been produced by severe edema or hemorrhagic transformation of the infarct. CT Scan now demonstrated massive infarction and edema-right anterior and middle cerebral artery territories plus-transtentorial and sub falx herniation (Fig.26-6). With emergency management of the increased intracranial pressure-(monitor and osmotic agents) the patient became more alert and was transferred to a rehabilitation facility.

Comment: This young woman had as a major risk factor, the intranasal snorting of cocaine. The vasospasm induced by this agent was sufficient to produce severe stenosis of the internal carotid and the initial segment of the middle cerebral artery. The multiple areas of narrowing seen in the branches of the MCA may well have represented emboli from these more proximal sources. Whether the severe stenosis of the M1 portion also involved an embolic event from the siphon remains unclear. It is clear that the severe stenosis of the carotid artery produced infarction of both the MCA and ACA territories. In this case there was insufficient cross flow from the left carotid supply to prevent infarction. As we will see in case 26-3 massive infarcts of the MCA territory plus or minus adjacent territories constitute a serious threat to life due to massive edema and or hemorrhagic infarction with the risk of herniation. The use of cocaine and of crack cocaine may be associated coronary or cerebral artery vasospasm. In addition to cerebral infarcts, cerebral hemorrhage may also occur, particularly with crack cocaine.

The following case history concerns a patient with severe stenosis at the carotid bifurcation producing both retinal and hemispheric TIA's.

Case 26-2: This 54-year-old, right-handed, white male had experienced intermittent episodes of blurring and blacking out of vision in the left eye for at least 7 years. Each episode would last 30 to 60 seconds and would occur twice per month. Ten days prior to admission, the patient had the onset of numbness of the right side of the face accompanied by minor weakness of the right face, arm, and leg. There was also a transient difficulty

in speech (possibly dysarthria, possibly difficulty in word finding). Symptoms cleared completely in 45 to 60 minutes with the exception of residual numbness of the right side of the face.

Family history: The patient's mother died of a "stroke" at age 66 years, and his father, of heart disease at age 57.

General physical examination:

- (1) Blood pressure was slightly increased to 160/100 in both arms. Pulse rate and rhythm were normal
- (2) Bruits (murmurs) were present over each carotid artery, but the heart was normal with no murmurs.
- (3) The retinal artery pulsation was easily obliterated by pressure on the globe of the left eye. No significant changes occurred on compression of the right globe.
- (4) Peripheral pulses were poor in the lower extremities.

Neurological examination: Mental status, language function, cranial nerves, motor system, reflexes, and sensory system were all normal except for a minor right central facial weakness.

Clinical diagnosis: Carotid stenosis with retinal and hemispheric TIA's.

Laboratory data:

1. Hemoglobin, serological tests for syphilis, skull and chest x-rays, electroencephalogram, and brain scan were all normal. Cholesterol was elevated to 284 mg%.

2. *Arteriography (aortic arch study)* demonstrated a complete occlusion at the origin of the left internal carotid artery. A right brachial arteriogram demonstrated filling of the left anterior and middle cerebral arteries by cross flow through the anterior communicating artery from the right side. Additional studies also demonstrated filling of the intracranial portion of the left internal carotid artery from the left posterior communicating artery.

Subsequent course: Ten days after that hospital admission, a left carotid endarterectomy was performed by Dr. Allan Callow with a restoration of blood flow following removal of the occlusive lesion (atherosclerosis with recent thrombosis) at the carotid bifurcation.

Comment: The location of disease in the left carotid artery was clearly indicated by the episodes of left eye visual disturbances followed by symptoms on the contralateral side of the body. The development of symptoms in the face, with disturbance of speech is consistent with total occlusion of the carotid artery, with greater involvement of the middle cerebral territory than of the anterior cerebral territory. The fact that this patient, with progressive stenosis of the carotid artery, had symptoms for many years only in the ophthalmic-retinal artery distribution, is explained by the excellent collateral flow into the anterior and middle cerebral arteries from the anterior communicating bypass. In addition collateral flow would enter the common carotid artery from the posterior communicating artery above the take off of the ophthalmic artery.

It should be apparent that the final complex of neurological symptoms and signs, occurring with occlusion of the carotid artery, will depend on the total pattern of cerebral blood flow in the individual patient. In many patients total occlusion of the carotid artery will produce an infarction of that portion of the cerebral hemisphere supplied by the carotid artery (primarily the middle cerebral territory). In others, a benign outcome is the result (Bornstein and Norris, 1989). With the development of imaging techniques such as CT and MRI scan - has come the recognition that small silent infarcts may occur in patients with non symptomatic stenosis of the carotid artery (Norris and Zhu, 1992).

In this case, the occurrence of symptoms in the right side of the face plus the difficulty in speech might raise the question of a possible embolus to a branch of the MCA from the thrombus at the bifurcation. A perfusion deficit would have produced problems primarily in the border zone (the area of the arm).

In this particular case, earlier evaluation of the patient might well have resulted in a demonstration of occlusive disease of the extracranial portion of the carotid artery

prior to total occlusion. For such patients surgical therapy is feasible. To restore blood flow 20 days after occlusion as in this case is unusual.

A question which remains unanswered in this case is whether this patient would have proceeded eventually to a completed lasting hemiparesis. Kase et al (1991) have summarized the various studies. The rate of completion of the stroke over a 40 month period varied from 2% (Marshall, 1964) to 51%.

The following case demonstrates a case in which the patient began with carotid TIA's progressed to a carotid border zone syndrome of infarction and then involved additionally all of the middle cerebral artery territory.

Case 26-3 (Pt. of Dr. Thomas Mullins): This 72-year old right-handed white male was admitted for evaluation of two episodes of right upper extremity weakness, each of two hours duration, beginning 2 days prior to admission. Following the first episode, the patient had persistent left-right disorientation, a deterioration in writing (dysgraphia), could not understand what he had read and had transient slurring of speech.

Neurological examination:

1. *Mental status and language function:* Intact for alertness and orientation. Language was fluent with intact repetition, and object naming; however, reading comprehension, writing, and left-right orientation were all impaired.
2. Cranial nerves: Intact.
3. Motor system, reflexes and sensory system were all entirely intact.
4. *Carotids:* A bruit was present on the left.

Clinical diagnosis: Carotid artery stenosis with TIA's reflecting decreased perfusion in the border zone followed by thrombosis and passage of emboli to the inferior division of the middle cerebral artery.

Laboratory Data:

1. CT scan and EKG were normal
2. An *arteriogram* performed on the day following admission demonstrated the following:
 - (a) The left internal carotid artery was completely occluded just above the bifurcation (Fig. 26-7A).
 - (b) The left external carotid artery did fill the left internal carotid artery at the siphon through anastomosis about the orbit (Fig. 26-7B). However, there was a cutoff just below the siphon suggesting that the thrombus (clot) at the bifurcation had extended to this level. Moreover, the left middle and anterior cerebral arteries failed to fill in this manner.
 - (c) The left posterior cerebral artery did originate from this segment of the otherwise occluded carotid siphon segment but with no retrograde filling into the basilar artery (Fig. 26-7B).
- 4) The right carotid artery filled not only the right middle cerebral and anterior cerebral artery but also was the source of the right posterior cerebral artery (Fig. 26-7C).
- 5) The right carotid system also supplied the left anterior cerebral artery and to a limited extent the left middle cerebral artery (Fig. 26-7D).

Subsequent course: On the day following admission, weakness in the right hand at wrist and finger extensors recurred. During the arteriogram, the patient was noted to have additional problems with speech. Weakness in the right upper extremity increased. Despite subsequent anticoagulation, additional progression occurred with total paralysis of the right upper extremity, aphasia and a right homonymous hemianopsia. A *repeat CT scan*, 72 hours after these events, demonstrated acute infarction with severe edema involving the entire cortical and deep territory of the middle cerebral artery and the cortical territory of the posterior cerebral artery but with relative sparing of the anterior cerebral artery territory and of the thalamic territory of the posterior cerebral artery (Fig. 26-8). Coma developed secondary to the herniation effects on the brainstem and the patient expired 8 days after admission.

Comment: This patient clearly had hemispheric carotid border zone TIA's followed by persistent symptoms that suggested involvement of the inferior division of the middle cerebral artery to the inferior parietal lobule. These latter persistent symptoms may well have been embolic from the thrombus at the level of the carotid bifurcation. There then was progression of the border zone findings

followed by involvement of the entire middle cerebral artery territory and of the cortical territory of the posterior cerebral artery. The end result was a massive cerebral infarct with considerable swelling. Such massive swelling with herniation of temporal lobe through tentorium and secondary brainstem compression is the major cause of acute death in patients dying after acute carotid artery or massive middle cerebral artery infarctions (31%). Other causes of death are pneumonia (29%), cardiac arrest (17%), pulmonary embolus (13%) (Bounds et al 1981).

Not all patients with acute carotid infarcts continue to progress. In the series of Jones and Milliken (1976), 39% of patients remained stable. Thirty-five percent had gradual improvement and 19% had a progressing deficit over 48 hours.

The following case history illustrates such an occlusion with massive infarction of the entire territory of the middle cerebral artery.

Case 26-4: This 61-year-old, right-handed black housewife one week prior to admission, suddenly fell to the floor while taking a bath and lost consciousness. She was picked up off the floor by her son who found that she was unable to move her left arm and leg. She was unable to walk and had regained no function in these extremities. Her speech had been thick, but no aphasia had been present. No headache had been noted.

Past history: Hypertension had been present for three years. Five days prior to admission, she had been switched to a new antihypertensive medication. There was no history of heart disease. Both parents had died of heart disease and hypertension.

General physical examination: Blood pressure was 150/100, pulse was regular at 84. Blood pressure was 150/100, the pulse was 84 and regular.

Neurological examination:

1. *Mental status:* The patient was obtunded and slow to respond. However, she was grossly oriented to time, place, and person.

2. *Cranial nerves:*

- a. The head and eyes were deviated to the right. The patient could not move the eyes to the left on command. However, on vestibular stimulation, the eyes could be moved to the left.
- b. The patient neglected stimuli in the left visual field. The pupils did respond to light.
- c. Papilledema was present bilaterally particularly in the right fundus where a recent hemorrhage was present.
- d. There was a decrease in pain sensation or a neglect of painful stimuli on the left side of the face.
- e. A marked left central facial weakness was present.

3. *Motor system:* A complete flaccid paralysis of the left arm and leg was present. The patient was unable to sit up without support.

4. *Reflexes:* Deep tendon reflexes were increased on the left compared to the right. The left plantar response was extensor.

5. *Sensory system:* All modalities of sensation were decreased on the left side of the body.

Clinical diagnosis: Acute occlusion of the stem of the middle cerebral artery, possibly embolic, although primary occlusions of intracranial arteries may occur in the non-Caucasian population. Hypertensive intracerebral hemorrhage was a less likely possibility.

Laboratory data:

1. *Chest and skull x-rays* were negative but the *electrocardiogram* showed left ventricular hypertrophy.
2. *Electroencephalogram* indicated focal damage throughout the right hemisphere—most prominent in the right frontal area, (focal 3 to 5 Hz slow waves). In addition there was a relative absence of electrical activity in the right temporal area (Fig. 2-23) consistent with a severe degree of destruction of this area.
3. Brain scan 3 days after admission showed a significant but diffuse uptake of isotope (Hg^{197}) in the right hemisphere. A repeat brain scan on 9 days after admission showed a more marked uptake measuring 11x6x6 cm., extending from the right frontal area to the posterior parietal area. Uptake extended from the surface to the deep midline (Fig. 26-14).
4. Cerebrospinal fluid contained no significant cells. Protein was moderately increased to 57 mg./100 ml. Pressure at the lumbar area was 150 mm. of csf.
6. Right brachial arteriogram revealed a complete occlusion of the right middle cerebral artery at its origin (Fig. 26-15).

Hospital course: The patient showed no significant improvement during a four week hospital course.

Comment: The patient had a sudden occlusion of the right middle cerebral artery with massive infarction of the entire area of the right hemisphere supplied by the middle cerebral artery. Such massive infarctions are often, as in this case, associated with a significant degree of cerebral edema with the development of papilledema. At times the degree of swelling of the cerebral hemisphere may be sufficient to displace the pineal or the anterior cerebral artery. It is also possible in this case that the infarct was secondarily hemorrhagic. In many cases of hemorrhagic infarction the spinal fluid does not contain red blood cells.

The equal involvement of arm, arm, and leg was consistent with the involvement of the penetrating branches of the middle cerebral artery with resultant infarction in the posterior limb of the internal capsule. The deviation of head and eyes to the right indicates destruction of area 8 of the right hemisphere or of the fibers descending from this area, through the corona radiata. Involvement of the cortex in addition to this the internal capsule is also indicated by the findings on the brain scan and electroencephalogram and by the neglect of visual and tactile stimuli on the left side. As regards the etiology, an embolus to the middle cerebral artery is the most likely etiology although in a non-Caucasian patient, primary occlusion could not be ruled out. Today this patient would probably have been treated with t-PA presuming that she had arrived at an emergency room capable of administration of this agent within 3 hours of onset of symptoms and did not have contraindications in terms of preexisting conditions or of CT scan findings (hemorrhage or massive infarction -refer to Brott & Boguslavsky, 2000) .

Prognosis for survival during the acute state of the first week depends on the degree of edema patients with massive middle cerebral artery territory infarcts due to MCA occlusion who already had early CT scan evidence of brain swelling within 24 hours of the ictus. Fifty five percent of these patients expired ,overwhelmingly of herniation effects. Patients older than 45 years had a poorer prognosis than younger patients. Infection of the lungs is a serious complication of large infarcts and a major cause of death during the second week. If the patient survives ,prognosis for recovery is related to the size of infarct. Less than 3 cm. infarcts may be associated with a good recovery ; greater than 3 cm. with severe disability (Olson ,1991). This patient had already survived for one week prior to reaching the neurologic center. Although she continued to survive, her prognosis for recovery remained poor.

The following case history illustrates many aspects of ischemia within the cortical distribution of the posterior cerebral artery. This patient demonstrates the general rule that posterior cerebral cortical infarcts are usually embolic.

Case 26-5: This 55 year old ambidextrous married white female research coordinator at approximately 11:30 AM on the day of admission suddenly developed blurring of vision possibly all over her field of vision, possibly in her left visual field, possibly in her left eye. A coworker checked her vision, and found that she had a left visual field defect. Shortly thereafter, she developed tingling paresthesias of the left face arm and leg.

Past history: Hypertension treated with hydrochlorothiazide and Lasix.

Physical examination: Blood pressure was elevated to 160/70. Weight was elevated to 264 pounds .A small ecchymosis was present under the toenail of the left second digit.

Neurological examination,(3hours after onset):

1.Mental status: Intact .

2.*Cranial nerves:* A non-congruous left homonymous hemianopsia was presented greater in the left temporal field than the right nasal field.

3.Motor system: Intact.

4.*Reflexes:* Deep tendon stretch reflexes were decreased in the lower extremities (patella,1+ and Achilles,0). Plantar responses were equivocal ,with the left probably extensor.

5.*Sensory system:* There was decreased pain and errors were made in graphesthesia over the left foot.

6.*Vascular:* There were no bruits over the carotids and subclavian areas and the blood pressures in the two arms were equal.

Clinical diagnosis: Posterior cerebral artery ischemia and possible infarct, probably embolic, involving the right calcarine cortex and thalamus or a lacunar event involving the right thalamus.

Laboratory data:

1. Duplex scans of the carotid and vertebral arteries and CT scan of the head on the day of the event were normal. RPR, ESR, TSH, proteins C, S, antithrombin 3 and all anticardiolipin antibodies were normal.
2. *MRI*, 4 days after onset (Fig.26-18) :small area of increased signal in the right occipital lobe in region of the visual cortex consistent with an infarct in distribution of the calcarine artery.
3. *MRA* (Fig.26-19): decreased flow in the distal right posterior cerebral artery probable embolic occlusion with filling of distal branches by anastomotic flow.
4. *Holter monitoring* demonstrated multiple brief episodes of paroxysmal atrial fibrillation.
5. The routine *transthoracic echocardiogram* demonstrated no clear cut abnormalities. However the *transesophageal echocardiogram* demonstrated a definite patent foramen ovale with right to left shunting.

Subsequent course: Reevaluation of the patient 22 hours after the onset of symptoms demonstrated clearing of all neurologic findings. When seen 2 weeks after the event her only complaint related to some problems in reading. This patient already been receiving aspirin at the time of the event and this was discontinued. She was begun on lifelong systemic anticoagulation with coumadin by the consultant cardiologist Dr. Filiberti since she had two conditions associated with embolization: paroxysmal atrial fibrillation and patent foramen ovale with right to left shunting. The patient did well over the subsequent 5 years.

Comment: When initially evaluated, the posterior cerebral artery location was clear but the pathophysiology was not. The subsequent imaging studies clearly indicated a small infarct involving the calcarine artery territory. Whether the previous sensory findings indicated some involvement of the posterior cerebral penetrating supply to the ventral posterior lateral nucleus of the thalamus remains unclear. The decreased flow in the right posterior cerebral artery was clearly demonstrated. In general as with the middle cerebral artery, cortical infarcts of the posterior cerebral artery territory, in the Caucasian population are almost always embolic. In this case the patient had two possible sources for emboli and was placed on long term anticoagulation.

The following case 26-6 presented at the onset with a transient bilateral posterior cerebral ischemia but with more severe residual symptoms reflecting unilateral posterior cerebral disease.

Case 26-6. This 75-year-old, white, right-handed widow developed sudden headache on the day prior to admission, with nausea, vomiting, and a poorly described bilateral disturbance of vision. She was found by a relative the morning of admission complaining of total blindness and of severe headache. She was noted to be confused and incoherent (believed she was in New Jersey rather than Massachusetts). She was able to walk only with assistance.

Past history: A minor degree of hypertension had been noted several days prior to admission.

Physical examination: The patient was an obese female with blood pressure elevated to 170/100. She was holding her head complaining of headache.

Neurological examination:

1. Mental status:
 - a. The patient was restless and disoriented for time and place.
 - b. There were difficulties in cooperation so that detailed testing of mental status could not be performed.
 - c. Simple calculations were poorly performed.
 - d. Digit span was markedly limited.
 - e. There was no left-right confusion and no evidence of aphasia.
2. Cranial nerves:
 - a. Initially the patient was unable to detect objects (e.g., a face or lights) in either visual field. Within six hours, a change had occurred. Although conjugate extraocular movements were full, the patient tended to keep her eye deviated to the right and failed to follow objects introduced from the periphery of the left visual field. The eyes could be deviated to the left on command.
 - b. The pupils responded to light.
3. Motor system:
 - a. Strength was grossly intact.

- b. A slight unsteadiness (ataxia) of gait was present.
- 4. Reflexes:
 - a. Deep tendon reflexes were grossly symmetrical.
 - b. A Babinski response was present on the left; a probable Babinski sign was also present on the right.
- 5. *Sensory system*: All modalities were intact.

Clinical diagnosis: Ischemia bilateral posterior cerebral arteries, cortical branches, probably embolic.

Laboratory data:

1. *Hematocrit* was normal. *Total cholesterol* was elevated to 312 mg./100 ml. The *glucose tolerance test* was consistent with diabetes mellitus.
2. Chest and skull x-rays and the electrocardiogram were normal.
3. The *electroencephalogram* demonstrated focal 3 to 4 cps slow waves in the right posterior parietal occipital area with rare slow waves in the right posterior temporal area consistent with focal damage in this area.
4. *Lumbar puncture* indicated clear spinal fluid with no cells and a normal protein of 18 mg./ml.

Hospital course: The patient had a significant improvement in headache and a clearing of confusion with a return of mental status to her normal level. Her hospital stay was prolonged by the development of thrombophlebitis of the left femoral vein. At the time of hospital discharge, one month after admission, there was still a residual left field defect (homonymous hemianopsia) with preservation of vision in the macular area (macular sparing). Follow-up evaluation approximately 14 months after discharge indicated no significant neurological findings except for the residual left field defect (homonymous hemianopsia with macular sparing) (Fig. 23-16).

Comment: The initial symptom of total blindness suggested bilateral posterior cerebral ischemia. The development of confusion and disorientation is also consistent with bilateral posterior cerebral ischemia. The nausea, vomiting, and minor ataxia of gait may well have indicated ischemia of the brain stem, suggesting that the basic occlusive process may have originated at a lower point in the basilar artery. The residual and most severe degree of involvement was certainly within the territory of the right calcarine artery.

The occurrence of severe headache is not usually considered in connection with ischemic-occlusive disease. A review of our cases of posterior cerebral occlusion indicates that the occurrence of severe headache is often a prominent symptom. Often in these cases prior to lumbar puncture, the diagnosis of subarachnoid hemorrhage was considered.

At the present time evaluation would include a CT or MRI scan. Other examples of posterior cerebral artery cortical infarcts are presented in the visual system chapter with appropriate CT scans.

The following case 26-7 provides an example of an intracerebral hematoma of unknown etiology in a young patient.

Case History 26-7. This 33-year-old white, right-handed, male linotype operator, at approximately 8:30 p.m. had the sudden onset of numbness of the left side of his mouth. At 10:30 p.m. he developed a severe right frontal headache and noted sudden onset of numbness of the left upper extremity which rapidly spread to involve the entire left side. Marked weakness of the left arm and leg developed. Evaluation that evening at his local community hospital indicated a dense left homonymous hemianopia, a marked left central facial weakness, an absence of any voluntary movement of the left arm and leg and no awareness of painful stimulation of the entire left side. A left Babinski sign was present. Lumbar puncture revealed opening pressure elevated to 235 mm. of water; and 50 fresh red blood cells per cubic mm. The patient was subsequently transferred to the neurosurgical service at New England Center Hospital.

Past history: There were no remarkable features as regards hypertension, renal disease, or diabetes mellitus. No history of drug use was obtained.

Physical examination: The patient was moderately obese with a normal blood pressure of 110/85. Examination of the heart revealed no abnormalities. No rigidity of the neck was present. There were no murmurs over the cranium.

Neurological examination:

1. **Mental status:** Orientation, speech and the ability to provide a coherent history were all intact.
 2. **Cranial nerves:**
 - a. Examination of the fundi showed no hemorrhage or papilledema.
 - b. A dense left homonymous hemianopsia was present.
 - c. Sensation was defective on the left side of the face, as well as the left side of the body.
 - d. A left central facial weakness was present.
 - e. The tongue deviated to the left.
 3. **Motor system:**
 - a. A dense flaccid paralysis of the left arm and leg was present.
 - b. There was no resistance to passive motion in the left arm and leg. and little in the left lower extremity (that is, a flaccid paralysis was present).
 - c. Cerebellar tests were negative.
 4. **Reflexes:**
 - a. Deep tendon reflexes were absent in the left upper extremity but increased in the left lower extremity
 - b. A Babinski sign was present on the left. The plantar on the right was flexor.
 - c. No grasp reflexes were present.
 5. **Sensation:**
 - a. There was no perception of pinprick or of tactile stimulus on the entire left side of the body.
 - b. Position and vibratory sensation were absent on the on the left.
- Clinical diagnosis:** Intracerebral hematoma right putamen-thalamus or embolus stem of MCA with hemorrhagic transformation.

Laboratory data:

1. Hematocrit, white blood count, and differential were all within normal limits. Sedimentation rate was normal.
2. *Tests of bleeding time, clotting time, and prothrombin time* were all within normal limits.
4. *Skull x-rays* revealed a shift of the pineal, 7 mm. from right to left.
5. *Electroencephalogram* revealed frequent focal 4 to 5 cps slow waves in the right hemisphere most prominent in the frontal and parietal areas consistent with focal damage in these areas.
6. *Arteriograms* (right common carotid) revealed a 12 mm. shift of the pericallosal branch of the anterior cerebral artery. The internal cerebral vein was also shifted 8 mm. from right to left. The middle cerebral branches emerging through the sylvian fissure were depressed. There was no evidence of an abnormal arteriovenous shunt or of an aneurysm. Cortical vessels and veins in the suprasylvian area were stretched over relatively avascular areas. The conclusion was a space-occupying mass in the right posterior frontal parietal area consistent with an intracerebral hematoma.

Subsequent course:

On the day of admission, the patient was taken to the operating room. A right parietal burr hole was made. The underlying cortex was noted by the neurosurgeon, Dr. Robert Yuan, to bulge prominently. A needle was inserted to a depth of 1 cm. into the cortex where 25 cc. of old, dark red blood under pressure was expelled. Free drainage of blood continued through a catheter which remained in place for 2 days.

Return of voluntary movement in the left lower extremity at the hip and knee was noted on the day following surgery. Reevaluation of neurological status 2 weeks after surgery, revealed continued improvement. The left homonymous hemianopsia was no longer present but the patient did have some difficulty in reading (losing the left half of the line of print). A left central facial weakness was present; voluntary hand-foot movements on the left were still not possible. Proximal muscle groups (shoulder, hip, knee) had returned to 60 per cent of normal strength. Deep tendon reflexes were now hyperactive in the upper and lower left extremities with a left Babinski sign. A dense

sensory deficit remained on the left side with no perception of pain, touch, vibration, and position in the upper and lower extremities. Reevaluation 4 weeks after surgery, revealed a return of pain and temperature sensation but continued deficits in proprioception. Reevaluation by Dr. Yuan 4 months after surgery, indicated a return of strength in the left hand with a strong grip. The gait was typical of a spastic hemiplegia. Reflexes were unchanged. Sensory examination revealed a return of primary modalities such as vibration and pain, but marked errors in cortical modalities, such as position sense, were made. Follow-up 7 months after surgery indicated an excellent return of strength on the left side but continued incoordination in the left hand due to deficits in proprioception.

Comment:

This patient from several standpoints presents a number of unusual features not seen in the typical case of intracerebral hemorrhage. The patient was relatively young (33 years old) and had no history of hypertension. He had none of those conditions such as leukemia, bleeding disorders, and the like which predispose to intracerebral hemorrhage. The arteriogram provided no evidence of an intrinsic or a secondary metastatic brain tumor. Moreover, histological examination of the tissue and drainage material obtained at the time of surgery failed to reveal tumor cells. No aneurysm was demonstrated on angiography. Although no arteriovenous malformation was demonstrated at the time of arteriography, such a malformation may have been present previously but destroyed in the process of hemorrhage. The significance of the minor prodromal sensation of numbness of the face remains uncertain. This may have reflected an initial small area of ischemia with secondary hemorrhage.

Where was the initial site of hemorrhage? In this case, the hemorrhage apparently originated in the subcortical white matter of the parietal lobe presenting as a lobar hemorrhage. The pattern of initial evolution of symptoms and the final pattern of sensory deficit is perhaps more consistent with such a parietal lobe location. From the prognostic standpoint, he did not lapse into coma and did not have compromise of brain stem functions as so often occurs when there is tentorial herniation or an extension of the hemorrhage into the ventricular system. That these various events did not occur, may in part relate to the drainage of the hematoma by the neurosurgeon with removal of this supratentorial mass lesion. The management of intracerebral hemorrhages is discussed in greater detail by Ojemann and Heros, (1983).

The following three cases provide examples of subarachnoid hemorrhage from aneurysms at the three major sites: posterior communicating-internal carotid (Case 26-8), middle cerebral bifurcation (Case 26-9) and anterior communicating –anterior cerebral junction (Case 26-10)

Posterior communicating- internal carotid junction.(Figs. 26-24)

Case 26-8: This 66-year-old white housewife, five days prior to admission, had the sudden onset of a severe bicipital bifrontal headache associated with vomiting. The headache was constantly present for 3 days but was increased by coughing. At the same time, she noted an alteration of vision in the right eye. She noted also a drooping of the right eyelid. The headache subsided, only to recur one night prior to admission as a severe occipital headache associated with vomiting. There was no past history of hypertension. The patient was admitted to her community hospital. A lumbar puncture revealed the presence of subarachnoid blood and the patient was transferred to the neurology/neurosurgical services of the New England Medical Center on 10/2/66.

General physical examination: The patient was an obese female with blood pressure of 140/80 and complaints of severe headache. Her temperature was normal.

Neurological examination:

1. *Mental status:* The patient was alert with mental status intact.
2. Cranial nerves:
 - a. Fundus: Blurred discs were present bilaterally, being greater on the right. No venous pulsations were present on the right.
 - b. Nerve III: The right pupil measured 4 mm. and was not reactive to light on direct or consensual stimulation.. The left pupil measured 2mm and was reactive to light. Ptosis of the right eyelid was present. At rest on forward gaze, there was outward deviation of the right eye. The patient was unable to adduct the right eye on left lateral gaze and failed to move this eye on upward or downward gaze. Other extraocular movements were intact.

c. Nerve VII: Minimal flattening of the right nasal labial fold was present.

3. *Motor system*: Strength, coordination, and gait were intact.
 4. *Reflexes*: Deep tendon: A minimal relative increase was present on the right. Plantar responses: The left was flexor, the right was equivocal.
 5. *Sensation*: All modalities were intact.
 6. *Neck*: Mild nuchal rigidity was present (resistant to passive flexion of head onto chest).
- Clinical diagnosis**: Subarachnoid hemorrhage due to an aneurysm at the posterior communicating–internal carotid junction.

Laboratory data:

1. Skull and chest x-rays were normal.
2. Studies of bleeding time, clotting time, and prothrombin time were all within normal limits.
3. *Arteriograms* revealed an aneurysm of the right internal carotid artery just below its junction with the posterior communicating artery. There was no left-to-right flow through the anterior communicating artery. There was narrowing of the anterior cerebral arteries near their origin bilaterally. This suggested to the radiologist the possibility of vasospasm, secondary to the presence of subarachnoid blood.

Hospital course:

Because the history suggested several episodes of bleeding, surgical therapy was selected. A right temporal craniotomy was performed by Dr. Robert Yuan with clipping of the neck of the aneurysm. The temporal lobe was retracted revealing a 13 mm.-long saccular aneurysm, arising from the internal carotid artery close to the junction with the posterior communicating artery. Distally the aneurysm enlarged into a large sac which was hidden behind the oculomotor nerve. This nerve was bulging at the point where the aneurysm, which was clipped, was well formed. The more distal sac of the aneurysm was thin and showed signs of previous rupture with yellow staining of the adjacent meninges. The sac of the aneurysm was covered with Gelfoam. Postoperatively, significant deficits as compared to the preoperative neurological status were evident. The level of consciousness waxed and waned with periods of alertness alternating with periods of apathy and drowsiness. Twenty days after surgery, she was described as sitting with both eyes closed, continuously grasping and palpating the arm of the chair with the right hand, less frequently with the left. There was a marked bilateral release of an instinctive grasp reflex. There was increased resistance in both upper extremities, at times described as plastic rigidity, at times as the “Gegenhalten,” associated with bilateral frontal lobe disease. No spontaneous voluntary movements of the left leg occurred. Bilateral Babinski signs were present. A bilateral resting tremor of the hands and of the head was also present. At times inappropriate jocularity was present. All of these findings suggested a bilateral front lobe syndrome with infarction in the territory of the anterior cerebral arteries and additional involvement of the basal ganglia. The complete paralysis of the right third nerve remained at preoperative level. At the time of hospital discharge, one month after surgery, the frontal lobe findings and the weakness in the left leg remained prominent.

Comment:

The presence of severe headache in association with a mild degree of nuchal rigidity suggests meningeal irritation. Such irritation could indicate a subarachnoid hemorrhage or a meningitis (inflammation of the meninges due to bacterial or viral infection). The sudden onset of the headache is more consistent with a subarachnoid hemorrhage. The lack of fever and of accompanying or prodromal systemic findings is also against the diagnosis of meningitis. Finally, the clearly focal third nerve findings are more in favor of the diagnosis of subarachnoid hemorrhage (although focal or multifocal neurological findings may develop as complications of a bacterial meningitis).

In this case, the significant findings on neurological examination related to the right third cranial nerve. The third cranial nerve is particularly subject to compression by aneurysms of the posterior communicating artery because having emerged from the midbrain it pursues an anterior course towards the cavernous sinus in a close parallel relationship to the posterior communicating artery. In general, compressive lesions of the third nerve produce initially an alteration in pupillary constrictor functions, then involvement of the levator palpebrae and finally involvement of the superior, medial and inferior

rectus, and inferior oblique muscles. The initial alteration in vision in the right eye and ptosis of the right eyelid at the onset of headache are then consistent with a compressive lesion. The patient at the onset of symptoms did not report a diplopia.

The third nerve as it emerges from the midbrain also passes in close relationship to the posterior cerebral and superior cerebellar arteries, but aneurysms of these vessels are much less common than those which occur in relation to the posterior communicating artery and internal carotid artery.

These findings with extrinsic compressive disease of the third nerve are to be contrasted with the pattern of intrinsic brain stem involvement of the third nerve nucleus where medial rectus or superior rectus function is more likely to be initially compromised.

The patient had minimal findings suggesting involvement of the left corticospinal and corticobulbar tracts: minimal right central facial weakness, minimal increase in deep tendon reflexes on the right side, and an equivocal right plantar response. The findings may have been produced by a slight shift of the brain stem to the left due to the small mass of aneurysm on the right side of brain stem. With such a shift, compression of the left cerebral peduncle against the tentorium might occur. In any case, these findings were minimal. The significant findings in this case clearly related to the third cranial nerve and it is these findings which allowed localization of the lesion prior to arteriography.

As regards the postoperative course, it is evident that this patient had severe involvement of the frontal lobes presumably as a result of bilateral infarction within the territory of the anterior cerebral arteries. In retrospect, the narrowing of the anterior cerebral arteries at their origin, presumed secondary to "spasm" noted at the time of arteriography, may have provided a clue as to the development of the complication. The neurosurgeon, faced with the decision as to the best time to intervene, would prefer as the ideal situation, the moment when arterial spasm has not yet developed or is no longer present but bleeding has not yet recurred. In reality the risk of recurrent hemorrhage is so great that the aneurysm should be clipped as soon as possible for example the day of presentation. Vasospasm can now be treated with calcium channel blockers and after clipping by increasing the blood pressure to increase perfusion. The typical angiographic appearance of aneurysms in this location is demonstrated in Figure 26-24. Occasionally large aneurysms can be demonstrated on the CT scan.

Middle cerebral bifurcation (Fig 26-25).

Case 26-9: This 46-year-old, right-handed, white, married male, was admitted to the neurology/neurosurgical services of the New England Medical Center on 6/10/66. He presented a history that 10 days prior to admission, he had the sudden onset of a severe, throbbing, supraorbital and vertex headache. The headache began while the patient was in bed in the early stages of sexual intercourse. The patient noted no weakness except that his tongue "felt funny" in articulation for approximately one minute. There was a transient difficulty in speech during this period.

Past history: Mild hypertension had been present.

General physical examination: Blood pressure was 160/100.

Neurological examination:

1. *Mental status* was intact.
2. *Cranial nerves* were intact.
3. *Motor system* was intact.
4. *Reflexes* were physiologic
5. *Sensory system* was intact.
6. Headache could be precipitated by *head movement*.
7. With *cervical flexion*, pain occurred in the neck and lumbar area occurred.

Laboratory data:

1. Skull and chest x-rays were normal.
2. *Electroencephalogram* revealed focal damage in the lateral aspect of the left hemisphere (focal 3 to 5 cps slow waves).
3. *Lumbar puncture* on the day following admission revealed opening pressure elevated to 270 mm. of water and closing pressure to 210 mm. of csf. The fluid was xanthochromic (yellow discoloration). In addition 38 fresh red blood cells per cubic mm. were present. Protein was elevated to 80 mg./100 ml. Hinton was negative.

4. *Arteriography* revealed a bilobed aneurysm at the trifurcation of the left middle cerebral artery measuring 8 x 4 mm. Spasm and narrowing of the proximal anterior and middle cerebral arteries were noted.

Hospital course:

On the day following admission, the patient complained of a few-minute episodes of numbness in the right face, tongue, and right upper extremity with thickness of speech. Examination now revealed right central facial weakness and slight slurring of speech. The patient also now complained of additional neck pain on extreme forward flexion. On June 12, 1966, the patient had another short episode beginning with numbness over the right thumb, spreading to the right hand and then to the angle of the mouth.

Because of the several episodes which occurred, following hospital admission, involving the right face, tongue, and hand in association with the finding of fresh red blood cells in the spinal fluid, it was considered likely that bleeding from the aneurysm was continuing to occur. Surgical therapy was therefore considered necessary to prevent additional (and possibly fatal) subarachnoid hemorrhage. On May 20, 1966 a left frontotemporal craniotomy was performed by Dr. Robert Yuan with subsequent plastic coating of the entire aneurysm to reinforce its wall. There was evidence of recent hemorrhage in the subarachnoid space with yellow discoloration of the meninges. In order to expose the aneurysm, it was necessary to remove the anterior tip of the temporal lobe back to a distance of 2.5 cm. There was a small amount (5 to 10 cc.) of intracerebral blood clot in the superior temporal region close to the aneurysm. The aneurysm itself had no actual neck that could be clipped. Several middle cerebral branches appeared to arise from the dome or lateral wall of the aneurysm.

In the postoperative period, the patient initially did well. A minor expressive aphasia was present, but the patient was alert and well oriented. However, fever and jaundice developed. With the development of significant alterations of liver functions approximately 7 days after surgery, the patient became confused and agitated. The prothrombin time fell to 3 per cent of normal and there was evidence of bleeding into the gastrointestinal tract at this time. The prothrombin deficit was corrected by administration of vitamin K. It was unclear, however, as to whether any minor intracranial bleeding occurred during this time. Some improvement in liver functions occurred, and the patient became more alert but continued to manifest inappropriate behavior, emotional lability, and disturbance of memory. He left the hospital against medical advice one month after surgery, on July 20, 1966.

The patient was readmitted to the hospital approximately one month later on August 13, 1966. For two days, the patient had been less active, appeared confused, glassy eyed, and failed to communicate. The degree of obtundation cleared when adequate dosage of the anticonvulsant medication, Dilantin, was administered. This fact taken on conjunction with the electroencephalogram, which demonstrated frequent focal spikes (excessive neuronal discharge) in the left temporal area (Fig. 29-1C) led to the conclusion that the episode which precipitated his readmission might well have represented a prolonged seizure discharge. The electroencephalogram also demonstrated an increase in slow wave activity in the left hemisphere, particularly the left temporal area indicating a possible increase in damage in the left temporal area. This appeared to be correlated with apparent progression of the patient's aphasia which was now receptive as well as expressive in nature. At the time of discharge, a severe expressive aphasia was still present.

Comment:

The sudden onset of severe headache during exercise or exertion (sexual intercourse in this case) is characteristic of subarachnoid hemorrhage. The location of the aneurysm was suggested by the symptoms relevant to the tongue and speech during the initial episode. The episode on June 11, 1966, involving numbness of the right face, tongue, and right upper extremity, could only indicate disease within the territory of the left middle cerebral artery. The lumbar puncture at this time indicated not only evidence of the initial leakage of blood 10 days prior to admission (an elevation of cerebrospinal fluid protein and a xanthochromia), but also fresh red blood cells suggesting that additional leakage of blood had occurred.

The nature of the episodes which occurred on June 11 and 12 is not certain. Most likely these were ischemic in nature related to decrease in blood flow as a result of clot formation within the aneurysm or from spasm of the adjacent portion of the middle cerebral artery. At times, however, symptoms such as rapidly spreading numbness occurring in episodes may suggest focal epileptic discharge. The development of an area of excessive discharge would not be unusual since this aneurysm involves those

middle cerebral artery branches which are supplying the cerebral cortex. In addition hemorrhage within the Sylvian fissure is likely to damage the surrounding cerebral cortex. Blood and iron are epileptogenic.

The patient's course following surgery was complicated by the development of severe liver dysfunction. The etiology of this problem was never clear, the various studies suggesting either a toxic hepatitis related to various drugs and anesthetic agents or a variety of obstructive jaundice. What the patient's eventual recovery would have been had this problem not developed is uncertain. It is clear, however, that during this post-

operative period the patient did develop significant impairment of language functions, possibly related to infarction or oozing of blood in areas supplied by the middle cerebral artery. It is also evident that a seizure focus had developed in this area. Such seizure foci may have developed in relation to the preoperative hematoma noted in the temporal lobe, in relation to the surgical manipulation of the area, or in relation to the postoperative complications.

Today (2002), the history presented by this patient would have prompted an immediate CT scan and a lumbar puncture if the CT scan were negative. An arteriogram would have been performed immediately after these studies. Surgery would have been performed immediately after the evaluation of the angiographic studies to prevent the recurrent episodes of bleeding.

Anterior communicating -anterior cerebral junction(Figs. 24-26, 24-27, 24-28)

Case History 26-10. . (Patient of Dr. John Sullivan). This 49-year-old, right-handed truck driver was transferred from his local community hospital for evaluation of subarachnoid hemorrhage.

The patient had experienced occasional frontal headaches for the previous 5 years. In June, 1965, while changing a tire, he had a severe throbbing frontal headache which cleared after thirty minutes. Since that time he had experienced daily throbbing frontal headaches, usually present on arising in the morning. On September 4, 1965, the patient had the onset of a particularly severe headache which began while he was engaged in heavy work on a boat. There was associated stiffness of the neck, nausea, vomiting, and a general sensation of weakness.

Evaluation at his local community hospital revealed papilledema (blurred optic disk margins on funduscopic examination). Nuchal rigidity was present. The lumbar puncture demonstrated grossly bloody cerebrospinal fluid. He was subsequently transferred to the neurology/neurosurgical services of the New England Medical Center on 9/7/65.

Past history:

1. Hypertension had been noted in June, 1965.
2. The patient's father had died at age 59 of a cerebrovascular accident.

General physical examination:

1. Blood pressure was moderately elevated to 180/100. Pulse was 60.
2. No bruits (murmurs) were present over the skull.
3. A significant degree of nuchal rigidity was present. The neck could not be actively or passively flexed.

Neurological examination:

1. Mental status:
 - a. The patient was somnolent but could be aroused, although attention span was noted to be shortened.
 - b. He was oriented for place and situation but confused as to time.
 - c. Digit span was shortened to 5 forward and 4 in reverse.
 - d. The patient was unable to do calculations.
2. Cranial nerves:
 - a. Sense of smell was decreased on the right side.
 - b. Disk margins were indistinct on examination of the fundus. Arterioles were tortuous and irregular.
3. Motor system:
 - a. Strength and tone were intact.
 - b. Cerebellar tests were normal.
4. Reflexes:
 - a. Deep tendon reflexes were symmetrical.

- b. Plantar responses were flexor.
- 5. Sensory system: All modalities were intact.

Laboratory data:

1. Bleeding, clotting, and prothrombin times were all normal. Platelets were normal on smear.
2. Chest and skull x-rays were normal.
3. *Arteriograms* demonstrated an aneurysm of the anterior communicating artery which extended posteriorly and to the right. The aneurysm filled from the left carotid circulation.

Hospital course: During the evening of September 11, 1965, the patient became lethargic and would not speak or obey commands. Blood pressure rose to 240 mm. systolic. The patient became totally unresponsive with pupils fixed and dilated and with incontinence of urine. Deep tendon reflexes were exaggerated with plantar responses extensor. Within minutes, the patient became responsive again; pupils were reactive, although the right remained sluggish. The patient made purposive movements and obeyed commands. Lumbar puncture subsequently indicated grossly bloody spinal fluid. The patient remained confused and less alert with a tendency to fall asleep.

On September 17, 1965, the patient again suddenly complained of violent headache and lost consciousness for approximately 30 minutes. The right pupil became dilated, and the right eye deviated to the right suggesting a right medial rectus weakness. The blood pressure again rose to 240/140. As previously, the patient regained consciousness. Although confused, he had no clearly lateralizing signs. Subsequent lumbar puncture again revealed the presence of fresh red blood cells.

Because repeated episodes of bleeding had occurred, surgical therapy was undertaken. On September 21, 1965 a left frontal craniotomy was performed by Dr. Robert Yuan. The left frontal pole was resected exposing the left anterior cerebral artery and the aneurysm which arose from the anterior communicating artery. The medial surface of the right frontal lobe was cystic and contained 20 cc. of hematoma. The hematoma was evacuated. The aneurysm was reinforced by spraying with a plastic coating.

Neurological examination approximately 1 week after surgery indicated that the patient was confused and disoriented, with a "rather negative response" refusing to follow directions and to speak to examiners. Blood pressure was noted to be extremely labile with a drop of 50 mm. of mercury systolic when the patient moved from prone to sitting position. Equivocal Babinski signs were present, and the patient was incontinent of urine and feces.

Reevaluation on November 17, 1965, approximately two months after surgery, indicated that although the patient was ambulatory and able to take care of his daily needs, he remained confused for time and place. When the patient was examined 6 months after surgery, confusion was no longer present; intellectual functions were consistent with his education.

Approximately 2 years after surgery, the patient, who had recently been married, reported that he was impotent, unable to obtain an erection.

Comment:

In this case, the history of sudden onset of severe headache and stiffness of the neck, precipitated by exertion, clearly suggested a subarachnoid hemorrhage originating from the rupture of an intracranial aneurysm. It is likely that several episodes of subarachnoid bleeding occurred in June and September of 1965. While the clinical findings of somnolence and confusion with a decrease in olfaction on the right may have suggested the possibility of an anterior communicating-artery location, these were certainly not firm diagnostic clues. The episodes characterized by sudden alteration in blood pressure, while nonspecific, might have raised the question of orbital-frontal, anterior cingulate, or hypothalamic effects (areas within the distribution of the anterior-cerebral arteries).

The negativity of the patient following surgery undoubtedly indicated preoperative and operative damage to the orbital and prefrontal areas. The bilateral Babinski signs and the incontinence of urine and feces in the postoperative period probably reflected damage to the parasagittal motor and premotor areas within the distribution of the anterior cerebral arteries. The impotence may have reflected damage at the frontal or hypothalamic level.

Today, an initial episode such as occurred in June 1965 would have prompted a CT scan and a lumbar puncture if that study had been negative. Of course many exertional headaches are not a result of

subarachnoid hemorrhage. Nevertheless the more serious entity must be ruled out at the emergency room level, since the mortality and morbidity of the frequent recurrent hemorrhage are so high. Again the use of early arteriography and early surgery are to be emphasized.

Case 26-11 illustrates many of the neurologic aspects of bacterial endocarditis.

Case 26-11: This 34-year old right hand married white male hair dresser was admitted with a one month history of night sweats, fever to 102-103° F., generalized aches and pains. Within the previous 3-4 months, the patient had undergone repeated dental procedures for dental infection. He had been reported to have a mild heart murmur 2-3 years prior to admission. His urine had recently become dark. The day prior to admission he had noted a small hemorrhagic lesion on the dorsum of his left hand.

Physical exam:

1) Skin: A small indurated red lesion dorsum left hand and a small red lesion under the nail bed 3rd left toe.

2) Heart: A grade IV/VI high-pitched holosystolic murmur was present at the apex; and a high-pitched II/VI murmur at the base; both not previously noted to this degree.

3) Temperature was elevated to 101° F

Neurological examination: Entirely within normal limits.

Clinical diagnosis: Bacterial endocarditis with systemic emboli but without neurological symptoms at this point.

Laboratory data:

1) **CBC:** Anemia with hematocrit 31 and hemoglobin of 10.1.
White blood count was 9900 with differential of 78% poly-morphonuclears and 9 atypical lymphocytes.

2) Sedimentation rate was elevated to 38 mm.

3) **Urinalysis** indicated 8-10 red blood cells per high power field.

4) All three **blood cultures** drawn on the day of admission produced growth of streptococcus viridans (alpha hemolytic).

5) **Echocardiogram** indicated a prolapsed mitral valve with probable mitral insufficiency. In addition, irregular densities on the mitral leaflets suggested vegetations.

Hospital course: All of these findings were consistent with a diagnosis of subacute bacterial endocarditis with evidence of microemboli to extremities (skin lesions) and to kidneys (hematuria). The patient was begun on high dosage intravenous penicillin (24 million units per day) with an excellent response as regards fever and general symptoms. Thirteen days after admission he again developed a temperature elevation. The following day, at 2 p.m., he abruptly developed difficulty with speech and a right hemiplegia. Over the next 2 hours this rapidly evolved to the following neurological state.

Neurological examination:

1) Mental Status and Language Function

a) The patient was drowsy - holding the left side of his head as though in pain.

b) He was mute.

c) He was unable to carry out any spoken or written commands.

2) Cranial Nerves

a) The patient neglected the right visual field and had no response to threat in the field.

b) The fundusoscopic exam indicated blurring of the disc margins on the left.

c) Right central facial weakness was present.

d) Pain sensation was decreased on the right side of the face.

3) **Motor System:** A flaccid right hemiparesis was present although some purposive withdrawal of the right arm and leg occurred on painful stimulation.

4) Reflexes

a) Deep tendon reflexes were increased bilaterally but right were greater than left with clonus of the right ankle.

- b) The right plantar response was extensor, the left flexor.
 - 5) *Sensation*: A right-sided hypalgesia was present. Other modalities could not be tested.
 - 6) Neck and Skin
 - a) No nuchal rigidity was present.
 - b) New splinter hemorrhages were present under the nails of the upper extremities.
- Neurological diagnosis:** Cerebral embolus left middle cerebral artery, with possible mycotic aneurysm and possible hematoma left middle cerebral artery secondary to bacterial endocarditis.

Laboratory data:

An immediate CT Scan (Fig. 26-30) demonstrated a large intracerebral hematoma involving the left basal ganglia and insula with massive shift of the left hemisphere to the right.

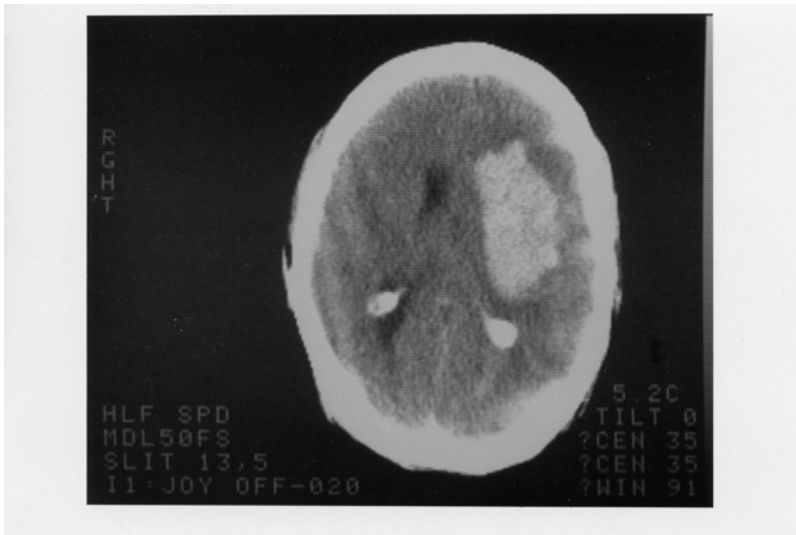
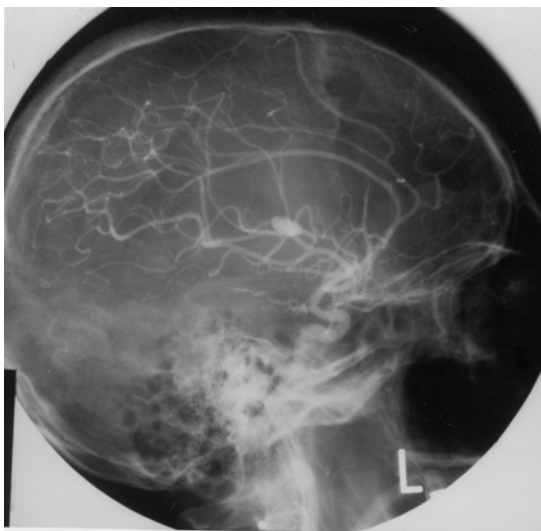


Figure 26-30.

2. An immediate arteriogram: (Fig. 26-31A) demonstrated a small aneurysm (arrow) arising from a small branch of the left middle cerebral artery (MCA) within the Sylvian fissure. A large avascular area surrounded this aneurysm with upward and lateral displacement of anterior cerebral arteries, medial displacement of lenticular striate, branches of the MCA and lateral and downward placement of the cortical MCA branches.



Subsequent course: That evening Dr. Robert Johnson removed a large intracerebral clot. Over the next 2 weeks the patient began to have some improvement in his right hemiparesis and aphasia. However two weeks after surgery, he developed right-sided focal status epilepticus. The patient had been receiving Phenytoin (Dilantin) but the level was low. Intravenous Phenytoin, intravenous Dexamethasone and Mannitol were administered. The CT scan now demonstrated a larger hemorrhage surrounded by edema. The patient was taken to surgery and additional old clot and a small amount of recent clots were removed. The patient failed to respond. He developed fixed dilated pupils and bilateral Babinski signs. The arteriogram (Fig.26-31 B,C) was repeated and now demonstrated a much larger aneurysm (measuring 11 mm vs 4-5 mm in previous films). There was also evidence of additional shifts of the anterior cerebral artery and internal cerebral vein. Anterior-frontal branches of the middle cerebral artery were occluded. Regression occurred and 8 days later patient met brain death criteria with absence of all brainstem reflexes, no spontaneous respirations and an absence of all cerebral electrical activity (silent EEG).

Comment: This patient presents a panorama of almost all of the cerebral complications of bacterial endocarditis including:

- a) Multiple septic emboli to brain, kidney, and small peripheral arteries;
- b) Mycotic aneurysm;
- c) Intracerebral hematoma
- d) Eventual mortality.

The mycotic aneurysm with eventual rupture was not a feature noted on presentation but instead was a late complication. (A silent unruptured aneurysm may well have been present on admission.) This subacute delayed presentation is more common in streptococcal endocarditis as opposed to the more virulent staphylococcal infections where acute intracranial presentations are the rule.

In this case, the aneurysm when initially discovered was small and associated with an intracerebral hemorrhage.

The aneurysm continued to enlarge after evacuation of the initial hematoma and eventually additional hemorrhage occurred. Not all patients with mycotic aneurysm will have intracranial hemorrhage. In the series of Brust et al (1990), 41% were associated with rupture. Of 20 aneurysms followed with angiography or CT scan, ten became smaller or disappeared, 10 remained unchanged or enlarged despite an adequate treatment course with antibiotics. In the present case, initial rupture occurred almost 2 weeks after admission and beginning of antibiotic treatment.

The recommended approach in patients with endocarditis to avoid the fatal complications of mycotic aneurysm rupture is to perform 4 vessel angiography in those patients with endocarditis who develop neurological symptoms. If a mycotic aneurysm is found, prompt surgical treatment (clipping) should be performed. Unfortunately many patients with mycotic aneurysms have no neurological symptoms prior to rupture. To perform angiography in all patients with bacterial endocarditis, would not be practical and would fail to detect aneurysms that developed after the studies. However, when long-term anticoagulation is planned in patients on the completion of antibiotic treatment to prevent additional emboli, angiography should be performed or repeated. The entire role of anticoagulation in bacterial endocarditis remains unclear. (See Salgade et.al 1987 and Hart et.al 1987, 1990). MRI may have an increasing role in non-invasive diagnosis, since MRI angiography should be able to detect aneurysms greater than 2-3 mm in diameter

Figure 26-32. Arteriovenous malformation in the right parietal area demonstrating the abnormal tangle of vessels and infarction of the surrounding cerebral cortex and white matter.

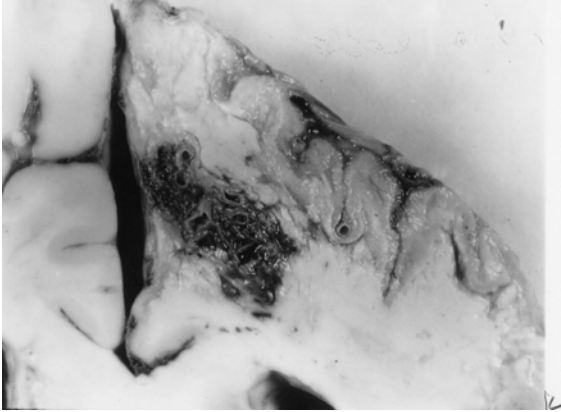


Figure 26-32. In this case, the malformation was fed mainly by the right anterior cerebral artery and drained into the superior sagittal sinus. This 46-year-old woman had, as a primary problem, subarachnoid hemorrhage from an anterior-communicating saccular aneurysm, with other unruptured aneurysms at left posterior communicating, and right superior cerebellar. (Courtesy of Dr. John Hills).

Case history 26-12 provides an example of a long-term unruptured arteriovenous malformation presenting as a seizure disorder.

Case 26-12: This 51-year old right-handed female experienced two nocturnal generalized convulsive seizures 6 years prior to evaluation . Evaluation by Dr. Robert Bazemore at that time revealed a significant 30-year history of minor episodes: “little sensations”. The patient described sudden strange feelings as though moving in slow motion. With other episodes she would feel at a distance from her surroundings with a sense of detachment at times with a strange odd smell. After 2-3 minutes the “spell” would alter, she would feel depressed with a sense of terrible fear. The patient also had a long history of migraine headaches (bilateral throbbing) which were often preceded by visual auras more prominent in the right visual field. The neurological examination was normal. She was treated with anticonvulsant (Phenytoin). When seen by the author for other unrelated neurological problems 6 years later , the interval history indicated no additional generalized seizures but complex partial seizures had continued.

Neurological examination: entirely within normal limits.

Clinical diagnosis : Simple and complex partial seizures of temporal lobe origin .

Laboratory data:

1. The *CT scan without enhancement* now demonstrated a calcified lesion in the anterior-medial right temporal lobe which enhanced with contrast (Fig. 26-32A). Large early draining veins were also noted (Fig. 26-32B).

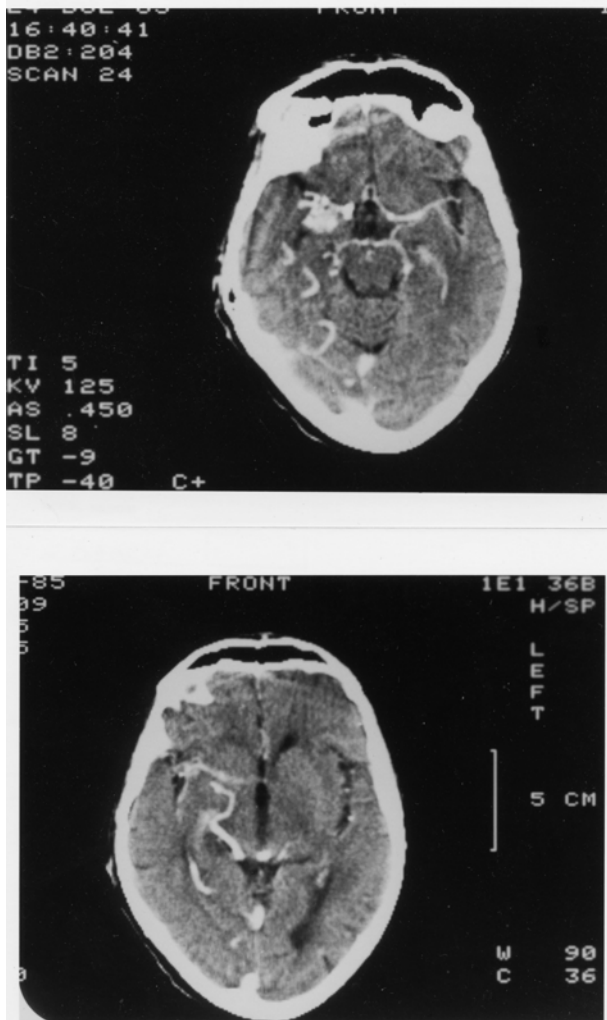


Figure 26-33. Arteriovenous malformation. Right anterior temporal:
Case History 24-12 CT Scan. This 51-year-old right-handed female
was evaluated in 1983. She had generalized seizures in 1977 and 36-
year history of complex partial seizures. She would feel "weird
sensations" and detached with a "strange odd smell", then a sense of
terrible fear. She also had a history of migraine headaches preceded
by visual auras, and a normal neurological examination. was not
remarkable. The CT Scan without contrast demonstrated a calcified
lesion in the right anterior temporal lobe (not shown).
A). With contrast a large enhancing lesion was present in the deep
Sylvian fissure area - involving anterior medial temporal areas, uncus
and adjacent insula.
B) At a higher level of section a large draining vein was visualized (see
also fig 26-35 and text for details).

Subsequent angiographic studies confirmed the anterior venous malformation with supply from right internal carotid, middle cerebral and anterior choroidal arteries (26-33A) and the presence of shunting into a large early draining vein (26-33B).

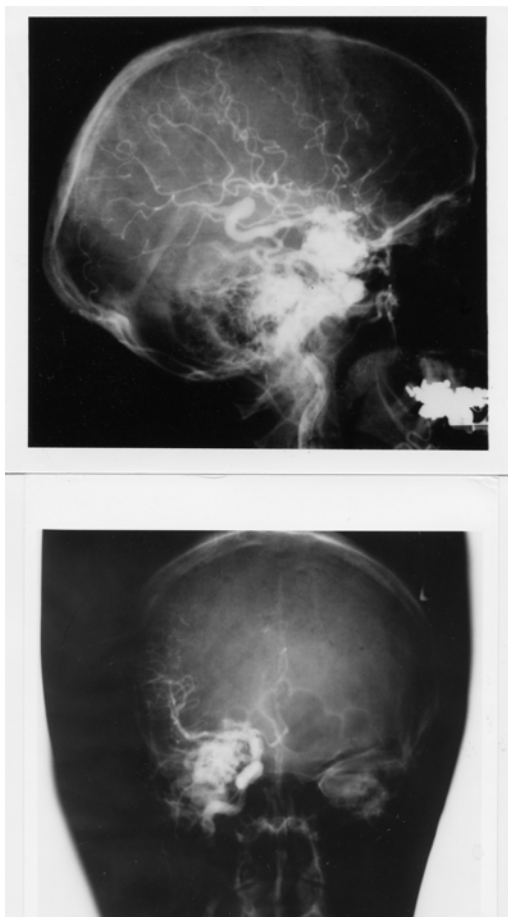


Figure 26-34. Arteriovenous malformation: Right anterior temporal lobe. Right carotid arteriograms. Case History 24-12

- A) Malformation - supplied by right internal carotid, middle cerebral, and anterior choroidal branches.
- B) There is early shunting of arterial blood into a large draining vein. See Text and Fig. 26-34 for details.

Comment: This patient presented with classical complex partial seizures originating in the right temporal lobe. No definite evidence of either subarachnoid or intracerebral hemorrhage was present over 35 years. With the use of CT and MRI scan, more of these lesions are being identified in an unruptured state in patients investigated for seizures and headaches.

Considerable controversy remains as to the appropriate therapy for the unruptured cerebral arteriovenous malformation (compare Aminoff, 1987 and Heros and Yong-Kwang, 1987). Long-term follow-ups - 12-20 years - does suggest a 25-39% risk of hemorrhage with a mortality from that hemorrhage of 10-14%. The risk of recurrent hemorrhage the first year is 6% with the subsequent annual risk for hemorrhage for both ruptured and unruptured 3% per year (see also Crawford et al, 1986, Brown et al 1988, Rigamont, et al 1988).

Surgical therapy involved excision after ligation or embolization of feeding vessels (Stein and Wolpert, 1986, Stein and Mohr, 1988, and Mohr, et al 1986).

CHAPTER 27: NON VASCULAR SYNDROMES : TRAUMA, TUMORS, INFECTIONS, TOXIC METABOLIC AND SYSTEMIC DISORDERS

I TRAUMA

Case 27-1 presents an example of an epidural hematoma seen in 1963 prior to modern neuroimaging.

Case 27-1: This twenty-two-year-old, white airman, during a winter storm, was involved in an auto accident at 11:30 p.m., in which he struck his head against the windshield. He also sustained minor abrasions of the shoulder, hands and chest. The patient apparently was dazed, perhaps unconscious, for a matter of seconds to minutes. He was taken by ambulance to the emergency room of the nearby army hospital where a brief evaluation indicated that the patient was alert, without definite neurological findings, and apparently without significant injuries. Skull X-rays did indicate a linear fracture over the right temporal area which did not, however, definitely cross the major groove of the middle meningeal artery. The patient was, therefore, admitted to the intensive care ward for head injury observation.

The patient was apparently alert upon his arrival on the ward. It should be noted, that the major attention of the physicians in the emergency room and of the nurses on the intensive care ward was given to four other patients from the same accident who sustained very severe and obvious injuries. However, by 5 a.m., the patient was reported by the nurses to be agitated and confused.

Neurological examination: (8 a.m.)

1. *Mental Status:* The patient was agitated and unable to cooperate. He was sitting up in bed, holding his head, moaning and hyperventilating to a marked degree. He answered only occasional questions and then with a yes or no.

2. *Cranial Nerves:* intact except

Fundi: The examination was negative but incomplete.

Pupils: There was a bilateral but sluggish response to light. A minimal asymmetry was present. The right pupil was perhaps slightly larger and slightly more sluggish than the left.

3. *Motor System:* All limbs were moved spontaneously. There was a variable increased resistance to passive motion, but this was apparently due to the patient's inability to cooperate.

4. *Reflexes:* Deep tendon reflexes were increased bilaterally. Plantar responses were bilaterally equivocal.

5. *Sensation:* Pain sensation appeared to be intact.

6. *Neck:* There was variable resistance to attempted flexion.

7. *Head:* The patient moaned when palpated over left or right temporal areas.

Neurological diagnosis : Possible evolving acute bilateral epidural or subdural hematoma

Subsequent course: The patient was to be evaluated by the civilian neurosurgical consultant, whose arrival was delayed by several other emergencies and a snowstorm. In the meantime, progression occurred.

Neurological examination (4 p.m.): The patient was now deeply comatose with little response to stimulation. The pupils were now bilaterally fixed and dilated. The four limbs were extended in a decerebrate posture with significant spasticity on passive motion. The degree of spasticity in the upper limbs could be modified by tonic neck maneuvers. The plantar responses were bilaterally extensor. Spontaneous respirations were now irregular and infrequent, and the patient required the assistance of a mechanical respirator.

Neurological diagnosis: Acute tentorial herniation with brain stem compression secondary to epidural hematoma.

Subsequent course: A general surgeon immediately performed definitive therapy. Bilateral burr holes were placed. An epidural hematoma over the right temporal-parietal area was evacuated and the

bleeding middle meningeal artery branch was coagulated and ligated with a significant rapid improvement in the patient's status. Follow-up examination approximately two months later indicated that the patient had returned to active duty but was experiencing some problems related to changes in recent memory and to changes in motivation and personality. No significant motor or sensory findings were present. Minor and inconsistent asymmetry of deep tendon reflexes was present.

Comment: This patient followed the usual pattern of a short lucid period followed by the rapid progression of confusion, agitation, coma and brain stem deterioration of function. As indicated by Plum and Posner (1980), the development of hyperventilation is often indicative of a midbrain-upper pontine stage of damage from an expanding supratentorial lesion. The early appearance of hyperventilation followed by bilaterally fixed dilated pupils and a decerebrate state may well indicate that the supratentorial lesion was producing a more central downward compression of the midbrain and less of a lateral uncal-type compression. In any case, it is evident that brain stem compromise was progressing rapidly. So rapidly, in fact, that therapy had to be undertaken immediately. In such a case, there was no longer time for the transfer of the patient to a specialized treatment center and no longer any time for specialized laboratory studies. Today, such a patient would have undergone CT scan studies at the time of emergency room evaluation or at the first sign of change in mental status. Similar cases of recovery of function from brain stem compression in patients with acute subdural or epidural hematomas have been reported by Brendler and Selverstone (1970).

The following case provides an example of chronic bilateral subdural hematomas

Case 27-2. (Patient of Dr. Alex Danylevich). This 83-year-old white female was transferred from her local hospital because of increasing confusion. Two months prior to admission, she had been involved in a motor vehicle accident sustaining fractures of her ribs and left clavicle. She also struck her head and had a scalp hematoma in the right frontal area. She was admitted to her local hospital at that time for several days. She was described as having post-traumatic anterograde and retrograde amnesia and obtundation which cleared over her hospital stay. She returned to her usual activities. Two months after the trauma she re-entered her local hospital with a three day history of increasing confusion and lethargy. When she became mute she was transferred to St. Vincent Hospital. Serum sodium at her local hospital had been low at 124 mEq/liter and CSF protein was reported at 62 mg%. EEG was reported as diffusely slow.

Neurological examination:

1. *Mental status:* She was relatively lethargic but could be aroused to an alert state. The patient was mute and did not follow commands even when relatively alert.
2. *Cranial nerves:* Pupils were 2 mm. and reactive. Sudden paroxysmal nystagmoid deviations of the eyes to the right occurred during the exam.
3. *Motor system:* Strength was intact. Tone was increased in the right leg.
4. *Reflexes:* Deep tendon stretch reflexes were symmetrical. Plantar responses were extensor bilaterally.
5. *Sensory system:* Pain responses were intact.

Clinical diagnosis: Chronic subdural hematomas, probably bilateral .

Laboratory data:

1. The CT scan (Fig. 27-3) demonstrated significant bilateral chronic subdural collections much denser on the left where the lateral ventricle was obscured and shifted to the right. The right lateral ventricle and sylvian fissure were enlarged. There was a question of additional recent rebleeding into the subdural collection on the left.
2. Serum sodium was low at 117 mEq/liter. Serum osmolality was 236. Urine sodium was 53 mEq/liter.

Hospital course: Serum sodium was corrected. Then, bilateral subdural hematomas were removed via burr holes on the right and a bone flap on the left where substantial chronic membrane and fluid were found. Neurological examination eight hours after conclusion of the procedure, indicated an alert patient who had no apparent language disorder and no weakness. Follow-up CT scan ,6 days after surgery revealed re-expansion of the cerebral hemispheres. Considerable cortical atrophy was

now evident. This was presumably long-standing predating the subdural hematomas. She was transferred back to her local hospital, 10 days after surgery. At that point she was alert; ambulating with assistance and was able to feed herself. She did develop transient right face and hand focal motor seizures which were treated with anti-convulsants.

Comment: If the history of trauma two months previously had not been present with a prior hospital admission related to the trauma, the confused obtunded mute state in this patient might easily have been attributed to a metabolic encephalopathy (low serum sodium) or to the cortical atrophy of a senile dementia of Alzheimer's type. Many patients with primary cerebral disease will develop a low serum sodium due to inappropriate secretion of anti-diuretic hormone with retention of water and dilution of serum sodium. The mute state in this patient in retrospect probably reflected the severe involvement of the dominant left cerebral hemisphere. The sudden eye movements to the right probably represented focal seizure activity originating in the left frontal eye fields, not far from the cortical area providing the focus for the post operative seizures.

In some patients without a definite history of trauma, the predominant findings may be those of a progressive bilateral frontal lobe involvement with confusion, bilateral grasp reflexes, and a frontal lobe apraxia of gait. In such patients, the nature of the pathological process involving the frontal lobes may be uncertain. The differential diagnostic list may include metastatic disease, frontal parasagittal meningioma or frontal glioma.

There are patients who are at increased risk for subdural hematomas: patients receiving anticoagulant medications, or patients with bleeding disorders, e.g., as in leukemia. The problem is more common in the elderly, in chronic alcoholics, and in patients with Parkinson's disease perhaps because such population groups are more prone to unsteadiness and falls. In the patient with cortical atrophy as in Alzheimer's disease, the bridging veins may be stretched and thus more prone to tear. In addition, the patient is unable to recall minor trauma and is already confused. In addition, because of the atrophy, a large amount of blood may accumulate in the subdural space without producing early symptoms of headache and other symptoms.

The problem also exists in the infant during the first year of life. The picture presented, however, differs significantly from that seen in the adult because in the infant, separation of the sutures may occur, allowing the intracranial cavity to expand. The onset is then often nonspecific and nonfocal: an enlargement of the head, a failure to thrive, a failure to gain weight, a failure to reach developmental landmarks. At times, generalized seizures, vomiting, and papilledema may be noted. The etiology often relates to presumed birth trauma.

A related problem may also be seen in infants following meningitis. This is the problem of subdural effusions usually occurring in relation to *Haemophilus influenzae* meningitis. The diagnosis of both subdural hematoma and subdural effusions may be made in the infant by CT or MRI scan replacing the earlier technique of subdural taps. The cerebrospinal fluid in these cases is often found to be abnormal with the presence of blood or xanthochromia and an elevated protein content.

II TUMORS

The following case history provides an example of the course of a low grade glial tumor.

Case 27-3: This 41 year old right handed white widow was admitted to the hospital because of increasing frequency of seizures. At age 30, eleven years prior to admission, the patient experienced her first generalized convulsive seizures. The neurological examination and the electroencephalogram were normal. Four years prior to admission, the patient had a change in the character of her seizures, she began to experience focal seizures involving the right arm and leg. These would begin with the sensation of a "chill" or stiffening of the right leg and a "numbness" (a tingling) which would then spread to the lower back. At the same time, weakness would occur in the right leg followed by repetitive clonic movements of the right arm. During this time, the patient would be unable to talk distinctly but would be aware of her surroundings. Although the episode continued for several minutes, there was no apparent loss of consciousness. Examination by Dr. John Hills at that time revealed a slowness of response but no definite neurological deficits. The EEG was again normal. Neurological evaluation three years later (one year prior to admission) was again unremarkable although focal seizures were still occurring every 2-4 weeks. Evaluation 2 months prior to admission, now indicated a more increase in deep tendon stretch reflexes in the

right lower extremity and an equivocal plantar response on the right side .Hospital admission finally occurred because the weakness experienced in the right leg during the seizure was becoming more severe.

Neurological examination

1. *Mental status*: The patient was anxious and tremulous with moderate psychomotor retardation and poor attention span. Digit span was limited to 5 digits forward and 4 in reverse .However orientation, memory ,delayed recall , calculations and language function were all intact.
2. *Cranial nerves*: All were intact with no papilledema.
3. *Motor system*: Strength, gait and cerebellar signs were all normal.
4. *Reflexes*: Deep tendon reflexes were slightly increased on the right side. The plantar response on the right was equivocally extensor.
5. *Sensory system*: Intact except for a minimal bilateral decrease in sensation at the toes.

Clinical diagnosis: Left parasagittal tumor most likely a meningioma, low grade glial tumor such as oligodendroglioma or low grade astrocytoma considered possible but very unlikely.

Laboratory data:

1. Chest and skull x rays ,radioactive brain scan(Hg 197) and left carotid arteriogram were all normal.
2. *EEG* was now mildly abnormal because of occasional focal sharp waves ,left parietal parasagittal area.
- 3.*Pneumoencephalogram* demonstrated a slight downward depression left lateral ventricle suggesting a possible left parasagittal mass. The CSF obtained was normal.

Subsequent course: Since the brain scan and arteriogram were normal, a meningioma was considered unlikely and a low grade glioma was considered the most likely diagnosis. The lack of calcification on the skull x rays was considered a point against the diagnosis of an oligodendroglioma and more in favor of a low grade astrocytoma. Since the patient was relatively free of neurological deficit and the dominant hemisphere was involved, neurosurgical intervention was deferred .Her anticonvulsant medications were readjusted. Frequent office evaluations indicated that significant progression was occurring with increasing weakness of the right leg, and an inability to form letters in handwriting. .Four months after hospital discharge ,the patient now had a right central facial weakness ,a mild right hemiparesis, and increased deep tendon stretch reflexes on the right and a right Babinski sign. Speech was dysarthric with a minor degree of misnaming or inability to name objects. A left carotid arteriogram now indicated a deep left posterior frontal mass lesion. There was also a suggestion of abnormal vascularity in the region of the pericallosal and callosal marginal branches of the anterior cerebral artery. Surgical exploration of the left frontal area indicated slight discoloration of and widening of gyri. Probe counting located an area of increased uptake of isotope (P32) at 16X normal in the mid and posterior frontal area. A partial frontal lobectomy was performed from the level of the sphenoid wing laterally and forward but sparing the speech areas. However tumor was still present at the posterior margin of the resection . Histologic examination of the tumor removed indicated a grade I- II astrocytoma. Following surgery ,the right sided weakness progressively improved, speech was unchanged. Following hospital discharge the patient ,received a 3 month course of supervoltage radiation (7,500 roentgens)directed to the left frontal parietal area. When last evaluated 18 months after surgery, there was a moderate disorientation for time , a nominal aphasia a slowness in following commands ,a perseveration of speech and performance, a right central facial weakness and a clumsiness in following commands.

Comment: The onset of seizures at age 30 ,always raises the question of a possible brain tumor. The initial seizures however were generalized convulsive seizures and the neurological examination and the EEG were normal, thus decreasing the risk of a tumor. When focal seizures appeared at age 36,the risk of a tumor was significantly increased but still ,the exam and the EEG remained normal .In retrospect ,the slowness of response might have suggested some frontal lobe involvement. By age 41, it was evident that a focal process was slowly evolving with some involvement of parasagittal motor cortex. Again the psychomotor retardation and the deficit in digit span at a time that delayed recall was normal (possibly consistent with an impairment of working memory) might have suggested some degree of. prefrontal involvement. Certainly, by the time of surgical intervention, 11 years after onset of symptoms, the pace of progression had accelerated. This might have indicated some alteration in the basic biological activity of the tumor.

Finally a note about diagnostic techniques . This patient was initially seen in 1956 and hospitalized in late 1967. At the time CT scan and MRI were not yet available. Today, an adult with onset of seizures at age 30 would have undergone an MRI or at least a CT scan with contrast. The diagnosis would have been made much earlier in time but the eventual treatment and results of treatment would probably not differ significantly from those obtained in 1967. The role of radiotherapy in low grade gliomas remains controversial. There is a role once transformation to a higher grade of malignancy has occurred.

MALIGNANT GLIOMAS

The following case demonstrates the apparent acute (possibly stroke like) onset and rapid progression of a very malignant glioblastoma multiforme.

Case 27-4 (patient of Dr. Tom Mullins): This 68 year old right handed white male was admitted to St Vincent Hospital with an apparent 4 to 5 day history of difficulty in doing calculations and in speaking, “he could think of the word ,but had difficulty getting it out”.

Neurological examination :

1. *Mental status and language function*: Speech was limited to short phrases with loss of connectors and sentence structure. Writing was impaired but, repetition, comprehension, naming and reading were intact.
2. *Cranial nerves*: Intact.
3. *Motor system*: Strength and gait were intact .However fine motor movements of the right hand were impaired .
4. *Reflexes*: Tone was increased on the right. The right patellar reflex was increased. Bilateral Babinski signs were present.
5. *Sensory system*: Intact.

Clinical diagnosis: Diagnosis was uncertain .The abrupt onset suggested a possible vascular event such as an embolus in the middle cerebral artery territory but the overall pattern including bilateral Babinski signs without significant hemiparesis was unusual. Thus other possibilities had to be considered including focal herpes simplex encephalitis, tumor or a small lobar hemorrhage.

Laboratory data :

1. EEG : Focal left hemisphere delta and theta slow wave activity was present.
2. CT scan(Fig.27-7):A. The non enhanced study demonstrated a low density mass in the mass in the left frontal-parietal parasagittal region with areas of hemorrhage. B. The contrast enhanced study demonstrated an irregular rim of enhancement.
3. Angiogram indicated an avascular mass in the left frontal-parietal area.

Subsequent course: Dr. Alex Danylevich performed a subtotal resection of this tumor which was found to contain blood clot and cystic fluid. The histology of the tumor was glioblastoma multiforme (Fig.27-5). The patient subsequently received 4000cGy whole brain radiation and an additional 2000cGy to the tumor site. Three months following surgery ,the patient developed increasing obtundation. CT scan revealed a large left frontal necrotic mass. Fever, hypocalcemia and hypernatremia developed and he expired one month later.

Comment: This patient presented with what appeared to be an abrupt onset of language problems raising the question of a cerebrovascular accident. In retrospect , it was evident on the CT scan and at surgery that the acute onset reflected the hemorrhage and necrosis which had occurred within the tumor. This was a rapidly growing ,extremely malignant tumor which apparently had outstripped its blood supply despite the neovascularity.

III INFECTIONS

FOCAL

Subdural empyema

The following case provides an example of subdural empyema complicating frontal sinusitis.

Case 27-5. This forty-eight year old, right-handed, white male was referred for evaluation because of headaches and papilledema. For 3 weeks prior to admission, the patient had severe bifrontal headaches which were constantly present and interfered with sleep. One week prior to admission, the patient developed a fever of 105° with a white blood count (WBC) of 25,000. X-rays indicated "sinusitis". The patient was hospitalized at his local community hospital. Confusion soon developed. Three days prior to transfer to a neurologic unit, the patient had a series of seizures characterized by turning of the head and eyes to the left. Lumbar puncture had indicated clear cerebrospinal fluid with pressure of 300 mm. and protein increased to 65 mg./100 ml. The patient had chronic right nasal discharge for ten years. Eight weeks prior to admission, the patient, while stooping down, struck his right frontal areas but was not - unconscious. A right periorbital ecchymoses developed, and the patient also had the onset of bilateral frontal headaches.

General physical examination: Temperature was elevated to 101°. There was right periorbital edema. Excoriation of right nasal mucosa was present.

Neurological examination:

1. *Mental status:* The patient was alert but irritable and slightly confused. He was poorly attentive and failed to persist in carrying out motor activities. He was oriented grossly for time, place and person. Calculations were poorly performed. Delayed recall was defective.
2. *Cranial Nerves:* All were intact with the exception of the fundi. Low-grade papilledema was present and venous pulsations were absent.
3. *Motor System:* Strength was intact, but there was a slight drift downward of the outstretched left arm.
4. *Reflexes:* Deep tendon reflexes were somewhat brisker at left arm and leg (3+) as compared to the right (2+). Plantar responses were flexor. A bilateral grasp reflex was present.
5. *Sensory system:* Intact
6. *Skull & Neck:* There were slight tenderness over the right periorbital area. Minimal nuchal rigidity (resistance to passive flexion of the neck) was present.

Clinical diagnosis: Right frontal subdural empyema or brain abscess.

Laboratory data:

1. The *WBC* was increased to 14,350 cells per cubic mm., and the sedimentation rate was increased to 110 mm. in one hour.
2. *Sinus X-rays:* Bilateral maxillary and frontal sinusitis was present with resorption of bone.
3. *Electroencephalogram:* Focal 4 to 7 cps slows wave activity was present in the right parietal area suggesting focal damage. Moreover, focal voltage suppression (reduction of voltage) was present in the right anterior frontal area suggesting a possible subdural collection.
4. *Right carotid arteriogram* showed an apparent slight shift of the anterior cerebral vessels to the left suggesting a right hemisphere space-occupying lesion.

Hospital Course: Following these studies a right frontal trephine (burr) hole was placed by Dr. Robert Yuan. When the dura was incised, 5 cc. of yellow purulent material escaped from the subdural space and additional purulent drainage was aspirated. Additional burr holes were placed in the right occipital area where a few drops of subdural pus were encountered. No pus was obtained from the left subdural area. Subsequent cultures demonstrated *Staphylococcus aureus* as the responsible organism. The dura and cortex otherwise appeared unremarkable although cerebral edema was present. The patient was subsequently treated with appropriate antibiotics. His temperature gradually subsided to normal and his mental

status cleared. Three weeks later, a bilateral frontal sinusotomy was performed by Dr. Thomas Klein with drainage of the sinus. Histological examination of a section of sinus mucosa removed demonstrated intense chronic inflammation. The patient continued to improve. When seen in followup examination four months after admission, papilledema had subsided, no neurological findings were present except for a slight reflex asymmetry (slightly increased on the left).

Comment: This patient presented a definite history of chronic nasal sinus infection with a recent exacerbation. The role of trauma in the exacerbation is uncertain. It is clear, however, that the sinusitis had produced involvement of the adjacent bone with subsequent spread to the adjacent frontal subdural space. The severe headache experienced by the patient reflected not only the process of infection involving the sinus and meninges but presumably also the increase in intracranial pressure. The early involvement of the right frontal area was suggested by the initial symptoms of confusion and by the occurrence of focal seizures characterized by turning of the head and eyes to the left. The findings of the electroencephalogram suggested a subdural collection of fluid or pus in the right frontal area.

These clinical and laboratory impressions were confirmed by the subsequent surgical observations. In the present case the arteriogram suggested only a non-specific space-occupying lesion in the right frontal area. The more specific finding in these cases would involve the displacement of distal branches of the anterior and middle cerebral artery from the inner table of the skull as in a subdural hematoma. Today the CT scan or the MRI/MRA is the study of choice for confirming the diagnosis of a subdural collection. Additional review of subdural empyemas will be found in Miller et al 1987. In the pre-antibiotic era, infections involving the nasal sinuses could produce thrombophlebitis of the cortical veins and superior sagittal sinus. With that complication, infarction of that area of motor cortex representing the leg could occur resulting in unilateral or bilateral leg weakness as well as focal motor seizures. Infection of the nose or face or of the ethmoid or sphenoid sinuses could produce thrombophlebitis of the cavernous sinus resulting in the syndrome discussed in the cranial nerve chapter: unilateral or bilateral involvement of the cranial nerves found in the lateral wall of the cavernous sinus (III, IV, VI and the ophthalmic division of V). The ophthalmic vein may be obstructed producing edema of the eyelid and face. Obstruction of the retinal vein produces papilledema. Infection of the middle ear or mastoid may produce involvement of the transverse or lateral sinus. If this extends to the jugular vein, increased intracranial pressure may also occur. However increased intracranial pressure may follow any involvement of the other venous sinuses. At the present time, dural venous sinus thrombosis is usually more indicative of dehydration and other systemic conditions in the infant and in the adult of immunological disorders or of conditions that produce a state of hypercoagulation such as polycythemia, carcinoma, pregnancy or birth control drugs. (refer to Daif et al, 1995 and DeVeber et al, 2001)

CHAPTER 30 MEMORY

A case of Wernicke-Korsakoff syndrome is presented in case 30-1.

Case 30-1. Patient of Doctor John Sullivan and Doctor John Hills): This 62-year-old, white, right-handed stonecutter had been a known heavy alcoholic spree drinker for many years. The patient would drink large quantities of wine for 6 to 8 weeks at a time. Two years previously, the patient had been admitted to the Boston City Hospital because of delirium tremens (tremor and visual hallucinations). Two months prior to admission shortly following the death of a brother-in-law, the patient began his most recent drinking spree. He unaccountably found himself in Florida, not knowing where he was and

why he was there. Apparently, he had drifted aimlessly for 5 weeks with no definite food intake for a month. The patient was brought back by his family and hospitalized at his local community hospital with diplopia, ataxia and marked impairment of memory. The patient had complaints of numbness of his fingertips and unsteadiness of gait. The patient after beginning treatment was shortly thereafter referred to the Neurology Service at the New England Medical Center.

General physical examination: No abnormalities were present except for an enlarged liver with the edge palpated approximately 2-1/2 finger breadths below the costal margin.

Neurological examination:

1. Mental status:

- a. The patient was markedly disoriented for time and place. At times, the patient thought that he was in New Jersey; at other times, he stated correctly that he was in Boston.
- b. The patient, with suggestion, would recall his apparent travels that day to various other locations within and outside Boston (he was actually in the hospital). Confabulation was also evident when it was suggested that he had recently seen various fictitious persons.
- c. Remote memory; The patient was unable to state his age. The patient was able to provide his birth date correctly. He could not give his address or telephone number. When quizzed as to the President of the United States, he selected on multiple choices the previous president. At times, the patient often indicated to visitors that his mother and father were still alive, though both parents had been dead for over 20 years.
- d. Insight; He appeared to have little insight for his disorientation in time. He had no insight as to his condition or for the reason for his hospitalization.
- e. The patient's digit span was normal at 7 forward and 6 in reverse.
- f. The patient could name various objects correctly when these were presented to him and yet he was unable to retain any memory of which objects had been presented to him five minutes previously. He was unable to retain any information concerning a story that he had been requested to learn.
- g. The patient was able to do 2 and 3 figure additions and multiplications without difficulty. He was able to do the initial subtractions in the serial 7 test but then lost track of the number to be subtracted.
- h. The patient was able to read and to write without difficulty. He showed no constructional apraxia and no left-right confusion.

2. *Cranial nerves:* There was horizontal diplopia on right lateral gaze. The minor degree of separation of images, however, did not allow precise identification of the muscle involved. A minor weakness of the right lateral rectus was suspected.⁶ Horizontal nystagmus was present on lateral gaze, bilaterally and vertical nystagmus on vertical gaze.

3. *Motor system:* Strength was intact except for a minor degree of weakness in the distal portions of the lower extremities evident on ankle dorsiflexion and toe dorsiflexion.

The patient walked on a narrow base with eyes open and showed no evidence of an ataxia of gait. On a narrow base with eyes closed, the patient had a positive Romberg test.

No cerebellar findings were present.

4. *Reflexes:* Deep tendon reflexes were normal at triceps and biceps, decreased at radial periosteal. And absent at patellar and Achilles even with reinforcement.

⁶ The minor nature of the diplopia undoubtedly reflected the improved nutritional status that had occurred during the previous 5 days of hospitalization at his community hospital. We presume that if the patient had been examined prior to hospitalization, more marked lateral rectus palsy probably would have been delineated.

Plantar responses were flexor bilaterally.

No grasp reflex was present.

5. Sensory System: Pain and touch were decreased in the lower extremities below the mid calf. Vibratory sensation was absent at the toes and decreased over the tibia to a marked degree and to a lesser degree over the knees. There was to a lesser extent, a decrease in the upper extremities at the fingertips and wrists.

Position sense was decreased at fingers and toes.

Clinical diagnosis: Wernicke' encephalopathy plus nutritional poly neuropathy

Laboratory data: Complete blood count, liver functions and renal functions, CSF, EEG, and X-rays of the skull and chest were all normal.

Subsequent course: The patient was treated with thiamine, 50 MGS daily. There was a significant improvement in extraocular functions. The patient had no diplopia after the day of admission. There was no significant change in his mental condition or peripheral neuropathy. Evaluation 3 months later, indicated persistent disorientation for time and place and severe selective deficits in memory (delayed recall was still grossly defective).

Comment: This patient presents a relatively typical history of the Wernicke-Korsakoff syndrome. He had been a heavy alcoholic spree drinker. The major symptomatology that was apparent to the patient's family and to his physician, related to his marked confusion, severe impairment of memory and confabulation. The patient himself had no significant complaints and little insight into his disease. In some cases, the severe memory disturbances may be present without any definite evidence of confabulation. Not only the retentive memory for new material was impaired but also the patient's distant memory was also significantly impaired. In such cases with severe impairment of memory the prognosis for a complete recovery of mental status is very poor. The diplopia and nystagmus, as expected, resolved significantly with treatment with thiamine. The ataxia of gait, which had been present early in the case, had apparently resolved by the time of transfer from his local hospital. A significant peripheral neuropathy, mainly distal sensory, was present related to multiple B vitamin nutritional deficiency.

In many cases, the state of confusion in Wernicke's encephalopathy is preceded by or accompanied by a period of delirium tremens indicating alcohol withdrawal. The use of intravenous glucose feedings without supplemental intravenous thiamine during such a withdrawal state may actually increase the requirements for thiamine, thus exacerbating the thiamine deficiency state. For this reason, all patients under treatment for alcohol withdrawal (or admitted to the hospital with a recent past history of alcoholism) should be treated with high dosage vitamin therapy as well, on the presumption that they are candidates for nutritional deficiency.

A case of transient global amnesia is presented in case 30-2 below.

Case 30-2: This 55-year-old, right-handed, white male, college professor, awoke at 3:00 a.m. on the morning of admission in an uneasy and restless state. He asked his wife what day it was but then did not recall what she had told him. He did not know the month, kept repeating himself and asking the same questions. His wife arranged for him to be seen early in the morning by his family physician who lived a short distance away. The patient, who was familiar with the route, was unable to find his way there. When he arrived at the doctor's office, he was unable to explain why he had come. The patient apparently had forgotten about the incidents, which had occurred earlier that morning. He had no recollection that he had a grandchild born three weeks before. He could remember no significant events from this 3-week period prior to the onset of his illness. The patient's more remote recall and other intellectual capacities remained intact. The patient drove into Boston later that day but became lost despite the usually familiar route.

The patient had a past history of gout with an elevated serum uric acid level.

Neurological examination: Findings were essentially limited to the mental status examination.

When examined in the early afternoon, the patient was beginning to regain some of his ability to retain new information. The patient was generally oriented to person and place. However, he was disoriented for the day and month but was oriented for the year. The patient's store of information was quite intact suggesting a highly intelligent person.

The patient had marked difficulty with delayed recall. He could recall none of the 4 objects after 5 minutes. He could not remember any of the three test phrases given to him when asked about these 5

minutes later. He did recall in a vague manner that a memory test had been given him. As regards recent memory, the patient was unable to remember his visit to his family physician earlier in the day. Digit retention, however, was relatively well preserved; 6 forward and 5 backward. The patient had no defects in calculation. There was no evidence of a constructional apraxia. Language function was entirely intact.

Clinical diagnosis: Probable transient global amnesia

Laboratory data:

1. Complete blood count, serology, blood urea nitrogen, total cholesterol, uric acid skull and chest X-rays, EEG and complete CSF were all within normal limits.
2. The *brain scan* demonstrated a small area of increased uptake of radioisotope (Hg197) in the left temporal region.

Subsequent course: Over the several hours following admission, the patient gradually regained his ability to retain new information and to recall the events of the preceding 3 weeks, the more remote events being recalled first. The memory for the events of the day prior to admission was regained last. This pattern is referred to as a shrinking retrograde amnesia. The specific events that occurred on the morning of admission were never recalled. The following morning delayed recall was four-out-of-four objects after 8 minutes. The patient's mental status and neurological examination were otherwise within normal limits. A repeat brain scan, 3 months after the episode demonstrated considerable improvement, and all brain scan findings had resolved at 5 months. No additional episodes occurred during the one-year after the acute episode.

Comment: The patient's main deficit was in learning new information (anterograde amnesia) with the old stored long-term memory information still intact. During the episode there was a retrograde amnesia that initially extended back for three weeks. As recovery occurred, this retrograde amnesia disappeared. These relatively recent past memories were intact but transiently not accessible. The labile stage of long-term memory has been estimated to be a matter of 20-180 minutes. This case suggests that there is not a sharp border between the labile more recent stage and the remote stage of long-term memory or perhaps of the ability to access those memories. The patient could not remember what happened during the episode. That is suggestive of mesial temporal lobe involvement, in this case left hippocampal region in dominant hemisphere. The ability to perform calculations and language functions was otherwise intact. This would suggest that lateral temporal areas were not involved. The electroencephalogram was normal and consistent with such a lack of involvement of the lateral aspects of the cerebral hemispheres. Occasionally, the EEG will demonstrate a minor focal involvement of the temporal lobe. More often, as in this case, the study is normal. CT scan and MRI when performed are usually unremarkable. SPECT scan might well indicate transient focal involvement as indicated above. The brain scan in this case did suggest a transient abnormality, which would be consistent with an area of ischemia/ infarction, which resolved over the succeeding months. Such an episode must be distinguished from episodes of amnesia, which may occur in relation to, and following a temporal lobe seizure.

The effects produced by electrical stimulation of the hippocampus may also occur as relatively selective ictal and postictal phenomena in a complex partial seizure originating in mesial temporal lobe structures as illustrated in case history 30-3 which follows. Focal temporal lobe seizure phenomena were followed by a period of impaired recent memory with an inability to record new memories.

Case 30-3: This 68-year-old, white male one year prior to valuation fell, striking his occiput and transiently losing consciousness. Except for a persistent defect in his sense of smell, the patient had no apparent neurological defects following this injury. Approximately six months later, the patient had the first of a series of recurrent episodes of amnesia. These episodes occurred most often on awakening. On some, but not all, occasions the episodes were preceded by a sensation of gastric upset, a strange odor and a sensation of familiarity (*déjà vu*). The episodes of total amnesia would last 30 to 60

minutes. There would then be an impairment of memory for approximately one to two days. The patient was said during the episode of total amnesia and during the subsequent episode, to behave in an otherwise normal and rational manner. For example, he would be able to converse with his wife and others. During the episodes, he was said to be unable to remember tasks, which his wife had asked him to do during that day. A significant impairment of retentive memory would be apparent to his wife and to others. His memory for more distant and remote events was also impaired to a variable but lesser degree. The patient would then regain memory progressively over the course of the next one to two days. Apparently, memory was not regained in any orderly pattern from recent to remote or vice versa. The patient at no time had any abnormal movements suggestive of a generalized convulsion.

No automatisms had been noted and to others the patient would appear fully conscious during the episodes.

Neurological examination:

1. *Mental Status*: The patient was oriented for time, place, and person. Delayed recall was intact. The patient could remember 4-out-of-5 objects in 5 minutes. Remote memory was intact. Digit span was slightly impaired at 6 numbers forward and 4 in reverse.

2. *Cranial Nerves*: All areas were intact with the exception of cranial nerve I where olfaction was decreased for the odor of coffee grounds, bilaterally.

3. *Motor system, reflexes and sensory system*: *Intact*.

Clinical diagnosis: 1) Complex partial seizures (most likely post traumatic) with episodes of amnesia as an ictal and or post ictal phenomena. 2) Post traumatic anosmia.

Laboratory data: 1. *Skull X-rays, routine EEG, radioactive brain scan, fasting blood sugar and glucose tolerance tests, pneumoencephalogram and spinal fluid examination were normal..*

2. The EEG obtained after a period of sleep deprivation revealed occasional multifocal spikes during sleep in the right anterior temporal area and to a lesser degree the left frontal-anterior temporal area.

Subsequent course: The patient was treated with anticonvulsant medication. The episodes continued to occur once per month but were now of shorter duration, lasting only 15 to 20 minutes. The impairment of memory was less marked and involved only the ability to learn new material without prolonged periods of retrograde amnesia. After 8 months no additional episodes occurred. When seen three years after initial evaluation his neurological examination was unremarkable except for the defect in olfaction suggesting that more serious progressive disorder was not present.

Comment: In this case the episodes experienced by the patient could have posed a diagnostic problem if the occasional warning symptoms of olfactory aura, déjà vu and epigastric sensation had not been present. Most of the episodes experienced by the patient were not preceded by these clear symptoms of temporal lobe seizure, but were instead simply episodes of amnesia. Though the actual temporal lobe seizures apparently lasted only a matter of 30 to 60 minutes, some degree of impairment of memory was present for one to two days following the episode.

The etiology of the seizures in this case must relate to the patient's preceding head trauma. The loss of olfactory sensation following the trauma suggested that this trauma was of sufficient nature to tear the nerve filaments passing through the cribriform plate to the olfactory bulb on the orbital surface of the frontal lobe. Such trauma does produce contusions of the orbital frontal cortex and epileptogenic foci may result. We may also assume that this trauma may have been sufficient to produce some minor contusion of the anterior poles, inferior and medial surfaces of the temporal lobes against the bony walls of the middle fossa with a resultant scar and epileptogenic focus. The fact that olfactory hallucinations and the experience of déjà vu preceded some of the amnesic episodes

would make the temporal origin more likely. The routine electroencephalogram is not reliable in the detection of seizure discharges in either the mesial temporal or the orbital frontal areas. The electroencephalogram showed significant areas of discharge in the temporal lobe only under conditions of sleep deprivation which acts to precipitate seizure discharges in individuals who have an underlying predisposition for seizure discharges. For additional discussion, see Gallassie, et al (1988), Hughlings-Jackson (1889), Tassinari, et al (1991).

The following case history presents an example of presenile dementia.

Case 30-4: This 64 year old right handed white male formerly an administrative assistant for the veteran's administration and newspaper distributor was initially evaluated for impairment of recent memory. Initially, the wife indicated this had been progressive over 4 years, but she was subsequently able to date this back to age 54 years, 10 years previously. A review of his record indicated that another neurologist of our department had seen him 4 years previously with similar memory complaints. The neurological examination at that time demonstrated no focal features, but his mental status examination indicated an inability to recall any of four objects. There were minor changes in time orientation: his date was off by one month and the day of the week was incorrectly stated. In the interim, the memory problems had progressed. In addition there were now personality changes. He no longer participated in those activities which had previously been of great interest. He was also having some problems in finding words. There were no problems in the activities of daily living and he was not getting lost in his familiar environments.

Family history: There was no history of neurological disease in his siblings or father. His mother had died at the relatively young age of 48 of cancer.

Neurological examination:

1. *Mental status:* The mini mental status exam indicated a total score of 19 out of 30. He had particular problems in time orientation. He was able to do the immediate recitation of three objects and of a test phrase but could remember none of these on a delayed recall test. He also had difficulty copying a test figure. The patient was often tangential in his answers and demonstrated inappropriate joking.

2. *Cranial nerves:* intact

3. *Motor system* was intact as regards strength, gait and cerebellar functions. However premotor /frontal lobe functions were abnormal. He had a release of the instinctive grasp reflex. He had difficulties performing the Luria three stage motor sequences demonstrated by the examiner (slap thigh with palmar surface, then with ulnar edge of hand and then with ulnar surface of closed fist.).

4. *Reflexes:* deep tendon stretch reflexes, and plantar responses were physiologic.

5. *Sensory system:* intact

Clinical diagnosis: Alzheimer's disease

Laboratory data:

1. All screening studies such as *complete blood count, sedimentation rate, B -12, folate, thyroid functions and serological test for syphilis* were normal.

2. *CT scan* demonstrated significant dilatation of the temporal horns. (This change in the size of the temporal horns suggested hippocampal atrophy.) In addition there was a general increase in lateral ventricular size. There was also blunting of the angles of the frontal horns.

3. *SPECT scan* was within normal limits except for a slight decrease in perfusion in the left parietal region.

Subsequent course: The patient was begun on treatment with 5mg per day of donepezil (Aricept) a centrally acting acetylcholinesterase inhibitor and high dosage of vitamin E (a possible antioxidant). . When re-evaluated at one month, his family reported improvement in memory; the mini mental status exam score was now 21 out of 30. At 10 weeks into treatment, the score had increased to 25 out of 30. There was particular improvement in the delayed recall section of the exam. There was however no change in personality. He still showed inappropriate jocularity when he could not answer a question and at times was tangential in his answers. Administration of the acetylcholinesterase inhibitor temporarily improved memory function for approximately 18 months. However by age 67, behavioral disturbance (agitation, aggression nocturnal wandering and sexual disinhibition) and urinary incontinence were becoming major problems. He could no longer be managed in his home and day care setting despite the

use of haloperidol. This resulted in his placement in a nursing home. At age 69, he was now described as relatively nonfluent, and very confused. He recognized his own name and occasionally recognized relatives but showed no other response to questions. He was usually restricted to a wheel chair, could walk with assistance. He was “stiff and afraid” when requested to walk.

Comment: This patient presents a typical example of the slowly progressive course of Alzheimer’s disease. Memory problems had begun insidiously at approximately age 54. Initially these problems in the older adult may be attributed to a benign age related process in which there is minor difficulty in accessing information such as names although the ability to incorporate new information is still intact (“wait a minute, the name or word will come to me eventually”). When evaluated by a neurologist at age 60, the major finding was a severe deficit in delayed recall suggesting a process at the level of the hippocampus. The patient failed to return for follow up at that time and when he did reappear at age 64, he was now beginning to show changes in personality and frontal release signs suggesting involvement of the prefrontal and premotor areas. The use of a cholinesterase inhibitor produced some improvement in memory for about 18 months but had little effect on the changes in personality and behavior. The use of this agent has been estimated to postpone nursing home placement by approximately 15 months. Eventually by age 69, fifteen years after disease onset, gait and other motor functions were seriously affected.

The rationale for the use of cholinesterase inhibitors is based on the demonstration by Drachman and Leavitt (1974) that administration of scopolamine, an anticholinergic drug that crosses the blood brain barrier, would produce a transient syndrome similar in many respects to memory and cognitive changes of Alzheimer’s disease. Subsequent studies demonstrated a marked loss of neurons in the basal forebrain nucleus of Meynert, a major source of cholinergic fibers to the cerebral cortex. (Whitehouse et al 1981 Rogers et al, 1985 editorial of Growden 1992). However, a simplistic cholinergic hypothesis is insufficient to explain all of the features of Alzheimer’s disease. Administration of acetylcholine esterase inhibitors in mild cases (mini mental status score of 10-25) has only a limited value as in the present case. Other neuronal systems are involved (noradrenergic synapses are also involved. hippocampal system is severely involved).

The following case 30-5 provides an example of general paresis producing severe changes in cognitive function and personality.

Case 30-5 : This 59-year-old right-handed white male, cleaning establishment owner, five years prior to evaluation, manifested a personality change - increased rigidity and irritability. He would become enraged over trivial matters many times per day. During the last 1.5 years, this process accelerated. He became more antisocial, unable to interact with employees and customers. His level of comprehension declined. He became more aggressive towards his wife and children. He often manifested frank paranoia and suspiciousness, accusing his wife of unreal, sexual infidelity. During the last 1.5 years, a significant gait disturbance had also developed, with impairment of balance. A slowing in speech and a tremor of hands had developed over the previous year.

The patient had been born in Poland. All significant infections were denied. He had received injections of “liver” and B12 after the war “for anemia” but had received no recent B12 injections.

Neurological examination:

1. *Mental status:* The patient was oriented for time, place and person.

Delayed recall was markedly impaired none of five in five minutes without assistance, one of five with assistance. Repetitions and naming of objects were intact. Distant (remote) memory was good. The patient could list all major world leaders during World War II and all assassination attempts.

The patient was often tangential in his responses and often initiated irrelevant conversations.

Serial 7 subtractions could not be done but the patient could reverse 12 months of the year.

Abstract reasoning for similarities was poor.

He often got up from the bed and looked outside the curtain, checking the activities of his roommate.

2. *Cranial nerves:* Pupils were small, 2 mm., and irregular but did respond to light.

Twitching and grimacing of face, eyelids and tongue occurred. He also had a lid lag.

3. *Motor system*: Strength was intact. Gait was wide-based, with a positive Romberg test. The patient was quite tremulous with occasional myoclonic jerks. He could not do rapid alternating movements.

4. *Reflexes*: Deep tendon reflexes were normal (2+) in the upper extremities, trace at patellar and absent at Achilles. Plantar responses were flexor, bilaterally. There was no release of the grasp reflex. Other frontal release signs were absent.

5. *Sensory system*: Pain, touch and position sense intact. Vibration was markedly decreased at toes, and ankle with minor preservation at knees.

Clinical diagnosis: Progressive dementia and personality change. Multiple entities to be considered including (1) the combination general paresis and tabes dorsalis, (2) B12 deficiency, (3) frontal lobe tumor, (4) frontal dementia and (5) Lewy body dementia

Laboratory data: The abnormal findings included:

1. *Vitamin B12 level* was borderline low at 209 picograms/ml., *Schilling test*, however, demonstrated normal absorption (25.4% excretion of radioactive B12 in urine).

2. Serum serological test for syphilis (RPR) was reactive with the more specific FTA markedly reactive.

3. *Cerebrospinal fluid*: 98 white cells were present - all lymphocytes. CSF protein was elevated to 116 mgs.% (normal <45 mgs.%). Sugar was low at 44 mgs.% with a simultaneous blood sugar of 90. Spinal fluid serological test for syphilis (VDRL) was positive.

4. *CT scan* showed mild frontal and temporal atrophy

Subsequent course: The patient was hospitalized for two weeks and received high dosage intravenous penicillin therapy, three million units every four hours for 10 days (18 million units per day).

When seen again 2 months later, the patient and his family reported that gait and coordination had significantly improved. Memory and personality had not improved. He still had episodes of agitation and irritability. Reflex and sensory findings were unchanged. The patient had been inconsistent in taking any medication such as haloperidol, aimed at altering his agitation.

He failed to return again for 18 months. Paranoid ideation had become more prominent. He could no longer manage his fiscal affairs. Orientation and delayed recall were intact. There was minor tremor of the hands and an unsteadiness of gait. Romberg was positive although position and vibratory sensation were intact. Serum serology was now negative. Lumbar puncture now indicated no significant cells, a normal protein.

Subsequently he did require hospitalization for renal failure secondary to enlarged prostate and a neurogenic bladder. Spinal fluid VDRL and serum RPR serological tests for syphilis, were both nonreactive. Serum FTA ABS - a much more specific and more sensitive test for previous syphilis was still 3+ reactive.

Telephone follow-up 11 years after the initial episode indicated that personality and cognitive changes had essentially leveled off, irritability and hostility were less. He had no urinary problems. He was unsteady in walking, but was still able to drive small distances and was living at home. Additional information approximately 20 years after the initial evaluation indicated that he spoke very little, he no longer demonstrated agitation. His mobility was more limited. Of interest, one pupil no longer responded to light but did respond to accommodation. CT scan demonstrated greater atrophy.

Comment: This patient had clinical manifestations predominantly related to general paresis. Both the history and the examination also provided evidence of tabes dorsalis. Penicillin therapy resulted in a non-active state, as regards serum serology and any cellular activity in the spinal fluid. However, the damage to cerebral cortex was not reversed and continued to provide a significant problem, as regards personality function. Thus, once cognitive function has been altered, due to damage to and loss of neurons, the changes in memory and personality may be persistent. Disturbances of frontal lobe and limbic system function once initiated may continue to evolve.

Moreover once the patient reaches the late 60's and the 70's, apparent progression of neurological changes in memory and other cognitive functions may occur related to the combined effects of the previous acquired lesions of general paresis and the effects of even mild Alzheimer's disease. A double hit has occurred.

The following case provides an example of a patient whose initial symptoms related primarily to a severe alteration in personality function and social interactions. Features of Parkinson's disease were apparent on her examination. Diagnosis was uncertain but diffuse Lewy body dementia should be considered.

Case 30-6: This 60-year old, right handed separated white housewife, residing in a nursing home, was referred for evaluation of problems in walking, progressive behavioral change and memory disturbance. Six years previously at age 54, a change in behavior was first noted by her family. She began to accumulate papers about the house. She would leave the shades down all day, and expressed fears that people would break into her house. As a result, she became isolated from her neighbors and friends. Shortly there after, she made repeated phone calls to the local police and it was apparent that she was confused. After investigation, the police had to break into the house and take her to an emergency room. In the emergency room she was described as confused and frightened. Paranoid ideation was prominent with considerable self-referral ideation. Thought process was described as tangential, with considerable perseveration. There was poor insight and judgment was impaired. She was confused as to time and place and she could recall two of three objects in 5 minutes. She had great difficulty with serial sevens, often losing track of the number to be subtracted. Judgment and insight were poor. She would read a book by rapidly turning the pages, but then had little recall of what she had read. With treatment with haloperidol, lability of mood and paranoia decreased. A CT Scan demonstrated "mild cortical atrophy". The patient was then transferred to a nursing home with a diagnosis of Alzheimer's Disease. In retrospect, a gait problem had also been present in January 1984, about the time that her symptoms had begun, and prior to the use of haloperidol.. The patient was walking flexed with small steps. These gait problems progressed so that she was unable to stand up from a chair and was unable to walk. She had become fearful of walking.

Family History - Indicated parents died at ages 70-80 years, without neurological disease. A sibling was age 79 without neurological disease.

Neurological examination:

1.*General:* A thin female appearing older than her stated age. She sat in a wheelchair with little facial expression and with little body movement. She was passive in the interview situation -allowing her husband to provide many answers.

2.*Mental Status:* She was oriented to the year but when requested to provide the month and day, she answered "it is the beginning of school time". As regards the location, she gave the name of the town where she formerly lived but could not name the town where the nursing home was located. She did name the nursing home and then said "its a jazzy place with more facilities, most of the people there are nice, some just sit around".

Asked to describe herself, she said, "I am nothing, I can't even take care of my child". She was, however, able to provide the name of her only daughter, now grown, and was able to indicate that the daughter had been born in 1945 in Philadelphia (all of which the husband verified as correct).

Asked to indicate her own birthplace and birth date, she indicated she herself had been born at home in Fitchburg in 1925 and then added, "I imagine everything has been tossed out there". When I asked "what had been tossed out?", she provided a tangential answer, "I do not know you" and then rambled on to a conversation topic about her husband's trip to Turkey on a "Fulbright" - some time in 1960 or 1970.

Delayed recall even with multiple choice assistance was zero out of five in five minutes. For serial seven subtractions, 100 - 7 "might equal 86 or might equal 55". She could name 3 out of 5 objects, could do repetitions, could write her name but not her address and refused to draw a house (? unwilling, ? unable).

3. *Cranial Nerves:* Intact except for a tremor of the closed eyelids and a positive glabellar sign. There was a lack of facial expression.

4. *Motor System*: Strength was difficult to assess, but appeared intact when maximal effort was made. Significant akinesia and bradykinesia were present. There was cogwheel rigidity of minor degree at wrist and elbow. There was variable resistance at hip and knee, which had primarily the character of frontal lobe type "Gegenhalten".
The patient had to be assisted to the standing position from her wheelchair. In the standing position, initially, her feet appeared to be stuck to the floor, as in a magnetic foot syndrome. Eventually, she was able to take small shuffling steps, as assistance was provided by holding her outstretched hands lightly. If unsupported, she tended to fall backwards - whether standing or walking.
 5. *Reflexes*: Deep tendon reflexes were physiologic at 2+ except for Achilles - 1+. Plantar responses were equivocal. There was marked release of the grasp reflex.
 5. *Sensory system*: Pain and vibration were intact. Position sense could not be tested.
- Clinical diagnosis:** Lewy body dementia , or a variant of frontal dementia.

Laboratory data:

1. *Metabolic surveys* were not remarkable in terms of electrolytes, BUN, creatinine, glucose, hepatic functions, vitamin B12, folate levels and thyroid functions.
2. Routine serum serological test and FTA absorption for syphilis were negative.
3. *Sedimentation rate* was moderately increased to 53 mm/hr. *Alkaline phosphatase* was elevated to 272 and bone scan suggested possible Paget's Disease.
4. *EEG* demonstrated a slow dominant awake activity of 6-7 Hz (compared to normal alpha rhythm of 8-13 Hz). In addition, rhythmic bilateral delta slow wave were present, most prominent in the frontal recording areas.
5. *CT Scan*, demonstrated marked cortical atrophy with enlargement of sulci, ventricular system and cisternal spaces.

Subsequent course:

The patient continue a slowly progressive course to the present time. According to her primary physician, she is essentially restricted to bed. She remains, from a medical standpoint, relatively clear of other medical problems and complications - at age 67, 13 years after onset of the disease.

Comment: The diagnosis in this case is uncertain . The patient at age 54 had the onset of a significant change in behavior which resulted in major problems in interpersonal relationships. Initially, she had been able to live by herself in her small seaside community. Eventually, however, the frequent night calls to friend, neighbors, and the police, resulted in her coming to medical attention. Even at that point, the patient's separated husband, who visited her frequently and supported her, appeared unaware of the patient's confusion and memory deficit. The husband had considerable difficulty appreciating the degree of disability. Such a pattern is not unusual.

In contrast to the previous case histories of this chapter, the memory problems were far beyond the selective involvement of recent memory seen in Wernicke's or hippocampal lesions. Moreover, a more diffuse involvement of other cognitive functions was present. As the disease progresses, motor aspects become prominent, indicating the effects of involvement of frontal and premotor areas. Mild "Parkinsonian" features may appear, due to either the medications employed (neuroleptic agents such as pheno thiazides, haloperidol, etc.) or to alterations in the frontal premotor basal, nuclei circuits or to loss of neurons, at the level of S. nigra or basal nuclei. Note however that the gait problems occurred prior to the use of haloperidol. The CT scan did not demonstrate the focal atrophy seen in frontotemporal dementia .Therefore the most likely diagnosis might be diffuse Lewy body dementia since personality changes were most prominent at onset, and Parkinsonian features developed early in the disease course. Contrast this case to the Alzheimer disease patient of case 30-4 in which the initial problems were restricted to changes in memory.

When seen at age 60 this patient was clearly late in her disease course. As indicated, remedial causes of the syndrome of progressive dementia must be ruled out. The effects of medication must be considered. Moreover, however, any masking depression should be treated. At this point in time, no specific therapy to reverse the progressive course of the disease is known.

Case 30-7: This 74-year-old right-handed widow presented to the emergency room at St Vincent hospital on 2-19-02 with an 8-10 week history of worsening memory problems. In December 2001, accompanied by her boyfriend she made her annual trip to Florida. Although she had been in her usual state of independent living prior to her departure, she was found to have serious problems with

memory on arrival. She was unaware as to where she was. In a telephone conversation with her daughter, “she was talking nonsense”. During the next 2 months, memory and word finding continued to deteriorate. She was taken to the emergency room of the local hospital in Florida where a CT scan without contrast on 02/07/02 demonstrated mild cortical atrophy but no acute process. Her son drove to Florida and found that her memory was poor and her conversation did not make sense. “My husband is in the service: my mother died last year.” However she could play cards with her grand daughter. Her gait was slow and stooped. She had urinary incontinence on her way to the bathroom.

She had no history of alcoholism and took various vitamins and herbs.

Family history: her brother had died of a brain tumor of unknown type.

Neurologic examination: The positive findings were the following:

1. *Mental status:* The patient was awake and alert. Overall Mini-Mental Status Score was 19/30. The major problems were in orientation and in delayed recall. She was able to indicate that she was in a hospital in Massachusetts. And the date was February. She registered 3 objects but could recall any in 3 minutes. She was however able to read, name objects, follow instructions, spell “world” backwards and copy a figure. She was unable to draw a clock with the hands set at 11:10.

2. *Cranial nerves:* intact

3. *Motor system:* Although strength and tone were normal, her gait was broad-based and shuffling.

4. *Reflexes:* Patellar and Achilles reflexes were absent but plantar responses were flexor.

5. *Sensory system:* Intact.

Clinical diagnosis: 1) Subacute dementia: etiology uncertain possibly of Alzheimer’s or Lewy body type. Various entities such as chronic subdurals, tumor etc to be ruled out 2) Peripheral neuropathy, most likely etiology at this age diabetes mellitus.

Laboratory data:

1. *Basic CBC and chemistries:* Normal except for an elevated fasting glucose.

2. *CT scan (Fig 30-10):* An enhancing 2.75 cm tumor with a necrotic center was present in the thalamus at the level of the upper third ventricle. There was bilateral involvement of the anterior and medial thalamus but with no involvement of the posterior thalamus or hypothalamus. The study suggested a lymphoma or glioblastoma

Subsequent course *Stereotaxic biopsy of the right thalamus:* Frozen section raised the question of a lymphoma or glioblastoma but special immunological stains were consistent with a glioblastoma. Necrosis and endothelial hyperplasia were present. The patient was treated with dexamethasone and radiotherapy with improvement in gait.

Comment: This patient presents an unusual cause of a progressive alteration in memory. As indicated earlier in this chapter those patients with Wernicke’s encephalopathy who progress to the Korsakoff syndrome had persistent pathology in the medial and anterior thalamus with sparing of the posterior thalamus. In this case the pathology was a rapidly progressive glioblastoma multiforme. As discussed above, an occasional patients, glioblastomas may also produce dementia and a change in personality by infiltrating the prefrontal areas and corpus callosum. Occasionally a patient with a more diffuse neoplasm gliomatosis cerebri may also present with a similar syndrome of dementia which may mimic Alzheimer’s disease. These are however rare causes compared to the more frequent degenerative disorders.

COMPLETE CASE HISTORIES FROM TEXTBOOK: *INTEGRATED NEUROSCIENCES*
PART IV. CASES; CEREBRUM VISION, DISEASES, MEMORY

CHAPTER 23: VISUAL SYSTEM

The following case is an example of a lesion involving the optic nerve, anterior to the optic chiasm.

Case History 23-1 (Fig 23-8).

This 53-year-old white right-handed housewife was referred for evaluation of progressive right-sided supraorbital headache of 23 years duration and decreasing acuity in the right eye. The loss of acuity had progressed to the point of almost total unilateral blindness. During the 3 years before admission, intermittent tingling paresthesia had been noted in the left face, arm, or leg. About 1 year before admission the patient had a sudden loss of consciousness and was amnesic for the events of the next 48 hours. She was hospitalized, but no explanation for the episode was clearly established, although cerebrospinal fluid protein was reported to be elevated (230 mg/dl).

The patient and her family reported some personality changes over a period of several years, including a loss of spontaneity and increasing apathy.

General Physical Examination: Unremarkable except for a minor degree of proptosis (downward protrusion of the right eye).

Neurologic Examination:

1. *Mental Status*: The patient was, in general, alert but at times would become lethargic. Her affect was flat. At times, she would laugh or joke in an inappropriate manner.
2. *Cranial Nerves*: There was anosmia for odors, such as cloves, on the right and a reduced sensitivity on the left.

Marked papilledema (increased intracranial pressure with protrusion of the optic disk and venous engorgement due to obstruction of the normal flow of CSF) was present in the left eye.

Pallor of the right optic disc was present, indicating optic atrophy. Visual acuity in the right eye was markedly reduced. The patient had only a small crescent of vision in the temporal field of the right eye, where only vague outlines of objects could be seen. A slight left central facial weakness was present.

3. *Motor Systems*: Intact although movements on the left side were slow.

4. *Reflexes*: A release of grasp reflex was present on the left side.

5. *Sensory system*: Intact

Clinical diagnosis: Subfrontal meningioma arising from olfactory groove or inner third sphenoid wing.

Laboratory data:

1. *Skull x-rays* demonstrated erosion of the dorsum sellae. Special lamniograms demonstrated hyperostosis of the sphenoid bone (planum sphenoidale) suggesting a meningioma originating from the sphenoid bone.

2. *EEG* demonstrated focal 2-4 Hz slow waves in the right anterior temporal and anterior lateral frontal area.

3. *Brain scan (H_g 197)* revealed a heavy uptake of isotope in the right posterior subfrontal area.

4. *Arteriograms* indicated that the anterior cerebral arteries were shifted backwards, posteriorly and the left. A tumor blush was present on the venous phase in the right subfrontal area extending back to the optic nerve groove (Fig 23-8). These findings were felt to be most consistent with an olfactory groove meningioma.

Hospital course: Dr. Samuel Brendler performed a bifrontal craniotomy which exposed a well-encapsulated smooth tumor attached to the medial third of the sphenoid wing. After intracapsular removal of 90 to 95% of the tumor, the right optic nerve could be visualized. The small portion of the tumor attached to the bone could not be removed because of considerable bleeding from the bone. Examination 4 months after surgery, indicated right anosmia and right optic atrophy were present.

Comment

If one considered only the patient's primary complaint, decreasing vision in the right eye, and the findings of right optic atrophy and left-sided papilledema (Foster-Kennedy syndrome), then the most probable diagnosis was inner-third sphenoid meningioma. The preservation of a small crescent of vision in the temporal field is consistent with compression of the optic nerve on its lateral surface. By the time of hospitalization, the lesion was quite large and had extended into the subfrontal area, producing anosmia on the right and some changes in personality. At this point, the various diagnostic studies suggested only a subfrontal mass and did not clearly differentiate between an olfactory-groove meningioma and a sphenoid-wing meningioma. One might suggest, in retrospect, that the degree of involvement of the right optic nerve was much more pronounced than the changes in prefrontal functions, and therefore, the inner-third sphenoid-wing location was more likely.

The surgical approach in any case was the same. The eventual recovery of vision in such cases is uncertain because the effects of compression often are not reversible.

The following case 23-2 provides an example of a macroadenoma of the pituitary producing a bitemporal adenoma..

Case 23-2. Patient of Dr. Martha Fehr. This 45-year-old man had an 18-month history of a progressive alteration in vision. He was unable to see objects in the right or left periphery of vision. He was concerned that in the process of driving he might hit pedestrians stepping off the sidewalks in the periphery of vision. He had also experienced over 6-8 months, progressive headaches, loss of energy and libido.

Neurological examination: Normal except for a bitemporal hemianopia.

Clinical diagnosis: Pituitary adenoma compressing the optic chiasm.

Laboratory data:

1. *Endocrine studies:* all were normal including prolactin, am cortisol, and thyroid functions.

2. *MRI:* A large macroadenoma measuring 3 cm in diameter extended outside of the sella turcica to compress the optic chiasm (fig. 23-11).

Subsequent course: Dr. Gerald McGuillicuddy performed a gross total trans sphenoidal resection of the tumor, with a significant improvement in vision. Three years later, the patient again had visual symptoms and eye pain. MRI scans indicated regrowth of tumor with possible impression on the right optic nerve. He was treated with radiotherapy.

Comment: Note that males are more likely to present with large pituitary adenoma compressing the optic chiasm. Women are more likely to present with microadenomas or small macroadenomas since they are more likely to be seen at an earlier stage due to an initial complaint of amenorrhea. Thus complaints of decreased libido in men are likely to be mentioned only in retrospect and not as an early presenting complaint.

The following case illustrates the effects of a space-occupying lesion in the occipital lobe. One should compare these findings to those reported earlier in Case 23-1, in which there was a lesion in the visual system anterior to the optic chiasm.

Case 23-3: This 47-year-old white, right-handed, real estate salesman was referred for evaluation of headache and visual disturbance. One month before admission the patient had a cough with some blood present in the sputum (hemoptysis). Five days before admission the patient developed a generalized headache, which was

precipitated by coughing or straining and which awakened him or prevented him from sleeping.

Two days before admission, the patient noted blurring in the left inferior quadrant of his field of vision.

The day before admission, he noted complete loss of vision in this quadrant. On the day of admission, the headache increased, and the patient was unable to see anything in the left visual field.

He had experienced no weakness, no disturbance of memory, and no language disturbance.

Past history was significant. The patient had multiple pulmonary infections, treated with antibiotics.

Neurologic examination:

1. Mental status: Intact

2. *Cranial nerves* were intact, except that blurring of disc margins was present bilaterally, with venous engorgement, indicating early papilledema.

A left non congruous homonymous hemianopia was present (Fig. 23-14A).

3. Motor system: Intact

4. Reflexes: *Deep tendon reflexes were slightly more active on the left. The plantar response on the left was extensor that on the right was flexor*

Laboratory data:

1. *Electroencephalogram* was abnormal because of frequent focal 3 to 4 cps, slow waves in the right occipital area and to a lesser degree, in the right posterior parietal area, consistent with focal damage in the right occipital area.

2. *Cerebrospinal fluid* pressure was elevated to 210 mm H₂O. The number of white blood cells was increased to 97 lymphocytes (upper normal limit is 5 to 7 lymphocytes). Protein was increased to 75 mg/dl (upper normal limit is 45 mg/dl). Glucose was 75 mg/dl (normal when compared to blood sugar of 95 mg/dl).

3. *Imaging* (radioactive brain scan Hg 197) demonstrated an enhanced region in the posterior and medial aspect of the right hemisphere (occipital and adjacent parietal lobes).

Subsequent course: The patient was treated with antibiotics (cephalothin sodium, penicillin, and streptomycin). Visual fields, EEG, and spinal fluid findings improved. Within 3 weeks the field defect had resolved to a non congruous left inferior quadrantanopia (Fig. 23-14B).

Ten days later the patient was readmitted to the hospital with a three-day history of right eye pain, sweats, and chills. Neurologic examination now revealed a recurrence of blurred optic-disc margins, a left homonymous hemianopia and a slight increase in deep tendon reflexes on the left. Imaging studies now revealed a large space-occupying lesion in the right parietal/occipital region, displacing the right lateral ventricle forward and downward.

After 10 days treatment with antibiotics (penicillin and streptomycin), a craniotomy was performed by Dr. Bertram Selverstone. A mass could be palpated medially in the right occipital and adjacent posterior parietal area. The abscess and a large surrounding area of hard granulomatous cortex and white matter were removed. (The etiologic organism was subsequently found to be a *microaerophilic streptococcus*.)

Postoperatively, the patient continued on treatment with penicillin. Follow-up examination 6 months after surgery was normal, except for the left homonymous hemianopia (Fig. 23-14C).

Comment: The rapid evolution of neurologic signs and symptoms in this case; the early development of papilledema, and the progressive changes in the electroencephalogram and brain scan; is consistent with the diagnosis of brain abscess. The primary infection in this case was probably in the lung.

The initial visual symptoms of inferior field involvement (quadrantanopia) suggested that the abscess, in its early stages, involved predominantly the superior portion of the optic radiation in the posterior parietal/occipital area or the superior bank of the calcarine fissure. With progression of the lesion, the entire optic radiation or the entire calcarine cortex was involved. The lesion found at surgery had destroyed or damaged both these areas.

The treatment of a brain abscess requires appropriate pre- and postoperative use of antibiotics. Many of these patients develop focal seizures at some time after successful surgical treatment of the abscess. Although prophylactic anticonvulsant medication, such as diphenylhydantoin (Dilantin), has been routinely administered, the value of such treatment remains unclear.

Note an important negative finding in this case: at no time did the patient experience any language disturbance. Reading and writing remained intact, as did the capacity for to construct drawings. This case involving the right occipital lobe should be compared with Case History 21-2, in which a focal lesion of the left occipital lobe was present.

The following is another example of the effects of a lesion in the occipital lobe with very different consequences than those seen in the previous case. The lesion clearly involved the cerebral cortex producing focal seizure activity.

Case 23-4. (Fig 23-15): This 18-year-old left-handed single white female restaurant employee was referred for reevaluation of a seizure disorder. While living in the south western United States, the patient had the onset of her seizures at age 14 when she had a sequence of five seizures in less than 12 hours. Each began with flashing lights, “like Christmas tree lights,” all over her visual field, plus the sensation that peoples’ faces were moving. She then would have an apparent grand mal seizure. She was hospitalized. The neurological examination was reported as normal. An electroencephalogram report noted occasional focal sharp and slow waves in the left hemisphere. The CT scan was interpreted as essentially within normal limits. In retrospect, there was a question of some mottled hypodensity in the left occipital area, not clearly distinguished from artifact. The patient was treated with carbamazepine (Tegretol), 400 mg in the morning, and 230 mg at hour of sleep. In the interim, she apparently had done quite well with no additional grand mal seizures. She had rare episodes of “fear attacks,” which would last 23 to 25 minutes. The last attack had occurred 2 years ago, but as recently as two months ago, she had had one episode of flashing lights. A recent EEG was normal.

Past history was negative, except her birth weight was ten pounds, three ounces, and there was a problem of breathing at birth. She had always done poorly in school. Her family history did not suggest possible causes for a seizure disorder.

Neurologic examination: Normal.

Clinical diagnosis: Seizures of focal origin occipital cortex, (flashing lights and movement of the lights) probably left hemisphere based on the reports received of the EEG. There was subsequent spread of discharge into the temporal lobe based on the report of “fear attacks”

Subsequent course

The patient did well for 3 years then had a recurrence of a generalized convulsive seizure possibly related to omission of medication. Six weeks later, she reported two additional episodes characterized by flashing lights, then movement of the lights away from a center circle, then dizziness, then a

sensation of unreality. She also had other episodes of feeling unreal accompanied by fear. There were no olfactory hallucinations and no other visual or auditory hallucinations. The neurologic examination now demonstrated a minor right central facial weakness not present previously.

Laboratory data:

1. *EEG*: remained normal.
2. *MRI scan*: now revealed a small tumor at the left occipital pole with surrounding edema (Fig. 23-15). On CT scan, this tumor appeared partially calcified but did show enhancement. Angiograms suggested tumor vascularity of a type seen with meningiomas.

Subsequent course: Dr. Bernard Stone removed a discrete encapsulated tumor that appeared to be a meningioma. Subsequent microscopic examination, however, indicated a rare type of indolent follicular adenocarcinoma of the thyroid, which sometimes spreads as a single lesion to brain and remains quiescent for many years. In the postoperative period, a non-congruous right-inferior-field defect was present (partial quadrantanopia). The blood level of thyroid-stimulating hormone (TSH) was elevated. A thyroid nodule was found. A thyroidectomy was performed, and thyroid replacement medication was prescribed. No additional seizures were observed over the next 18 months. A metastatic lesion in the lumbar vertebral body subsequently appeared.

Comment: This patient presented many of the features of focal seizures arising in the occipital cortex: flashing lights, movement of objects and secondary generalization. Some of the seizure phenomenology such as “fear attacks,” dizziness, and “feeling unreal” suggested that spread into the temporal lobe was sometimes occurring. The student should now compare and contrast the cases presented in the previous chapter on the limbic system to this case to be able to note the differences seen after lesions in these adjoining cortical regions.

CHAPTER 24: SPEECH, LANGUAGE FUNCTION, APHASIAS, AGNOSIAS, APRAXIA

The following case, 24-1 presents an example of a selective non fluent aphasia of aphasia. An embolus to the superior division of the left middle cerebral artery produced marked weakness of the face tongue and distal right upper extremity and a severe selective nonfluent aphasia. The

hand weakness rapidly disappeared, the right central facial weakness, an apraxia of tongue movements and some expressive difficulties persisted.

Case 24-1: This 55-year-old, right-handed white housewife while working in her garden at 10:00 a.m. on 04-15-69, the day of admission suddenly developed a weakness of her right side and was unable to speak. Apparently, the right-sided weakness affected predominantly the face and arm since the patient was able to walk. The past history was significant. In 1960, nine years previously, the patient had been admitted to the hospital with a three-year history of progressive congestive heart failure secondary to rheumatic heart disease (mitral stenosis with atrial fibrillation). An open cardiectomy was performed with a mitral valvuloplasty (the valve opening was enlarged). A thrombus found in the left atrial appendage was also removed. Postoperatively, the patient was given an anticoagulant, bishydroxycoumarin (Dicumarol). Although atrial fibrillation continued, she did well until the day of admission. Prothrombin time at the time of admission was close to normal; that is, the patient was not in a therapeutic range for anticoagulation.

General physical examination: Blood pressure was moderately elevated to 170/80. Pulse was 110 and irregular (atrial fibrillation). Examination of the heart revealed the findings of mitral stenosis: a loud first sound, a diastolic rumble and an opening snap at the apex as well as the atrial fibrillation.

Neurological examination:

1. Mental status and language function:
 - a. The patient was alert.
 - b. She had no spontaneous speech and could not use speech to answer questions and could not even use yes or no to provide answers. She could not repeat words.
 - c. The patient was, however, able to indicate answers to questions by nodding (yes) or shaking her head (no), if questions were posed in a multiple choice situation. In this manner it was possible to determine that she was grossly oriented for time, place and person.
 - d. The patient was able to carry out spoken commands and simple written commands, such as, "hold up your hand, close your eyes." However, she had significant difficulty in performing voluntary tongue movements (such as "wiggle your tongue"; "stick out your tongue") on command.
2. Cranial nerves:
 - a. The patient tended to neglect stimuli in the right visual field.
 - b. She was unable to look to the right on command although the head and eyes were not grossly deviated to the left at rest.
 - c. A marked right supranuclear (central) type facial weakness was present.
 - d. The patient had difficulty in tongue protrusion. When the tongue was protruded it deviated to the right. The patient was unable to wiggle the tongue.
3. *Motor system:* Strength: there was a marked weakness without spasticity in the right upper extremity, most prominent distally. Some shoulder movements were possible; no hand or finger movements could be made. There was a minor degree of weakness involving the right lower extremity (75 percent of normal).
4. Reflexes:
 - a. Deep tendon stretch reflexes were increased on the right in the arm and leg.
 - b. Plantar responses were both extensors; more prominent on the right.
 - c. The abdominal reflex was absent on the right; present on the left.
5. Sensory:
 - a. Pain, touch and vibration were intact.
 - b. It was difficult to test other modalities but tactile localization appeared to be intact.

Clinical diagnosis: Embolus from heart to left middle cerebral artery

Laboratory data:

1. *Skull X-rays* were normal.
2. *EEG* was normal (48 hours after admission).
3. Cerebrospinal fluid was normal.
4. *Electrocardiogram* revealed atrial fibrillation

Hospital course: Within 24 hours a significant return of strength in the right hand had occurred; independent finger movements could be made. Within 48 hours after admission the patient was able to

repeat single words but still had almost no spontaneous speech. She appeared aware of her speech disability and would manifest some frustration. She was able to carry out two- or three-stage commands although tongue movements and perseveration remained a problem. Within 6 days of admission the patient used words, phrases and occasional short sentences spontaneously. She was better able to repeat short sentences. At this time strength in the right arm had returned to normal, but a right central facial weakness was still present. More detailed language evaluation two weeks after admission indicated the persistence of expressive disabilities consisting of word-finding and apraxic components. The apraxic components were evident on tongue placement and alternating tongue movements. Although complete sentences were used, sentence formulation in spontaneous speech was slow and labored with word finding difficulties. Repetition was better performed. In reading sentences aloud, substitutions or word omissions were made. The patient did well in naming common pictures and in matching printed words to spoken words or printed words to pictures. She could write from dictation and would often respond preferentially in writing when difficulty in speaking was encountered. No left-right confusion was present. Minor difficulties with simple arithmetic were reported. A right central facial weakness was still present.

Comment: There would appear little doubt that this patient had the sudden passage of an embolus (presumably from the left atrial appendage) into the left middle cerebral artery. In view of the selective face and arm weakness with a predominant expressive aphasia, the involved vessels must have been cortical branches such as the prerolandic and rolandic originating from the superior division of the middle cerebral artery. From the onset, it was clear that although some receptive components might be present, these were minor. The major problem was a severe nonfluent aphasia. As the hand weakness disappeared, the only other residual neurological findings were those of a right central facial weakness and an apraxia of tongue movements. Such findings would, of course, be consistent with a relatively selective involvement of Broca's area in the inferior frontal gyrus.

Why did such a rapid improvement occur in motor function and of the visual field? Most likely, the embolus fragmented and passed into the cortical branches supplying Broca's area.

With the passage of time, this type of patient would continue to show some degree of improvement (Mohr, 1973). Improvement could continue to occur over a two-year period. Although lesions of Broca's area may produce the acute onset of a nonfluent aphasia, rapid amelioration of the deficit occurs even when the acute lesion involves underlying white matter, as well as the superficial cortex.

In the following case 24-2, a more persistent anterior aphasia is demonstrated.

Case 24-2: On May 30, 1985, at midday, this 37-year-old right-handed woman with a past history of rheumatic fever, rheumatic heart disease and "an irregular pulse"(atrial fibrillation) had the sudden onset of loss of speech, central weakness of right face, an inability to protrude the tongue and a right hemiparesis. Although hemiparesis, face and tongue problems disappeared within a week, recovery of speech was slower and limited. At one week, she could produce some two syllable words.

Neurological examination at 17 months revealed the following residual findings:

1. *Language function:* Spontaneous speech was slow and relatively scanty. She could name objects slowly without difficulty, could do some simple repetitions and could write from dictation. She could carry out two and three stage commands. She could read slowly aloud but had little comprehension of what she read.
2. *Reflexes:* A residual right Babinski sign and right-sided hyperreflexia were present.

Clinical diagnosis: Anterior aphasia: embolic infarct of superior division of middle cerebral artery.

Laboratory data:

Although initial CT scans in May 1985 had been reported as negative; the MRIs in November 1986 and June 1990 demonstrated the infarct which included Broca's area, as well as adjacent frontal areas with predominant involvement of frontal operculum (inferior frontal gyrus) and adjacent middle frontal gyrus. In addition, a minor independent infarct was present in right occipital area (presumably embolic to the calcarine artery).

Subsequent course: Similar findings were present at 5 years, June 1990).

A brain section from a patient (Case 24-3) with a persistent nonfluent aphasia (is presented in Figure 24-4.

Case 24-3: This 69-year-old, right-handed male expired in 1965. In 1961 and 1963, The patient, had experienced transient episodes of right hemiparesis and aphasia, both followed by complete recovery. In 1964, a more persistent right hemiparesis and aphasia had developed.

General physical examination: No left carotid pulsation was present.

Neurologic examination(1965):

1. **Language functions:** Speech was nonfluent with only a small verbal output. A significant nominal aphasia with paraphasias was present. Reading was limited. Comprehension of spoken language was good. A marked apraxia was present for movements of tongue, lips and hands.
2. **Motor system:** Right hemiparesis with associated reflex findings.
Post mortem findings: Left carotid occlusion with old infarction, predominantly of left middle cerebral territory with lesser involvement of anterior cerebral territory. Note that minor cortical infarcts are also present involving cortex of right hemisphere.
(Courtesy of Dr. John Hills,; and Dr. Jose Segarra.)

Case 24-4 provides an example of a patient with a Wernicke's type aphasia

Case 24-4: This 40-year-old, right-handed white male had experienced a series of myocardial infarctions beginning 10 months prior to consultation. Angiographic studies indicated occlusion of the right coronary artery and the left anterior descending coronary artery with stenosis of the circumflex artery. The patient was subsequently admitted and a coronary artery bypass procedure was performed using extracorporeal circulation. Although the patient was stated to have tolerated the procedure well, the anesthetist noted that the patient was nonreactive 15minutes after the last administration of halothane anesthesia. When the patient did wake up, he was quite agitated requiring the use of agents to reduce agitation. Throughout the postoperative period, the patient continued in a disoriented and combative manner. Because of the patient's acutely psychotic state, transfer to the psychiatry service was actively planned. Because there were certain organic features to the patient's illness, a neurological consultation was obtained. The neurology resident in reviewing the progress notes discovered a notation that shortly after surgery the patient had transient difficulty in using his right arm.

Neurological examination:

1. **Mental status:**
 - a. The patient was an alert but agitated white male. Additional inquiries indicated that his agitation related to his inability to write a letter to his mother.
 - b. The patient's speech was fluent and usually grammatical. He made use of many paraphasias and neologisms (nonsense words). He often appeared unaware of his errors.
 - c. The patient was unable to name single objects such as pencil, cup, and spoon though he could recognize and demonstrate their use.
 - d. The patient could read occasional individual words; for example, cat, house. He could not comprehend or carry out, either spoken or written commands.
 - e. His attempts at spontaneous writing produced only a few letters. He was unable to write words or phrases from dictation. He did significantly better when asked to copy a printed sentence or phrase.
- f. Repetition of spoken phrases or sentences was poor.
- g. Calculations of even a simple nature were poorly performed.
2. **Cranial nerves:** II-XII was intact.
3. **Motor system:** No actual weakness was present. Gait was intact.
4. **Reflexes:**
 - a. A minor increase in deep tendon stretch reflexes was present on the right side.
 - b. The plantar response on the right was equivocal. The left was flexor.
5. **Sensation:** Pain, touch and vibration were intact.

Clinical diagnosis: Wernicke's type of fluent aphasia probably secondary to an embolus to the inferior division of the middle cerebral artery.

Comment: This patient who was seen before the era of modern neuroimaging provides an example of the clinical picture described by Wernicke. The use of the heart pump for open-heart surgery was associated with a high incidence of cerebral

emboli. The incidence of this complication has decreased as technical advances have been made and as “time on the pump” has decreased. As we have stressed, for solving neurological problems, the details of the history are important if the appropriate diagnosis is to be made. In the patient who is unable to provide a history, the careful review of progress notes and of nurses notes will often provide the clue that allows diagnosis.

The following case history 24-5 demonstrates such a sequence of involvement in a tumor infiltrating the posterior temporal inferior parietal area starting with a conduction aphasia.

Case 24-5: This 42-year-old right handed truck driver noted fatigue and irritability 6-8 weeks prior to admission. Three to four weeks prior to admission, he noted he was using words which he did not mean to use and certain words would not come to him. He had two generalized convulsive seizures; each proceeded by a ringing sensation in the ears, during the week prior to admission.

Neurological examination:

1. Mental status and language function

- a. The patient was alert and oriented to time, place and person.
 - b. He was cooperative and able to carry out the four-step command: “stick out your tongue, close your eyes, hold up your hand and touch the thumb to your ear”. There was however evidence of a significant left-right confusion when laterality was introduced e.g. “left hand to right ear”.
 - c. The ability to do even simple calculations was markedly impaired with or without paper e.g. $100-9=99$.
 - d. Memory was impaired; with immediate recall object recall limited to 2/5 objects and delayed recall in 5 minutes limited to 0/5. Digit span was limited to 2 forward and 0 in reverse. (normal would be 7 forward and 6 in reverse).
 - e. There was little evidence of an expressive aphasia. Flow of speech was slow with only minor mispronunciations. Reading was slow but with few errors. The patient’s did have minor difficulty in naming objects-a mild nominal aphasia. The patient’s greatest difficulty was in repetition of simple test phrases. There were moderate defects in drawings of a house and a clock but few errors in copying simple figures. There was a significant dysgraphia with marked difficulty in writing a simple sentence spontaneously or in writing from dictation. On the other hand, the patient was much better able to copy a simple sentence. Significant errors were made in spelling.
2. **Cranial nerves:** All were intact except for a mild right central facial weakness.
 3. **Motor system:** Strength, gait and cerebellar functions were all intact.
 4. **Sensory system:** Pain, touch, vibration, stereognosis, simultaneous stimulation, graphesthesia, and position sense were all intact, but point localization was impaired on the right side.

Clinical Diagnosis: Fluent posterior aphasia, disconnection syndrome plus elements of Gerstmann’s syndrome (left right confusion, dyscalculia, dysgraphia) plus seizures of focal origin (Heschl’s gyrus posterior temporal lobe) with secondary generalization. All suggested a lesion in the left posterior temporal-posterior parietal area.

Etiology was uncertain but tumor (glioma) or embolus to inferior division of left middle cerebral artery possible.

Laboratory data:

1. Skull and chest x-rays were normal.
2. **EEG:** Focal 4-5 Hz slow wave activity was present in the left parietal and posterior temporal areas.
3. **Brain scan (radioactive Hg 197):** Increased up take of isotope in the left posterior temporal –parietal area measuring 4x5 cm.
4. **Left carotid arteriogram:** Vascular mass in the region of the angular gyrus with tumor stain in the area.

Subsequent course: Papilledema soon developed and Dr. Robert Yuan performed a craniotomy. Although the cortex appeared externally normal, a firm mass could be palpated

slightly above and posterior to the angular gyrus. At 2 cm below the surface, firm yellow tumor tissue was encountered. All visible tumor and adjacent cortex of the angular and supramarginal gyri were removed and a partial left temporal lobectomy was performed. Histologic examination indicated a highly malignant glial tumor with active mitosis and necrosis (a glioblastoma multiforme). Post operatively, the patient had a marked expressive and receptive aphasia. By 30 days after surgery, the patient had a significant improvement in fluency, he continued to have a severe posterior type of aphasia. He was unable to carry out simple commands. His speech was incoherent, with nonsense words and neologisms. He appeared unaware of his errors and did not appear frustrated by his failure to follow commands. In addition to this Wernicke's type aphasia, the patient was unable to repeat words of two syllables. He could do no calculations, had severe difficulties in copying drawings and was unable to even write his name. The patient received radiotherapy but his condition continued to worsen with the development of a progressive expressive and receptive aphasia and hemiparesis all suggesting the spread of a rapidly growing glioblastoma. Coma, pupillary changes and respiratory changes then intervened suggesting the effects of herniation of the residual temporal lobe. Death occurred 7 months after onset of symptoms, and 5 months following surgery.

Comment: The early language and mental status disturbances in this patient were most severe in those tasks requiring repetition. Thus the patient could repeat no more than two digits, was unable to repeat any of the test phrases and was unable to write from dictation at a time when he could copy a sentence. Any expressive aphasia was minor, and he was fluent. He had no evidence of Wernicke type aphasia, since he could carry out a four-stage command without difficulty. Reading was relatively well preserved compared to writing, calculations and drawing construction. All of these findings suggest (1) the speech reception Wernicke's area was disconnected from the motor association areas for speech and writing Broca's areas 44,45 and the related areas of the premotor cortex and (2) the inferior parietal areas associated with writing, calculations, drawing, and the ability to distinguish left and right were damaged. The lesion found at surgery was deep to the angular and supramarginal gyri, the location of the arcuate sulcus. The seizures that finally brought the patient to neurological attention were originating in Heschl's gyrus of the temporal lobe, which would be adjacent to the area of the tumor.

The clinical state at 30 days following surgery reflected the additional effects of ablation of the Wernicke's area as well as the accentuation of the preoperative state. There had been the transient appearance of an expressive aphasia probably reflecting minor effects of the procedure on Broca's area.

The neurosurgical approach to the management of a glioblastoma particularly those involving the speech areas of the dominant hemisphere have changed in 35 years since this patient was seen. A limited stereotaxic biopsy under CT scan guidance would be undertaken and the patient would then be treated with dexamethasone and radiotherapy. The end results would have been similar and actually may even have occurred earlier. The postoperative quality of language function may have been transiently better. Unfortunately this patient had a very malignant and aggressive tumor. The median survival of glioblastomas with surgery alone is 26 weeks, with the addition of radiotherapy; 52-60 weeks. Median means that 50% of patients are going to survive less than these median figures.

The following case (24-6) provides a case of posterior aphasia with the lesion documented with CT scan.

Case 24-6: This 57-year-old female, with a long history of hypertension in the summer of 1985, had a brief episode of difficulty in word finding and a more prolonged episode in December 1985 with confusion, "visual problems", "inappropriate speech and difficulty finding the appropriate words". Following an additional episode in March 1986, she had persistent problems in reading and apraxia of the right hand.

Neurological examination (May 1986): The following abnormalities were present:

1. *Language function:* Spontaneous speech was usually quite fluent. She described the room, the environment and her friend. In contrast, capacity for repetition was very poor both as regards spoken and written speech. Spontaneous writing was very poor except for name and address

Reading to herself aloud was poor with little comprehension. She was able, however, to follow single one stage spoken or written commands but unable to do a sequence of commands. Naming of objects was well performed.

2. *Cranial nerves*: Extinction occurred in the right visual field for bilateral simultaneous stimuli.
3. *Motor system*: No hemiparesis was present.
4. *Reflexes*: Right-sided hyperreflexia and a right Babinski sign were present.

Clinical diagnosis: Posterior aphasia, infarction left posterior temporal and parietal areas, probably due to embolic occlusion of inferior division of the left middle cerebral artery.

Laboratory data:

1. *CT scan*: Infarct left posterior temporal and parietal areas (Fig. 24-6).
2. *Angiograms*: Occlusion of the left internal carotid artery. All anterior and middle cerebral artery branches filled from the right carotid. An artery to artery embolus was presumed.

The following case 24-7 would suggest this type of unilateral lesion producing a transient and partial but selective type of dyslexia.

Case 24-7: Seven days prior to admission, following a period of athletic activity, this 15-year-old, right-handed white male high school student had the onset of a 48-hour period of sharp pain in the left jaw and the supraorbital area. The next day the patient began to complain of blurring of vision and the following day had the onset of vomiting. Four days prior to admission, the patient noted that he was unable to read and to translate his Latin lessons. No definite aphasia was apparent. Two days prior to admission, the patient had the sudden onset of severe left facial pain, accompanied by tingling paresthesias of the right leg. The patient became stuporous and then unresponsive for approximately 90 minutes. An examination of spinal fluid at that time revealed pressure elevated to 290 mm of csf with 250 fresh blood cells.

Neurological examination:

1. *Mental status*: All aspects, including language function were intact.
2. *Cranial nerves*:
 - a. Examination of the fundus showed several small flame shaped hemorrhages. Visual fields were intact.
 - b. A slight, right, supranuclear-type (central) facial weakness was present.
3. *Motor system*: Intact
4. *Reflexes*: Deep tendon reflexes and superficial reflexes were symmetrical and physiologic.
5. *Sensory system*: Primary and cortical modalities were intact.
6. *Neck*: A slight degree of resistance was present on flexion of the neck (nuchal rigidity) consistent with the presence of blood in the subarachnoid space.

Clinical diagnosis: Subarachnoid hemorrhage of uncertain etiology. In view of age and the transient dyslexia, and the transient paresthesias of the right leg, an arteriovenous malformation in the left parasagittal parietal-occipital area might be suspected.

Laboratory data:

Arteriograms: An arteriovenous malformation was present in the left occipital region. The main arterial supply was the posterior temporal branch of the left posterior cerebral artery. The malformation drained into the lateral sinus. The posterior portion of the anterior cerebral artery was shifted across the midline, indicating a hematoma as well as the malformation.

Subsequent course: On that evening after his admission, the patient had the sudden onset of a bifrontal headache. For a 2- to 3-minute period, the patient was unconscious with deviation (repetitive driving) of both eyes to the right, and with sweating and slowing of the pulse rate. Over the next two days an increase in blurring of the optic disc margins was noted (early papilledema). Four days after admission, the patient suddenly complained of being unable to see from his right eye. He became restless and agitated. Additional headache and neck pain with numbness of right arm and leg were reported. Examination now disclosed a dense right visual field defect (homonymous hemianopsia). The deep tendon reflexes were now slightly more active on the right. Funduscopy suggested that

recent additional subarachnoid bleeding had occurred since new retinal hemorrhages were present. The next day (five days after admission), the patient was noted to have a significant reading disability (dyslexia), although other language functions were intact.

Because of the progressive evolution of neurological findings due to an expanding intracerebral hematoma, Doctor Robert Yuan performed a craniotomy. Blood was present in the subarachnoid space. The left lateral occipital cortical surface had numerous areas of bluish discoloration indicating an intracerebral clot. The main arterial vessel was a lateral and inferior branch of the posterior cerebral artery, bearing no relationship to the calcarine region. The draining vein was located in the occipital-temporal area, close to the tentorium. At a depth of 1 cm, a hematoma of 50 cc of clot was found. The clot extended down to the occipital horn of the lateral ventricle but did not enter the ventricle. The malformation, hematoma and related cerebral tissue of the lateral occipital area were removed. The calcarine area remained intact at the end of the procedure. Over a period of several days, the visual field deficits disappeared.

Detailed language and psychological testing approximately two weeks after surgery indicated that language function was intact except for reading. Oral reading was very slow (4 times slower than normal for a test paragraph), halting and stumbling. Comprehension of the material read was good. Minor errors were made in the visual recognition of letters. This was reflected in occasional errors in spelling. Visual recognition and naming of objects was intact. Auditory and tactile recognition of sounds, words, letters, sentences, questions, commands and so forth was intact. Calculations were intact. No right-left confusion or finger agnosia was present. Writing and drawing were intact but slow. Repetition of speech and spontaneous speech were intact.

Follow-up evaluation at 20 and 30 months indicated that, although the patient was doing well in school, receiving A's and B's with excellent grades in mathematics, he still was described as slow in reading compared to his level prior to illness. No actual errors were made in reading when this was tested.

Comment: The arteriovenous malformation in this case had involved and eventually required surgical removal of the lateral occipital area of the dominant hemisphere. The hematoma in the occipital lobe extending in from the lateral surface to the occipital horn was so located as to compress the optic radiation passing to the calcarine cortex or perhaps even to indirectly compress the calcarine cortex. Such a hematoma would also interfere with association fibers passing from left occipital areas to temporal parietal areas and with callosal radiation fibers passing from the occipital region (area 18) of the right hemisphere to the occipital and parietal areas of the dominant hemisphere. Following surgery, the patient had a relatively good recovery with the minor difficulties in reading; (a selective dyslexia) as perhaps the only indication of any damage to these fiber systems.

The complaint of the patient at the time that the right homonymous hemianopsia appeared was of blindness in the right eye. It is not uncommon for patients to localize field defects in this manner to the eye of the same side. The same may sometimes be true of patients with discharging lesions in the occipital area; the flashing lights and lines may be localized to the contralateral eye rather than to the contralateral visual field.

The episode on the night of admission is of interest because it suggests a focal adverse seizure, in this case presumably originating from areas 18 and 19 of the left hemisphere.

Geschwind (1965) has reviewed many of the previously reported cases of selective dyslexia. It is uncertain whether the information from area 18 of the non-dominant hemisphere passes to the non-dominant angular gyrus and then crosses to the dominant temporal parietal areas or whether these fibers pass instead directly to area 18 of the dominant hemisphere with information then conveyed to the dominant temporal parietal areas. He finally concludes that both pathways are probably operative. The relatively minor nature of the final residual deficit in the present case would be consistent with such multiple pathways. In addition, non-fatal hemorrhages always produce less damage than infarcts of comparable size. Finally, Coslett (2000) has reviewed various recovered pure cases of dyslexia where the right hemisphere may have played a role in reading. Such patients do better with concrete nouns than abstract nouns, verbs and functors (pronouns, prepositions, conjunctions and interrogatives). It should be noted that a relatively selective dyslexia in the absence of a severe general visual agnosia might occur. Geschwind has suggested that whether a general visual agnosia or dyslexia occurs may depend on the degree of disconnection of the dominant speech areas from the parietal and occipital areas of the non-dominant hemisphere. In the patient who already has left occipital cortex damage, dyslexia may require only damage to the splenium of the corpus callosum, whereas visual agnosia may require more extensive damage to the posterior body of the corpus callosum as well. As noted bilateral

visual association lesions (areas 18 and 19) would also produce a visual agnosia. (See also Coslett and Saffran 1989 and Friedman and Albert 1985).

In addition there are patients who have acquired dyslexia which is unrelated to the processing of the visual information input. These patients have a central (rather than the peripheral dyslexia of the pure alexia syndrome discussed above). The central dyslexic patient has an impairment of the “deeper” or “higher” reading functions by which visual word forms mediate access to meaning or speech production mechanisms. This problem is reviewed in detail by Coslett (2000).

Feinberg and Farah (2000) review the general topic of agnosias.

CHAPTER 26: VASCULAR SYNDROMES OF THE CEREBRAL HEMISPHERES

The following case history presents a young adult with severe carotid stenosis and infarction of the territories of both the anterior and middle cerebral arteries.

Case 26-1: This 23 year old right handed female on birth control pills, smoking one pack of cigarettes per day, on June 15, 1985 shortly after intranasal “snorting” of cocaine complained of gradually increasing right sided headache and then fell to the floor with a flaccid left hemiplegia with the head and eyes deviated to the right **Neurological examination:**

1. *Mental status:* The patient denied any illness and could not explain why she was in the hospital.
2. *Cranial nerves:* There was a left homonymous hemianopsia, deviation of head and eyes to the left and a left central facial weakness.
3. *Motor system:* A flaccid left hemiparesis was present.
4. *Reflexes:* deep tendon reflexes were initially depressed on the left side. Plantar responses were extensor bilaterally.
5. *Sensory system* a severe left hemisensory deficit, with a neglect of the left side of space and body was present.

Clinical diagnosis: Total right middle cerebral artery territory infarct.

Laboratory data:

1. *Initial CT Scan* demonstrated hypodensity (infarction in right frontal and parietal areas).
2. *Right carotid angiogram* demonstrated severe stenosis of the supraclinoid segment of the right internal carotid artery with severe stenosis of the M-1 segment of the right middle cerebral artery and multiple areas of narrowing of the remainder of the right MCA. *Left carotid angiogram* indicated only limited cross filling of the distal right middle and anterior cerebral arteries.

Subsequent course: On 6-21-85, 6 days after admission the previously alert patient suddenly developed a decreased level of consciousness and a fixed, dilated right pupil suggesting that tentorial herniation had been produced by severe edema or hemorrhagic transformation of the infarct. CT Scan now demonstrated massive infarction and edema-right anterior and middle cerebral artery territories plus-transtentorial and sub falx herniation (Fig.26-6). With emergency management of the increased intracranial pressure-(monitor and osmotic agents) the patient became more alert and was transferred to a rehabilitation facility.

Comment: This young woman had as a major risk factor, the intranasal snorting of cocaine. The vasospasm induced by this agent was sufficient to produce severe stenosis of the internal carotid and the initial segment of the middle cerebral artery. The multiple areas of narrowing seen in the branches of the MCA may well have represented emboli from these more proximal sources. Whether the severe stenosis of the M1 portion also involved an embolic event from the siphon remains unclear. It is clear that the severe stenosis of the carotid artery produced infarction of both the MCA and ACA territories. In this case there was insufficient cross flow from the left carotid supply to prevent infarction. As we will see in case 26-3 massive infarcts of the MCA territory plus or minus adjacent territories constitute a serious threat to life due to massive edema and or hemorrhagic infarction with the risk of herniation. The use of cocaine and of crack cocaine may be associated coronary or cerebral artery vasospasm. In addition to cerebral infarcts, cerebral hemorrhage may also occur, particularly with crack cocaine.

The following case history concerns a patient with severe stenosis at the carotid bifurcation producing both retinal and hemispheric TIA's.

Case 26-2: This 54-year-old, right-handed, white male had experienced intermittent episodes of blurring and blacking out of vision in the left eye for at least 7 years. Each episode would last 30 to 60 seconds and would occur twice per month. Ten days prior to admission, the patient had the onset of numbness of the right side of the face accompanied by minor weakness of the right face, arm, and leg. There was also a transient difficulty

in speech (possibly dysarthria, possibly difficulty in word finding). Symptoms cleared completely in 45 to 60 minutes with the exception of residual numbness of the right side of the face.

Family history: The patient's mother died of a "stroke" at age 66 years, and his father, of heart disease at age 57.

General physical examination:

- (1) Blood pressure was slightly increased to 160/100 in both arms. Pulse rate and rhythm were normal
- (2) Bruits (murmurs) were present over each carotid artery, but the heart was normal with no murmurs.
- (3) The retinal artery pulsation was easily obliterated by pressure on the globe of the left eye. No significant changes occurred on compression of the right globe.
- (4) Peripheral pulses were poor in the lower extremities.

Neurological examination: Mental status, language function, cranial nerves, motor system, reflexes, and sensory system were all normal except for a minor right central facial weakness.

Clinical diagnosis: Carotid stenosis with retinal and hemispheric TIA's.

Laboratory data:

1. Hemoglobin, serological tests for syphilis, skull and chest x-rays, electroencephalogram, and brain scan were all normal. Cholesterol was elevated to 284 mg%.

2. *Arteriography (aortic arch study)* demonstrated a complete occlusion at the origin of the left internal carotid artery. A right brachial arteriogram demonstrated filling of the left anterior and middle cerebral arteries by cross flow through the anterior communicating artery from the right side. Additional studies also demonstrated filling of the intracranial portion of the left internal carotid artery from the left posterior communicating artery.

Subsequent course: Ten days after that hospital admission, a left carotid endarterectomy was performed by Dr. Allan Callow with a restoration of blood flow following removal of the occlusive lesion (atherosclerosis with recent thrombosis) at the carotid bifurcation.

Comment: The location of disease in the left carotid artery was clearly indicated by the episodes of left eye visual disturbances followed by symptoms on the contralateral side of the body. The development of symptoms in the face, with disturbance of speech is consistent with total occlusion of the carotid artery, with greater involvement of the middle cerebral territory than of the anterior cerebral territory. The fact that this patient, with progressive stenosis of the carotid artery, had symptoms for many years only in the ophthalmic-retinal artery distribution, is explained by the excellent collateral flow into the anterior and middle cerebral arteries from the anterior communicating bypass. In addition collateral flow would enter the common carotid artery from the posterior communicating artery above the take off of the ophthalmic artery.

It should be apparent that the final complex of neurological symptoms and signs, occurring with occlusion of the carotid artery, will depend on the total pattern of cerebral blood flow in the individual patient. In many patients total occlusion of the carotid artery will produce an infarction of that portion of the cerebral hemisphere supplied by the carotid artery (primarily the middle cerebral territory). In others, a benign outcome is the result (Bornstein and Norris, 1989). With the development of imaging techniques such as CT and MRI scan - has come the recognition that small silent infarcts may occur in patients with non symptomatic stenosis of the carotid artery (Norris and Zhu, 1992).

In this case, the occurrence of symptoms in the right side of the face plus the difficulty in speech might raise the question of a possible embolus to a branch of the MCA from the thrombus at the bifurcation. A perfusion deficit would have produced problems primarily in the border zone (the area of the arm).

In this particular case, earlier evaluation of the patient might well have resulted in a demonstration of occlusive disease of the extracranial portion of the carotid artery

prior to total occlusion. For such patients surgical therapy is feasible. To restore blood flow 20 days after occlusion as in this case is unusual.

A question which remains unanswered in this case is whether this patient would have proceeded eventually to a completed lasting hemiparesis. Kase et al (1991) have summarized the various studies. The rate of completion of the stroke over a 40 month period varied from 2% (Marshall, 1964) to 51%.

The following case demonstrates a case in which the patient began with carotid TIA's progressed to a carotid border zone syndrome of infarction and then involved additionally all of the middle cerebral artery territory.

Case 26-3 (Pt. of Dr. Thomas Mullins): This 72-year old right-handed white male was admitted for evaluation of two episodes of right upper extremity weakness, each of two hours duration, beginning 2 days prior to admission. Following the first episode, the patient had persistent left-right disorientation, a deterioration in writing (dysgraphia), could not understand what he had read and had transient slurring of speech.

Neurological examination:

1. *Mental status and language function:* Intact for alertness and orientation. Language was fluent with intact repetition, and object naming; however, reading comprehension, writing, and left-right orientation were all impaired.
2. Cranial nerves: Intact.
3. Motor system, reflexes and sensory system were all entirely intact.
4. *Carotids:* A bruit was present on the left.

Clinical diagnosis: Carotid artery stenosis with TIA's reflecting decreased perfusion in the border zone followed by thrombosis and passage of emboli to the inferior division of the middle cerebral artery.

Laboratory Data:

1. CT scan and EKG were normal
2. An *arteriogram* performed on the day following admission demonstrated the following:
 - (a) The left internal carotid artery was completely occluded just above the bifurcation (Fig. 26-7A).
 - (b) The left external carotid artery did fill the left internal carotid artery at the siphon through anastomosis about the orbit (Fig. 26-7B). However, there was a cutoff just below the siphon suggesting that the thrombus (clot) at the bifurcation had extended to this level. Moreover, the left middle and anterior cerebral arteries failed to fill in this manner.
 - (c) The left posterior cerebral artery did originate from this segment of the otherwise occluded carotid siphon segment but with no retrograde filling into the basilar artery (Fig. 26-7B).
- 4) The right carotid artery filled not only the right middle cerebral and anterior cerebral artery but also was the source of the right posterior cerebral artery (Fig. 26-7C).
- 5) The right carotid system also supplied the left anterior cerebral artery and to a limited extent the left middle cerebral artery (Fig. 26-7D).

Subsequent course: On the day following admission, weakness in the right hand at wrist and finger extensors recurred. During the arteriogram, the patient was noted to have additional problems with speech. Weakness in the right upper extremity increased. Despite subsequent anticoagulation, additional progression occurred with total paralysis of the right upper extremity, aphasia and a right homonymous hemianopsia. A *repeat CT scan*, 72 hours after these events, demonstrated acute infarction with severe edema involving the entire cortical and deep territory of the middle cerebral artery and the cortical territory of the posterior cerebral artery but with relative sparing of the anterior cerebral artery territory and of the thalamic territory of the posterior cerebral artery (Fig. 26-8). Coma developed secondary to the herniation effects on the brainstem and the patient expired 8 days after admission.

Comment: This patient clearly had hemispheric carotid border zone TIA's followed by persistent symptoms that suggested involvement of the inferior division of the middle cerebral artery to the inferior parietal lobule. These latter persistent symptoms may well have been embolic from the thrombus at the level of the carotid bifurcation. There then was progression of the border zone findings

followed by involvement of the entire middle cerebral artery territory and of the cortical territory of the posterior cerebral artery. The end result was a massive cerebral infarct with considerable swelling. Such massive swelling with herniation of temporal lobe through tentorium and secondary brainstem compression is the major cause of acute death in patients dying after acute carotid artery or massive middle cerebral artery infarctions (31%). Other causes of death are pneumonia (29%), cardiac arrest (17%), pulmonary embolus (13%) (Bounds et al 1981).

Not all patients with acute carotid infarcts continue to progress. In the series of Jones and Milliken (1976), 39% of patients remained stable. Thirty-five percent had gradual improvement and 19% had a progressing deficit over 48 hours.

The following case history illustrates such an occlusion with massive infarction of the entire territory of the middle cerebral artery.

Case 26-4: This 61-year-old, right-handed black housewife one week prior to admission, suddenly fell to the floor while taking a bath and lost consciousness. She was picked up off the floor by her son who found that she was unable to move her left arm and leg. She was unable to walk and had regained no function in these extremities. Her speech had been thick, but no aphasia had been present. No headache had been noted.

Past history: Hypertension had been present for three years. Five days prior to admission, she had been switched to a new antihypertensive medication. There was no history of heart disease. Both parents had died of heart disease and hypertension.

General physical examination: Blood pressure was 150/100, pulse was regular at 84. Blood pressure was 150/100, the pulse was 84 and regular.

Neurological examination:

1. *Mental status:* The patient was obtunded and slow to respond. However, she was grossly oriented to time, place, and person.

2. *Cranial nerves:*

- a. The head and eyes were deviated to the right. The patient could not move the eyes to the left on command. However, on vestibular stimulation, the eyes could be moved to the left.
- b. The patient neglected stimuli in the left visual field. The pupils did respond to light.
- c. Papilledema was present bilaterally particularly in the right fundus where a recent hemorrhage was present.
- d. There was a decrease in pain sensation or a neglect of painful stimuli on the left side of the face.
- e. A marked left central facial weakness was present.

3. *Motor system:* A complete flaccid paralysis of the left arm and leg was present. The patient was unable to sit up without support.

4. *Reflexes:* Deep tendon reflexes were increased on the left compared to the right. The left plantar response was extensor.

5. *Sensory system:* All modalities of sensation were decreased on the left side of the body.

Clinical diagnosis: Acute occlusion of the stem of the middle cerebral artery, possibly embolic, although primary occlusions of intracranial arteries may occur in the non-Caucasian population. Hypertensive intracerebral hemorrhage was a less likely possibility.

Laboratory data:

1. *Chest and skull x-rays* were negative but the *electrocardiogram* showed left ventricular hypertrophy.
2. *Electroencephalogram* indicated focal damage throughout the right hemisphere—most prominent in the right frontal area, (focal 3 to 5 Hz slow waves). In addition there was a relative absence of electrical activity in the right temporal area (Fig. 2-23) consistent with a severe degree of destruction of this area.
3. Brain scan 3 days after admission showed a significant but diffuse uptake of isotope (Hg^{197}) in the right hemisphere. A repeat brain scan on 9 days after admission showed a more marked uptake measuring 11x6x6 cm., extending from the right frontal area to the posterior parietal area. Uptake extended from the surface to the deep midline (Fig. 26-14).
4. Cerebrospinal fluid contained no significant cells. Protein was moderately increased to 57 mg./100 ml. Pressure at the lumbar area was 150 mm. of csf.
6. Right brachial arteriogram revealed a complete occlusion of the right middle cerebral artery at its origin (Fig. 26-15).

Hospital course: The patient showed no significant improvement during a four week hospital course.

Comment: The patient had a sudden occlusion of the right middle cerebral artery with massive infarction of the entire area of the right hemisphere supplied by the middle cerebral artery. Such massive infarctions are often, as in this case, associated with a significant degree of cerebral edema with the development of papilledema. At times the degree of swelling of the cerebral hemisphere may be sufficient to displace the pineal or the anterior cerebral artery. It is also possible in this case that the infarct was secondarily hemorrhagic. In many cases of hemorrhagic infarction the spinal fluid does not contain red blood cells.

The equal involvement of arm, arm, and leg was consistent with the involvement of the penetrating branches of the middle cerebral artery with resultant infarction in the posterior limb of the internal capsule. The deviation of head and eyes to the right indicates destruction of area 8 of the right hemisphere or of the fibers descending from this area, through the corona radiata. Involvement of the cortex in addition to this the internal capsule is also indicated by the findings on the brain scan and electroencephalogram and by the neglect of visual and tactile stimuli on the left side. As regards the etiology, an embolus to the middle cerebral artery is the most likely etiology although in a non-Caucasian patient, primary occlusion could not be ruled out. Today this patient would probably have been treated with t-PA presuming that she had arrived at an emergency room capable of administration of this agent within 3 hours of onset of symptoms and did not have contraindications in terms of preexisting conditions or of CT scan findings (hemorrhage or massive infarction -refer to Brott & Bogusslavsky, 2000) .

Prognosis for survival during the acute state of the first week depends on the degree of edema patients with massive middle cerebral artery territory infarcts due to MCA occlusion who already had early CT scan evidence of brain swelling within 24 hours of the ictus. Fifty five percent of these patients expired ,overwhelmingly of herniation effects. Patients older than 45 years had a poorer prognosis than younger patients. Infection of the lungs is a serious complication of large infarcts and a major cause of death during the second week. If the patient survives ,prognosis for recovery is related to the size of infarct. Less than 3 cm. infarcts may be associated with a good recovery ; greater than 3 cm. with severe disability (Olson ,1991). This patient had already survived for one week prior to reaching the neurologic center. Although she continued to survive, her prognosis for recovery remained poor.

The following case history illustrates many aspects of ischemia within the cortical distribution of the posterior cerebral artery. This patient demonstrates the general rule that posterior cerebral cortical infarcts are usually embolic.

Case 26-5: This 55 year old ambidextrous married white female research coordinator at approximately 11:30 AM on the day of admission suddenly developed blurring of vision possibly all over her field of vision, possibly in her left visual field, possibly in her left eye. A coworker checked her vision, and found that she had a left visual field defect. Shortly thereafter, she developed tingling paresthesias of the left face arm and leg.

Past history: Hypertension treated with hydrochlorothiazide and Lasix.

Physical examination: Blood pressure was elevated to 160/70. Weight was elevated to 264 pounds .A small ecchymosis was present under the toenail of the left second digit.

Neurological examination,(3hours after onset):

1.Mental status: Intact .

2.*Cranial nerves:* A non-congruous left homonymous hemianopsia was presented greater in the left temporal field than the right nasal field.

3.Motor system: Intact.

4.*Reflexes:* Deep tendon stretch reflexes were decreased in the lower extremities (patella,1+ and Achilles,0). Plantar responses were equivocal ,with the left probably extensor.

5.*Sensory system:* There was decreased pain and errors were made in graphesthesia over the left foot.

6.*Vascular:* There were no bruits over the carotids and subclavian areas and the blood pressures in the two arms were equal.

Clinical diagnosis: Posterior cerebral artery ischemia and possible infarct, probably embolic, involving the right calcarine cortex and thalamus or a lacunar event involving the right thalamus.

Laboratory data:

1. Duplex scans of the carotid and vertebral arteries and CT scan of the head on the day of the event were normal. RPR, ESR, TSH, proteins C, S, antithrombin 3 and all anticardiolipin antibodies were normal.
2. *MRI*, 4 days after onset (Fig.26-18) :small area of increased signal in the right occipital lobe in region of the visual cortex consistent with an infarct in distribution of the calcarine artery.
3. *MRA* (Fig.26-19): decreased flow in the distal right posterior cerebral artery probable embolic occlusion with filling of distal branches by anastomotic flow.
4. *Holter monitoring* demonstrated multiple brief episodes of paroxysmal atrial fibrillation.
5. The routine *transthoracic echocardiogram* demonstrated no clear cut abnormalities. However the *transesophageal echocardiogram* demonstrated a definite patent foramen ovale with right to left shunting.

Subsequent course: Reevaluation of the patient 22 hours after the onset of symptoms demonstrated clearing of all neurologic findings. When seen 2 weeks after the event her only complaint related to some problems in reading. This patient already been receiving aspirin at the time of the event and this was discontinued. She was begun on lifelong systemic anticoagulation with coumadin by the consultant cardiologist Dr. Filiberti since she had two conditions associated with embolization: paroxysmal atrial fibrillation and patent foramen ovale with right to left shunting. The patient did well over the subsequent 5 years.

Comment: When initially evaluated, the posterior cerebral artery location was clear but the pathophysiology was not. The subsequent imaging studies clearly indicated a small infarct involving the calcarine artery territory. Whether the previous sensory findings indicated some involvement of the posterior cerebral penetrating supply to the ventral posterior lateral nucleus of the thalamus remains unclear. The decreased flow in the right posterior cerebral artery was clearly demonstrated. In general as with the middle cerebral artery, cortical infarcts of the posterior cerebral artery territory, in the Caucasian population are almost always embolic. In this case the patient had two possible sources for emboli and was placed on long term anticoagulation.

The following case 26-6 presented at the onset with a transient bilateral posterior cerebral ischemia but with more severe residual symptoms reflecting unilateral posterior cerebral disease.

Case 26-6. This 75-year-old, white, right-handed widow developed sudden headache on the day prior to admission, with nausea, vomiting, and a poorly described bilateral disturbance of vision. She was found by a relative the morning of admission complaining of total blindness and of severe headache. She was noted to be confused and incoherent (believed she was in New Jersey rather than Massachusetts). She was able to walk only with assistance.

Past history: A minor degree of hypertension had been noted several days prior to admission.

Physical examination: The patient was an obese female with blood pressure elevated to 170/100. She was holding her head complaining of headache.

Neurological examination:

1. Mental status:
 - a. The patient was restless and disoriented for time and place.
 - b. There were difficulties in cooperation so that detailed testing of mental status could not be performed.
 - c. Simple calculations were poorly performed.
 - d. Digit span was markedly limited.
 - e. There was no left-right confusion and no evidence of aphasia.
2. Cranial nerves:
 - a. Initially the patient was unable to detect objects (e.g., a face or lights) in either visual field. Within six hours, a change had occurred. Although conjugate extraocular movements were full, the patient tended to keep her eye deviated to the right and failed to follow objects introduced from the periphery of the left visual field. The eyes could be deviated to the left on command.
 - b. The pupils responded to light.
3. Motor system:
 - a. Strength was grossly intact.

- b. A slight unsteadiness (ataxia) of gait was present.
- 4. Reflexes:
 - a. Deep tendon reflexes were grossly symmetrical.
 - b. A Babinski response was present on the left; a probable Babinski sign was also present on the right.
- 5. *Sensory system*: All modalities were intact.

Clinical diagnosis: Ischemia bilateral posterior cerebral arteries, cortical branches, probably embolic.

Laboratory data:

1. *Hematocrit* was normal. *Total cholesterol* was elevated to 312 mg./100 ml. The *glucose tolerance test* was consistent with diabetes mellitus.
2. Chest and skull x-rays and the electrocardiogram were normal.
3. The *electroencephalogram* demonstrated focal 3 to 4 cps slow waves in the right posterior parietal occipital area with rare slow waves in the right posterior temporal area consistent with focal damage in this area.
4. *Lumbar puncture* indicated clear spinal fluid with no cells and a normal protein of 18 mg./ml.

Hospital course: The patient had a significant improvement in headache and a clearing of confusion with a return of mental status to her normal level. Her hospital stay was prolonged by the development of thrombophlebitis of the left femoral vein. At the time of hospital discharge, one month after admission, there was still a residual left field defect (homonymous hemianopsia) with preservation of vision in the macular area (macular sparing). Follow-up evaluation approximately 14 months after discharge indicated no significant neurological findings except for the residual left field defect (homonymous hemianopsia with macular sparing) (Fig. 23-16).

Comment: The initial symptom of total blindness suggested bilateral posterior cerebral ischemia. The development of confusion and disorientation is also consistent with bilateral posterior cerebral ischemia. The nausea, vomiting, and minor ataxia of gait may well have indicated ischemia of the brain stem, suggesting that the basic occlusive process may have originated at a lower point in the basilar artery. The residual and most severe degree of involvement was certainly within the territory of the right calcarine artery.

The occurrence of severe headache is not usually considered in connection with ischemic-occlusive disease. A review of our cases of posterior cerebral occlusion indicates that the occurrence of severe headache is often a prominent symptom. Often in these cases prior to lumbar puncture, the diagnosis of subarachnoid hemorrhage was considered.

At the present time evaluation would include a CT or MRI scan. Other examples of posterior cerebral artery cortical infarcts are presented in the visual system chapter with appropriate CT scans.

The following case 26-7 provides an example of an intracerebral hematoma of unknown etiology in a young patient.

Case History 26-7. This 33-year-old white, right-handed, male linotype operator, at approximately 8:30 p.m. had the sudden onset of numbness of the left side of his mouth. At 10:30 p.m. he developed a severe right frontal headache and noted sudden onset of numbness of the left upper extremity which rapidly spread to involve the entire left side. Marked weakness of the left arm and leg developed. Evaluation that evening at his local community hospital indicated a dense left homonymous hemianopia, a marked left central facial weakness, an absence of any voluntary movement of the left arm and leg and no awareness of painful stimulation of the entire left side. A left Babinski sign was present. Lumbar puncture revealed opening pressure elevated to 235 mm. of water; and 50 fresh red blood cells per cubic mm. The patient was subsequently transferred to the neurosurgical service at New England Center Hospital.

Past history: There were no remarkable features as regards hypertension, renal disease, or diabetes mellitus. No history of drug use was obtained.

Physical examination: The patient was moderately obese with a normal blood pressure of 110/85. Examination of the heart revealed no abnormalities. No rigidity of the neck was present. There were no murmurs over the cranium.

Neurological examination:

1. **Mental status:** Orientation, speech and the ability to provide a coherent history were all intact.
 2. **Cranial nerves:**
 - a. Examination of the fundi showed no hemorrhage or papilledema.
 - b. A dense left homonymous hemianopsia was present.
 - c. Sensation was defective on the left side of the face, as well as the left side of the body.
 - d. A left central facial weakness was present.
 - e. The tongue deviated to the left.
 3. **Motor system:**
 - a. A dense flaccid paralysis of the left arm and leg was present.
 - b. There was no resistance to passive motion in the left arm and leg. and little in the left lower extremity (that is, a flaccid paralysis was present).
 - c. Cerebellar tests were negative.
 4. **Reflexes:**
 - a. Deep tendon reflexes were absent in the left upper extremity but increased in the left lower extremity
 - b. A Babinski sign was present on the left. The plantar on the right was flexor.
 - c. No grasp reflexes were present.
 5. **Sensation:**
 - a. There was no perception of pinprick or of tactile stimulus on the entire left side of the body.
 - b. Position and vibratory sensation were absent on the on the left.
- Clinical diagnosis:** Intracerebral hematoma right putamen-thalamus or embolus stem of MCA with hemorrhagic transformation.

Laboratory data:

1. Hematocrit, white blood count, and differential were all within normal limits. Sedimentation rate was normal.
2. *Tests of bleeding time, clotting time, and prothrombin time* were all within normal limits.
4. *Skull x-rays* revealed a shift of the pineal, 7 mm. from right to left.
5. *Electroencephalogram* revealed frequent focal 4 to 5 cps slow waves in the right hemisphere most prominent in the frontal and parietal areas consistent with focal damage in these areas.
6. *Arteriograms* (right common carotid) revealed a 12 mm. shift of the pericallosal branch of the anterior cerebral artery. The internal cerebral vein was also shifted 8 mm. from right to left. The middle cerebral branches emerging through the sylvian fissure were depressed. There was no evidence of an abnormal arteriovenous shunt or of an aneurysm. Cortical vessels and veins in the suprasylvian area were stretched over relatively avascular areas. The conclusion was a space-occupying mass in the right posterior frontal parietal area consistent with an intracerebral hematoma.

Subsequent course:

On the day of admission, the patient was taken to the operating room. A right parietal burr hole was made. The underlying cortex was noted by the neurosurgeon, Dr. Robert Yuan, to bulge prominently. A needle was inserted to a depth of 1 cm. into the cortex where 25 cc. of old, dark red blood under pressure was expelled. Free drainage of blood continued through a catheter which remained in place for 2 days.

Return of voluntary movement in the left lower extremity at the hip and knee was noted on the day following surgery. Reevaluation of neurological status 2 weeks after surgery, revealed continued improvement. The left homonymous hemianopsia was no longer present but the patient did have some difficulty in reading (losing the left half of the line of print). A left central facial weakness was present; voluntary hand-foot movements on the left were still not possible. Proximal muscle groups (shoulder, hip, knee) had returned to 60 per cent of normal strength. Deep tendon reflexes were now hyperactive in the upper and lower left extremities with a left Babinski sign. A dense

sensory deficit remained on the left side with no perception of pain, touch, vibration, and position in the upper and lower extremities. Reevaluation 4 weeks after surgery, revealed a return of pain and temperature sensation but continued deficits in proprioception. Reevaluation by Dr. Yuan 4 months after surgery, indicated a return of strength in the left hand with a strong grip. The gait was typical of a spastic hemiplegia. Reflexes were unchanged. Sensory examination revealed a return of primary modalities such as vibration and pain, but marked errors in cortical modalities, such as position sense, were made. Follow-up 7 months after surgery indicated an excellent return of strength on the left side but continued incoordination in the left hand due to deficits in proprioception.

Comment:

This patient from several standpoints presents a number of unusual features not seen in the typical case of intracerebral hemorrhage. The patient was relatively young (33 years old) and had no history of hypertension. He had none of those conditions such as leukemia, bleeding disorders, and the like which predispose to intracerebral hemorrhage. The arteriogram provided no evidence of an intrinsic or a secondary metastatic brain tumor. Moreover, histological examination of the tissue and drainage material obtained at the time of surgery failed to reveal tumor cells. No aneurysm was demonstrated on angiography. Although no arteriovenous malformation was demonstrated at the time of arteriography, such a malformation may have been present previously but destroyed in the process of hemorrhage. The significance of the minor prodromal sensation of numbness of the face remains uncertain. This may have reflected an initial small area of ischemia with secondary hemorrhage.

Where was the initial site of hemorrhage? In this case, the hemorrhage apparently originated in the subcortical white matter of the parietal lobe presenting as a lobar hemorrhage. The pattern of initial evolution of symptoms and the final pattern of sensory deficit is perhaps more consistent with such a parietal lobe location. From the prognostic standpoint, he did not lapse into coma and did not have compromise of brain stem functions as so often occurs when there is tentorial herniation or an extension of the hemorrhage into the ventricular system. That these various events did not occur, may in part relate to the drainage of the hematoma by the neurosurgeon with removal of this supratentorial mass lesion. The management of intracerebral hemorrhages is discussed in greater detail by Ojemann and Heros, (1983).

The following three cases provide examples of subarachnoid hemorrhage from aneurysms at the three major sites: posterior communicating-internal carotid (Case 26-8), middle cerebral bifurcation (Case 26-9) and anterior communicating –anterior cerebral junction (Case 26-10)

Posterior communicating- internal carotid junction.(Figs. 26-24)

Case 26-8: This 66-year-old white housewife, five days prior to admission, had the sudden onset of a severe bicipital bifrontal headache associated with vomiting. The headache was constantly present for 3 days but was increased by coughing. At the same time, she noted an alteration of vision in the right eye. She noted also a drooping of the right eyelid. The headache subsided, only to recur one night prior to admission as a severe occipital headache associated with vomiting. There was no past history of hypertension. The patient was admitted to her community hospital. A lumbar puncture revealed the presence of subarachnoid blood and the patient was transferred to the neurology/neurosurgical services of the New England Medical Center on 10/2/66.

General physical examination: The patient was an obese female with blood pressure of 140/80 and complaints of severe headache. Her temperature was normal.

Neurological examination:

1. *Mental status:* The patient was alert with mental status intact.
2. Cranial nerves:
 - a. Fundus: Blurred discs were present bilaterally, being greater on the right. No venous pulsations were present on the right.
 - b. Nerve III: The right pupil measured 4 mm. and was not reactive to light on direct or consensual stimulation.. The left pupil measured 2mm and was reactive to light. Ptosis of the right eyelid was present. At rest on forward gaze, there was outward deviation of the right eye. The patient was unable to adduct the right eye on left lateral gaze and failed to move this eye on upward or downward gaze. Other extraocular movements were intact.

c. Nerve VII: Minimal flattening of the right nasal labial fold was present.

3. *Motor system*: Strength, coordination, and gait were intact.
 4. *Reflexes*: Deep tendon: A minimal relative increase was present on the right. Plantar responses: The left was flexor, the right was equivocal.
 5. *Sensation*: All modalities were intact.
 6. *Neck*: Mild nuchal rigidity was present (resistant to passive flexion of head onto chest).
- Clinical diagnosis**: Subarachnoid hemorrhage due to an aneurysm at the posterior communicating–internal carotid junction.

Laboratory data:

1. Skull and chest x-rays were normal.
2. Studies of bleeding time, clotting time, and prothrombin time were all within normal limits.
3. *Arteriograms* revealed an aneurysm of the right internal carotid artery just below its junction with the posterior communicating artery. There was no left-to-right flow through the anterior communicating artery. There was narrowing of the anterior cerebral arteries near their origin bilaterally. This suggested to the radiologist the possibility of vasospasm, secondary to the presence of subarachnoid blood.

Hospital course:

Because the history suggested several episodes of bleeding, surgical therapy was selected. A right temporal craniotomy was performed by Dr. Robert Yuan with clipping of the neck of the aneurysm. The temporal lobe was retracted revealing a 13 mm.-long saccular aneurysm, arising from the internal carotid artery close to the junction with the posterior communicating artery. Distally the aneurysm enlarged into a large sac which was hidden behind the oculomotor nerve. This nerve was bulging at the point where the aneurysm, which was clipped, was well formed. The more distal sac of the aneurysm was thin and showed signs of previous rupture with yellow staining of the adjacent meninges. The sac of the aneurysm was covered with Gelfoam. Postoperatively, significant deficits as compared to the preoperative neurological status were evident. The level of consciousness waxed and waned with periods of alertness alternating with periods of apathy and drowsiness. Twenty days after surgery, she was described as sitting with both eyes closed, continuously grasping and palpating the arm of the chair with the right hand, less frequently with the left. There was a marked bilateral release of an instinctive grasp reflex. There was increased resistance in both upper extremities, at times described as plastic rigidity, at times as the “Gegenhalten,” associated with bilateral frontal lobe disease. No spontaneous voluntary movements of the left leg occurred. Bilateral Babinski signs were present. A bilateral resting tremor of the hands and of the head was also present. At times inappropriate jocularity was present. All of these findings suggested a bilateral front lobe syndrome with infarction in the territory of the anterior cerebral arteries and additional involvement of the basal ganglia. The complete paralysis of the right third nerve remained at preoperative level. At the time of hospital discharge, one month after surgery, the frontal lobe findings and the weakness in the left leg remained prominent.

Comment:

The presence of severe headache in association with a mild degree of nuchal rigidity suggests meningeal irritation. Such irritation could indicate a subarachnoid hemorrhage or a meningitis (inflammation of the meninges due to bacterial or viral infection). The sudden onset of the headache is more consistent with a subarachnoid hemorrhage. The lack of fever and of accompanying or prodromal systemic findings is also against the diagnosis of meningitis. Finally, the clearly focal third nerve findings are more in favor of the diagnosis of subarachnoid hemorrhage (although focal or multifocal neurological findings may develop as complications of a bacterial meningitis).

In this case, the significant findings on neurological examination related to the right third cranial nerve. The third cranial nerve is particularly subject to compression by aneurysms of the posterior communicating artery because having emerged from the midbrain it pursues an anterior course towards the cavernous sinus in a close parallel relationship to the posterior communicating artery. In general, compressive lesions of the third nerve produce initially an alteration in pupillary constrictor functions, then involvement of the levator palpebrae and finally involvement of the superior, medial and inferior

rectus, and inferior oblique muscles. The initial alteration in vision in the right eye and ptosis of the right eyelid at the onset of headache are then consistent with a compressive lesion. The patient at the onset of symptoms did not report a diplopia.

The third nerve as it emerges from the midbrain also passes in close relationship to the posterior cerebral and superior cerebellar arteries, but aneurysms of these vessels are much less common than those which occur in relation to the posterior communicating artery and internal carotid artery.

These findings with extrinsic compressive disease of the third nerve are to be contrasted with the pattern of intrinsic brain stem involvement of the third nerve nucleus where medial rectus or superior rectus function is more likely to be initially compromised.

The patient had minimal findings suggesting involvement of the left corticospinal and corticobulbar tracts: minimal right central facial weakness, minimal increase in deep tendon reflexes on the right side, and an equivocal right plantar response. The findings may have been produced by a slight shift of the brain stem to the left due to the small mass of aneurysm on the right side of brain stem. With such a shift, compression of the left cerebral peduncle against the tentorium might occur. In any case, these findings were minimal. The significant findings in this case clearly related to the third cranial nerve and it is these findings which allowed localization of the lesion prior to arteriography.

As regards the postoperative course, it is evident that this patient had severe involvement of the frontal lobes presumably as a result of bilateral infarction within the territory of the anterior cerebral arteries. In retrospect, the narrowing of the anterior cerebral arteries at their origin, presumed secondary to "spasm" noted at the time of arteriography, may have provided a clue as to the development of the complication. The neurosurgeon, faced with the decision as to the best time to intervene, would prefer as the ideal situation, the moment when arterial spasm has not yet developed or is no longer present but bleeding has not yet recurred. In reality the risk of recurrent hemorrhage is so great that the aneurysm should be clipped as soon as possible for example the day of presentation. Vasospasm can now be treated with calcium channel blockers and after clipping by increasing the blood pressure to increase perfusion. The typical angiographic appearance of aneurysms in this location is demonstrated in Figure 26-24. Occasionally large aneurysms can be demonstrated on the CT scan.

Middle cerebral bifurcation (Fig 26-25).

Case 26-9: This 46-year-old, right-handed, white, married male, was admitted to the neurology/neurosurgical services of the New England Medical Center on 6/10/66. He presented a history that 10 days prior to admission, he had the sudden onset of a severe, throbbing, supraorbital and vertex headache. The headache began while the patient was in bed in the early stages of sexual intercourse. The patient noted no weakness except that his tongue "felt funny" in articulation for approximately one minute. There was a transient difficulty in speech during this period.

Past history: Mild hypertension had been present.

General physical examination: Blood pressure was 160/100.

Neurological examination:

1. *Mental status* was intact.
2. *Cranial nerves* were intact.
3. *Motor system* was intact.
4. *Reflexes* were physiologic
5. *Sensory system* was intact.
6. Headache could be precipitated by *head movement*.
7. With *cervical flexion*, pain occurred in the neck and lumbar area occurred.

Laboratory data:

1. Skull and chest x-rays were normal.
2. *Electroencephalogram* revealed focal damage in the lateral aspect of the left hemisphere (focal 3 to 5 cps slow waves).
3. *Lumbar puncture* on the day following admission revealed opening pressure elevated to 270 mm. of water and closing pressure to 210 mm. of csf. The fluid was xanthochromic (yellow discoloration). In addition 38 fresh red blood cells per cubic mm. were present. Protein was elevated to 80 mg./100 ml. Hinton was negative.

4. *Arteriography* revealed a bilobed aneurysm at the trifurcation of the left middle cerebral artery measuring 8 x 4 mm. Spasm and narrowing of the proximal anterior and middle cerebral arteries were noted.

Hospital course:

On the day following admission, the patient complained of a few-minute episodes of numbness in the right face, tongue, and right upper extremity with thickness of speech. Examination now revealed right central facial weakness and slight slurring of speech. The patient also now complained of additional neck pain on extreme forward flexion. On June 12, 1966, the patient had another short episode beginning with numbness over the right thumb, spreading to the right hand and then to the angle of the mouth.

Because of the several episodes which occurred, following hospital admission, involving the right face, tongue, and hand in association with the finding of fresh red blood cells in the spinal fluid, it was considered likely that bleeding from the aneurysm was continuing to occur. Surgical therapy was therefore considered necessary to prevent additional (and possibly fatal) subarachnoid hemorrhage. On May 20, 1966 a left frontotemporal craniotomy was performed by Dr. Robert Yuan with subsequent plastic coating of the entire aneurysm to reinforce its wall. There was evidence of recent hemorrhage in the subarachnoid space with yellow discoloration of the meninges. In order to expose the aneurysm, it was necessary to remove the anterior tip of the temporal lobe back to a distance of 2.5 cm. There was a small amount (5 to 10 cc.) of intracerebral blood clot in the superior temporal region close to the aneurysm. The aneurysm itself had no actual neck that could be clipped. Several middle cerebral branches appeared to arise from the dome or lateral wall of the aneurysm.

In the postoperative period, the patient initially did well. A minor expressive aphasia was present, but the patient was alert and well oriented. However, fever and jaundice developed. With the development of significant alterations of liver functions approximately 7 days after surgery, the patient became confused and agitated. The prothrombin time fell to 3 per cent of normal and there was evidence of bleeding into the gastrointestinal tract at this time. The prothrombin deficit was corrected by administration of vitamin K. It was unclear, however, as to whether any minor intracranial bleeding occurred during this time. Some improvement in liver functions occurred, and the patient became more alert but continued to manifest inappropriate behavior, emotional lability, and disturbance of memory. He left the hospital against medical advice one month after surgery, on July 20, 1966.

The patient was readmitted to the hospital approximately one month later on August 13, 1966. For two days, the patient had been less active, appeared confused, glassy eyed, and failed to communicate. The degree of obtundation cleared when adequate dosage of the anticonvulsant medication, Dilantin, was administered. This fact taken on conjunction with the electroencephalogram, which demonstrated frequent focal spikes (excessive neuronal discharge) in the left temporal area (Fig. 29-1C) led to the conclusion that the episode which precipitated his readmission might well have represented a prolonged seizure discharge. The electroencephalogram also demonstrated an increase in slow wave activity in the left hemisphere, particularly the left temporal area indicating a possible increase in damage in the left temporal area. This appeared to be correlated with apparent progression of the patient's aphasia which was now receptive as well as expressive in nature. At the time of discharge, a severe expressive aphasia was still present.

Comment:

The sudden onset of severe headache during exercise or exertion (sexual intercourse in this case) is characteristic of subarachnoid hemorrhage. The location of the aneurysm was suggested by the symptoms relevant to the tongue and speech during the initial episode. The episode on June 11, 1966, involving numbness of the right face, tongue, and right upper extremity, could only indicate disease within the territory of the left middle cerebral artery. The lumbar puncture at this time indicated not only evidence of the initial leakage of blood 10 days prior to admission (an elevation of cerebrospinal fluid protein and a xanthochromia), but also fresh red blood cells suggesting that additional leakage of blood had occurred.

The nature of the episodes which occurred on June 11 and 12 is not certain. Most likely these were ischemic in nature related to decrease in blood flow as a result of clot formation within the aneurysm or from spasm of the adjacent portion of the middle cerebral artery. At times, however, symptoms such as rapidly spreading numbness occurring in episodes may suggest focal epileptic discharge. The development of an area of excessive discharge would not be unusual since this aneurysm involves those

middle cerebral artery branches which are supplying the cerebral cortex. In addition hemorrhage within the Sylvian fissure is likely to damage the surrounding cerebral cortex. Blood and iron are epileptogenic.

The patient's course following surgery was complicated by the development of severe liver dysfunction. The etiology of this problem was never clear, the various studies suggesting either a toxic hepatitis related to various drugs and anesthetic agents or a variety of obstructive jaundice. What the patient's eventual recovery would have been had this problem not developed is uncertain. It is clear, however, that during this post-

operative period the patient did develop significant impairment of language functions, possibly related to infarction or oozing of blood in areas supplied by the middle cerebral artery. It is also evident that a seizure focus had developed in this area. Such seizure foci may have developed in relation to the preoperative hematoma noted in the temporal lobe, in relation to the surgical manipulation of the area, or in relation to the postoperative complications.

Today (2002), the history presented by this patient would have prompted an immediate CT scan and a lumbar puncture if the CT scan were negative. An arteriogram would have been performed immediately after these studies. Surgery would have been performed immediately after the evaluation of the angiographic studies to prevent the recurrent episodes of bleeding.

Anterior communicating -anterior cerebral junction(Figs. 24-26, 24-27, 24-28)

Case History 26-10. . (Patient of Dr. John Sullivan). This 49-year-old, right-handed truck driver was transferred from his local community hospital for evaluation of subarachnoid hemorrhage.

The patient had experienced occasional frontal headaches for the previous 5 years. In June, 1965, while changing a tire, he had a severe throbbing frontal headache which cleared after thirty minutes. Since that time he had experienced daily throbbing frontal headaches, usually present on arising in the morning. On September 4, 1965, the patient had the onset of a particularly severe headache which began while he was engaged in heavy work on a boat. There was associated stiffness of the neck, nausea, vomiting, and a general sensation of weakness.

Evaluation at his local community hospital revealed papilledema (blurred optic disk margins on funduscopic examination). Nuchal rigidity was present. The lumbar puncture demonstrated grossly bloody cerebrospinal fluid. He was subsequently transferred to the neurology/neurosurgical services of the New England Medical Center on 9/7/65.

Past history:

1. Hypertension had been noted in June, 1965.
2. The patient's father had died at age 59 of a cerebrovascular accident.

General physical examination:

1. Blood pressure was moderately elevated to 180/100. Pulse was 60.
2. No bruits (murmurs) were present over the skull.
3. A significant degree of nuchal rigidity was present. The neck could not be actively or passively flexed.

Neurological examination:

1. Mental status:
 - a. The patient was somnolent but could be aroused, although attention span was noted to be shortened.
 - b. He was oriented for place and situation but confused as to time.
 - c. Digit span was shortened to 5 forward and 4 in reverse.
 - d. The patient was unable to do calculations.
2. Cranial nerves:
 - a. Sense of smell was decreased on the right side.
 - b. Disk margins were indistinct on examination of the fundus. Arterioles were tortuous and irregular.
3. Motor system:
 - a. Strength and tone were intact.
 - b. Cerebellar tests were normal.
4. Reflexes:
 - a. Deep tendon reflexes were symmetrical.

- b. Plantar responses were flexor.
- 5. Sensory system: All modalities were intact.

Laboratory data:

1. Bleeding, clotting, and prothrombin times were all normal. Platelets were normal on smear.
2. Chest and skull x-rays were normal.
3. *Arteriograms* demonstrated an aneurysm of the anterior communicating artery which extended posteriorly and to the right. The aneurysm filled from the left carotid circulation.

Hospital course: During the evening of September 11, 1965, the patient became lethargic and would not speak or obey commands. Blood pressure rose to 240 mm. systolic. The patient became totally unresponsive with pupils fixed and dilated and with incontinence of urine. Deep tendon reflexes were exaggerated with plantar responses extensor. Within minutes, the patient became responsive again; pupils were reactive, although the right remained sluggish. The patient made purposive movements and obeyed commands. Lumbar puncture subsequently indicated grossly bloody spinal fluid. The patient remained confused and less alert with a tendency to fall asleep.

On September 17, 1965, the patient again suddenly complained of violent headache and lost consciousness for approximately 30 minutes. The right pupil became dilated, and the right eye deviated to the right suggesting a right medial rectus weakness. The blood pressure again rose to 240/140. As previously, the patient regained consciousness. Although confused, he had no clearly lateralizing signs. Subsequent lumbar puncture again revealed the presence of fresh red blood cells.

Because repeated episodes of bleeding had occurred, surgical therapy was undertaken. On September 21, 1965 a left frontal craniotomy was performed by Dr. Robert Yuan. The left frontal pole was resected exposing the left anterior cerebral artery and the aneurysm which arose from the anterior communicating artery. The medial surface of the right frontal lobe was cystic and contained 20 cc. of hematoma. The hematoma was evacuated. The aneurysm was reinforced by spraying with a plastic coating.

Neurological examination approximately 1 week after surgery indicated that the patient was confused and disoriented, with a "rather negative response" refusing to follow directions and to speak to examiners. Blood pressure was noted to be extremely labile with a drop of 50 mm. of mercury systolic when the patient moved from prone to sitting position. Equivocal Babinski signs were present, and the patient was incontinent of urine and feces.

Reevaluation on November 17, 1965, approximately two months after surgery, indicated that although the patient was ambulatory and able to take care of his daily needs, he remained confused for time and place. When the patient was examined 6 months after surgery, confusion was no longer present; intellectual functions were consistent with his education.

Approximately 2 years after surgery, the patient, who had recently been married, reported that he was impotent, unable to obtain an erection.

Comment:

In this case, the history of sudden onset of severe headache and stiffness of the neck, precipitated by exertion, clearly suggested a subarachnoid hemorrhage originating from the rupture of an intracranial aneurysm. It is likely that several episodes of subarachnoid bleeding occurred in June and September of 1965. While the clinical findings of somnolence and confusion with a decrease in olfaction on the right may have suggested the possibility of an anterior communicating-artery location, these were certainly not firm diagnostic clues. The episodes characterized by sudden alteration in blood pressure, while nonspecific, might have raised the question of orbital-frontal, anterior cingulate, or hypothalamic effects (areas within the distribution of the anterior-cerebral arteries).

The negativity of the patient following surgery undoubtedly indicated preoperative and operative damage to the orbital and prefrontal areas. The bilateral Babinski signs and the incontinence of urine and feces in the postoperative period probably reflected damage to the parasagittal motor and premotor areas within the distribution of the anterior cerebral arteries. The impotence may have reflected damage at the frontal or hypothalamic level.

Today, an initial episode such as occurred in June 1965 would have prompted a CT scan and a lumbar puncture if that study had been negative. Of course many exertional headaches are not a result of

subarachnoid hemorrhage. Nevertheless the more serious entity must be ruled out at the emergency room level, since the mortality and morbidity of the frequent recurrent hemorrhage are so high. Again the use of early arteriography and early surgery are to be emphasized.

Case 26-11 illustrates many of the neurologic aspects of bacterial endocarditis.

Case 26-11: This 34-year old right hand married white male hair dresser was admitted with a one month history of night sweats, fever to 102-103° F., generalized aches and pains. Within the previous 3-4 months, the patient had undergone repeated dental procedures for dental infection. He had been reported to have a mild heart murmur 2-3 years prior to admission. His urine had recently become dark. The day prior to admission he had noted a small hemorrhagic lesion on the dorsum of his left hand.

Physical exam:

1) Skin: A small indurated red lesion dorsum left hand and a small red lesion under the nail bed 3rd left toe.

2) Heart: A grade IV/VI high-pitched holosystolic murmur was present at the apex; and a high-pitched II/VI murmur at the base; both not previously noted to this degree.

3) Temperature was elevated to 101° F

Neurological examination: Entirely within normal limits.

Clinical diagnosis: Bacterial endocarditis with systemic emboli but without neurological symptoms at this point.

Laboratory data:

1) **CBC:** Anemia with hematocrit 31 and hemoglobin of 10.1.
White blood count was 9900 with differential of 78% poly-morphonuclears and 9 atypical lymphocytes.

2) Sedimentation rate was elevated to 38 mm.

3) **Urinalysis** indicated 8-10 red blood cells per high power field.

4) All three **blood cultures** drawn on the day of admission produced growth of streptococcus viridans (alpha hemolytic).

5) **Echocardiogram** indicated a prolapsed mitral valve with probable mitral insufficiency. In addition, irregular densities on the mitral leaflets suggested vegetations.

Hospital course: All of these findings were consistent with a diagnosis of subacute bacterial endocarditis with evidence of microemboli to extremities (skin lesions) and to kidneys (hematuria). The patient was begun on high dosage intravenous penicillin (24 million units per day) with an excellent response as regards fever and general symptoms. Thirteen days after admission he again developed a temperature elevation. The following day, at 2 p.m., he abruptly developed difficulty with speech and a right hemiplegia. Over the next 2 hours this rapidly evolved to the following neurological state.

Neurological examination:

1) Mental Status and Language Function

a) The patient was drowsy - holding the left side of his head as though in pain.

b) He was mute.

c) He was unable to carry out any spoken or written commands.

2) Cranial Nerves

a) The patient neglected the right visual field and had no response to threat in the field.

b) The fundusoscopic exam indicated blurring of the disc margins on the left.

c) Right central facial weakness was present.

d) Pain sensation was decreased on the right side of the face.

3) **Motor System:** A flaccid right hemiparesis was present although some purposive withdrawal of the right arm and leg occurred on painful stimulation.

4) Reflexes

a) Deep tendon reflexes were increased bilaterally but right were greater than left with clonus of the right ankle.

- b) The right plantar response was extensor, the left flexor.
 - 5) *Sensation*: A right-sided hypalgesia was present. Other modalities could not be tested.
 - 6) Neck and Skin
 - a) No nuchal rigidity was present.
 - b) New splinter hemorrhages were present under the nails of the upper extremities.
- Neurological diagnosis:** Cerebral embolus left middle cerebral artery, with possible mycotic aneurysm and possible hematoma left middle cerebral artery secondary to bacterial endocarditis.

Laboratory data:

An immediate CT Scan (Fig. 26-30) demonstrated a large intracerebral hematoma involving the left basal ganglia and insula with massive shift of the left hemisphere to the right.

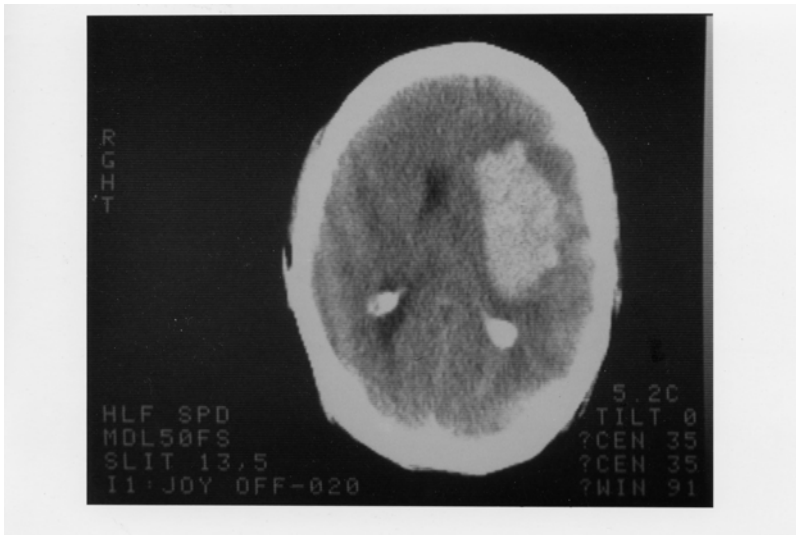
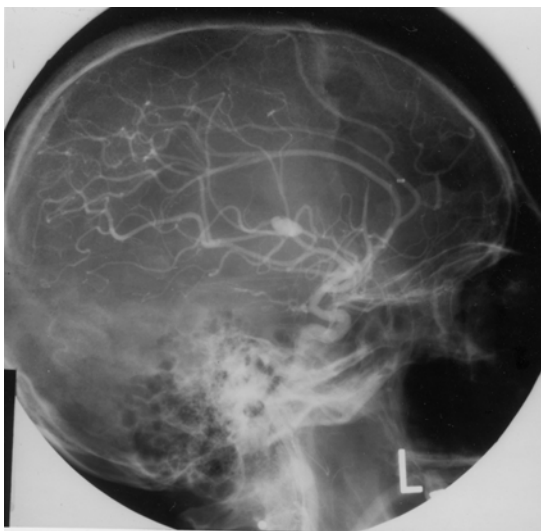


Figure 26-30.

2. An immediate arteriogram: (Fig. 26-31A) demonstrated a small aneurysm (arrow) arising from a small branch of the left middle cerebral artery (MCA) within the Sylvian fissure. A large avascular area surrounded this aneurysm with upward and lateral displacement of anterior cerebral arteries, medial displacement of lenticular striate, branches of the MCA and lateral and downward placement of the cortical MCA branches.



Subsequent course: That evening Dr. Robert Johnson removed a large intracerebral clot. Over the next 2 weeks the patient began to have some improvement in his right hemiparesis and aphasia. However two weeks after surgery, he developed right-sided focal status epilepticus. The patient had been receiving Phenytoin (Dilantin) but the level was low. Intravenous Phenytoin, intravenous Dexamethasone and Mannitol were administered. The CT scan now demonstrated a larger hemorrhage surrounded by edema. The patient was taken to surgery and additional old clot and a small amount of recent clots were removed. The patient failed to respond. He developed fixed dilated pupils and bilateral Babinski signs. The arteriogram (Fig.26-31 B,C) was repeated and now demonstrated a much larger aneurysm (measuring 11 mm vs 4-5 mm in previous films). There was also evidence of additional shifts of the anterior cerebral artery and internal cerebral vein. Anterior-frontal branches of the middle cerebral artery were occluded. Regression occurred and 8 days later patient met brain death criteria with absence of all brainstem reflexes, no spontaneous respirations and an absence of all cerebral electrical activity (silent EEG).

Comment: This patient presents a panorama of almost all of the cerebral complications of bacterial endocarditis including:

- a) Multiple septic emboli to brain, kidney, and small peripheral arteries;
- b) Mycotic aneurysm;
- c) Intracerebral hematoma
- d) Eventual mortality.

The mycotic aneurysm with eventual rupture was not a feature noted on presentation but instead was a late complication. (A silent unruptured aneurysm may well have been present on admission.) This subacute delayed presentation is more common in streptococcal endocarditis as opposed to the more virulent staphylococcal infections where acute intracranial presentations are the rule.

In this case, the aneurysm when initially discovered was small and associated with an intracerebral hemorrhage.

The aneurysm continued to enlarge after evacuation of the initial hematoma and eventually additional hemorrhage occurred. Not all patients with mycotic aneurysm will have intracranial hemorrhage. In the series of Brust et al (1990), 41% were associated with rupture. Of 20 aneurysms followed with angiography or CT scan, ten became smaller or disappeared, 10 remained unchanged or enlarged despite an adequate treatment course with antibiotics. In the present case, initial rupture occurred almost 2 weeks after admission and beginning of antibiotic treatment.

The recommended approach in patients with endocarditis to avoid the fatal complications of mycotic aneurysm rupture is to perform 4 vessel angiography in those patients with endocarditis who develop neurological symptoms. If a mycotic aneurysm is found, prompt surgical treatment (clipping) should be performed. Unfortunately many patients with mycotic aneurysms have no neurological symptoms prior to rupture. To perform angiography in all patients with bacterial endocarditis, would not be practical and would fail to detect aneurysms that developed after the studies. However, when long-term anticoagulation is planned in patients on the completion of antibiotic treatment to prevent additional emboli, angiography should be performed or repeated. The entire role of anticoagulation in bacterial endocarditis remains unclear. (See Salgade et.al 1987 and Hart et.al 1987, 1990). MRI may have an increasing role in non-invasive diagnosis, since MRI angiography should be able to detect aneurysms greater than 2-3 mm in diameter

Figure 26-32. Arteriovenous malformation in the right parietal area demonstrating the abnormal tangle of vessels and infarction of the surrounding cerebral cortex and white matter.

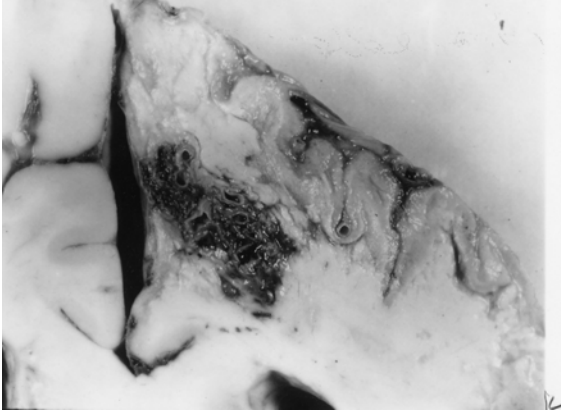


Figure 26-32. In this case, the malformation was fed mainly by the right anterior cerebral artery and drained into the superior sagittal sinus. This 46-year-old woman had, as a primary problem, subarachnoid hemorrhage from an anterior-communicating saccular aneurysm, with other unruptured aneurysms at left posterior communicating, and right superior cerebellar. (Courtesy of Dr. John Hills).

Case history 26-12 provides an example of a long-term unruptured arteriovenous malformation presenting as a seizure disorder.

Case 26-12: This 51-year old right-handed female experienced two nocturnal generalized convulsive seizures 6 years prior to evaluation . Evaluation by Dr. Robert Bazemore at that time revealed a significant 30-year history of minor episodes: “little sensations”. The patient described sudden strange feelings as though moving in slow motion. With other episodes she would feel at a distance from her surroundings with a sense of detachment at times with a strange odd smell. After 2-3 minutes the “spell” would alter, she would feel depressed with a sense of terrible fear. The patient also had a long history of migraine headaches (bilateral throbbing) which were often preceded by visual auras more prominent in the right visual field. The neurological examination was normal. She was treated with anticonvulsant (Phenytoin). When seen by the author for other unrelated neurological problems 6 years later , the interval history indicated no additional generalized seizures but complex partial seizures had continued.

Neurological examination: entirely within normal limits.

Clinical diagnosis : Simple and complex partial seizures of temporal lobe origin .

Laboratory data:

1. The *CT scan without enhancement* now demonstrated a calcified lesion in the anterior-medial right temporal lobe which enhanced with contrast (Fig. 26-32A). Large early draining veins were also noted (Fig. 26-32B).

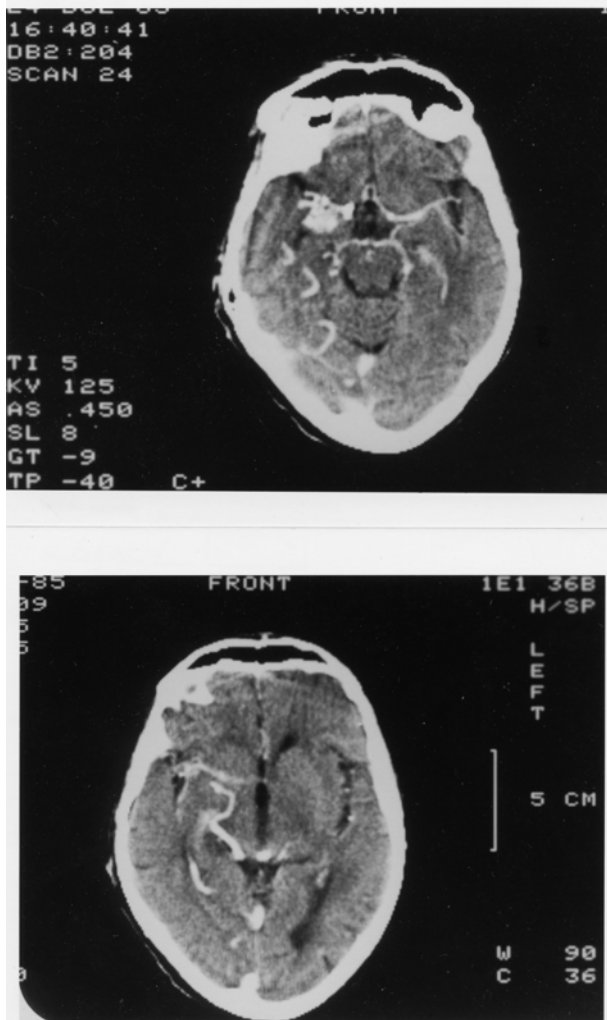


Figure 26-33. Arteriovenous malformation. Right anterior temporal:
 Case History 24-12 CT Scan. This 51-year-old right-handed female
 was evaluated in 1983. She had generalized seizures in 1977 and 36-
 year history of complex partial seizures. She would feel "weird
 sensations" and detached with a "strange odd smell", then a sense of
 terrible fear. She also had a history of migraine headaches preceded
 by visual auras, and a normal neurological examination. was not
 remarkable. The CT Scan without contrast demonstrated a calcified
 lesion in the right anterior temporal lobe (not shown).
 A). With contrast a large enhancing lesion was present in the deep
 Sylvian fissure area - involving anterior medial temporal areas, uncus
 and adjacent insula.
 B) At a higher level of section a large draining vein was visualized (see
 also fig 26-35 and text for details).

Subsequent angiographic studies confirmed the anterior venous malformation with supply from right internal carotid, middle cerebral and anterior choroidal arteries (26-33A) and the presence of shunting into a large early draining vein (26-33B).

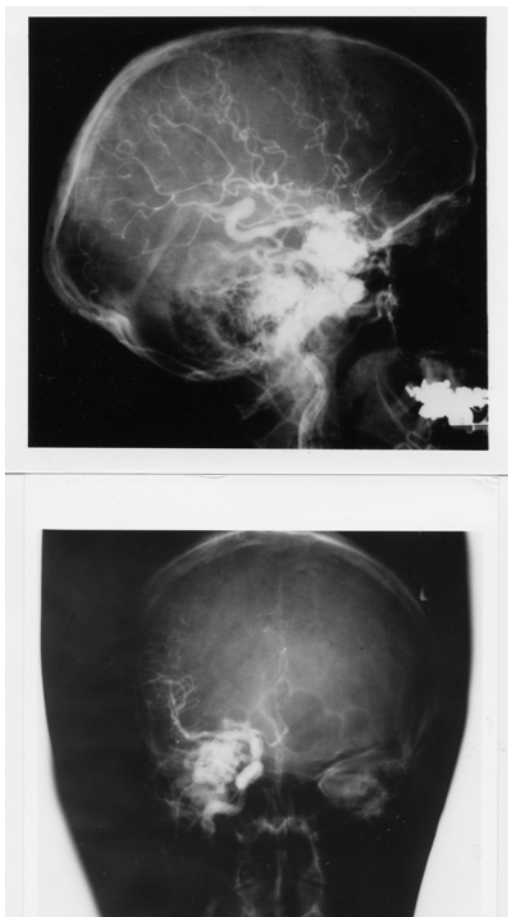


Figure 26-34. Arteriovenous malformation: Right anterior temporal lobe. Right carotid arteriograms. Case History 24-12

- A) Malformation - supplied by right internal carotid, middle cerebral, and anterior choroidal branches.
- B) There is early shunting of arterial blood into a large draining vein. See Text and Fig. 26-34 for details.

Comment: This patient presented with classical complex partial seizures originating in the right temporal lobe. No definite evidence of either subarachnoid or intracerebral hemorrhage was present over 35 years. With the use of CT and MRI scan, more of these lesions are being identified in an unruptured state in patients investigated for seizures and headaches.

Considerable controversy remains as to the appropriate therapy for the unruptured cerebral arteriovenous malformation (compare Aminoff, 1987 and Heros and Yong-Kwang, 1987). Long-term follow-ups - 12-20 years - does suggest a 25-39% risk of hemorrhage with a mortality from that hemorrhage of 10-14%. The risk of recurrent hemorrhage the first year is 6% with the subsequent annual risk for hemorrhage for both ruptured and unruptured 3% per year (see also Crawford et al, 1986, Brown et al 1988, Rigamont, et al 1988).

Surgical therapy involved excision after ligation or embolization of feeding vessels (Stein and Wolpert, 1986, Stein and Mohr, 1988, and Mohr, et al 1986).

CHAPTER 27: NON VASCULAR SYNDROMES : TRAUMA, TUMORS, INFECTIONS, TOXIC METABOLIC AND SYSTEMIC DISORDERS

I TRAUMA

Case 27-1 presents an example of an epidural hematoma seen in 1963 prior to modern neuroimaging.

Case 27-1: This twenty-two-year-old, white airman, during a winter storm, was involved in an auto accident at 11:30 p.m., in which he struck his head against the windshield. He also sustained minor abrasions of the shoulder, hands and chest. The patient apparently was dazed, perhaps unconscious, for a matter of seconds to minutes. He was taken by ambulance to the emergency room of the nearby army hospital where a brief evaluation indicated that the patient was alert, without definite neurological findings, and apparently without significant injuries. Skull X-rays did indicate a linear fracture over the right temporal area which did not, however, definitely cross the major groove of the middle meningeal artery. The patient was, therefore, admitted to the intensive care ward for head injury observation.

The patient was apparently alert upon his arrival on the ward. It should be noted, that the major attention of the physicians in the emergency room and of the nurses on the intensive care ward was given to four other patients from the same accident who sustained very severe and obvious injuries. However, by 5 a.m., the patient was reported by the nurses to be agitated and confused.

Neurological examination: (8 a.m.)

1. *Mental Status:* The patient was agitated and unable to cooperate. He was sitting up in bed, holding his head, moaning and hyperventilating to a marked degree. He answered only occasional questions and then with a yes or no.

2. *Cranial Nerves:* intact except

Fundi: The examination was negative but incomplete.

Pupils: There was a bilateral but sluggish response to light. A minimal asymmetry was present. The right pupil was perhaps slightly larger and slightly more sluggish than the left.

3. *Motor System:* All limbs were moved spontaneously. There was a variable increased resistance to passive motion, but this was apparently due to the patient's inability to cooperate.

4. *Reflexes:* Deep tendon reflexes were increased bilaterally. Plantar responses were bilaterally equivocal.

5. *Sensation:* Pain sensation appeared to be intact.

6. *Neck:* There was variable resistance to attempted flexion.

7. *Head:* The patient moaned when palpated over left or right temporal areas.

Neurological diagnosis : Possible evolving acute bilateral epidural or subdural hematoma

Subsequent course: The patient was to be evaluated by the civilian neurosurgical consultant, whose arrival was delayed by several other emergencies and a snowstorm. In the meantime, progression occurred.

Neurological examination (4 p.m.): The patient was now deeply comatose with little response to stimulation. The pupils were now bilaterally fixed and dilated. The four limbs were extended in a decerebrate posture with significant spasticity on passive motion. The degree of spasticity in the upper limbs could be modified by tonic neck maneuvers. The plantar responses were bilaterally extensor. Spontaneous respirations were now irregular and infrequent, and the patient required the assistance of a mechanical respirator.

Neurological diagnosis: Acute tentorial herniation with brain stem compression secondary to epidural hematoma.

Subsequent course: A general surgeon immediately performed definitive therapy. Bilateral burr holes were placed. An epidural hematoma over the right temporal-parietal area was evacuated and the

bleeding middle meningeal artery branch was coagulated and ligated with a significant rapid improvement in the patient's status. Follow-up examination approximately two months later indicated that the patient had returned to active duty but was experiencing some problems related to changes in recent memory and to changes in motivation and personality. No significant motor or sensory findings were present. Minor and inconsistent asymmetry of deep tendon reflexes was present.

Comment: This patient followed the usual pattern of a short lucid period followed by the rapid progression of confusion, agitation, coma and brain stem deterioration of function. As indicated by Plum and Posner (1980), the development of hyperventilation is often indicative of a midbrain-upper pontine stage of damage from an expanding supratentorial lesion. The early appearance of hyperventilation followed by bilaterally fixed dilated pupils and a decerebrate state may well indicate that the supratentorial lesion was producing a more central downward compression of the midbrain and less of a lateral uncal-type compression. In any case, it is evident that brain stem compromise was progressing rapidly. So rapidly, in fact, that therapy had to be undertaken immediately. In such a case, there was no longer time for the transfer of the patient to a specialized treatment center and no longer any time for specialized laboratory studies. Today, such a patient would have undergone CT scan studies at the time of emergency room evaluation or at the first sign of change in mental status. Similar cases of recovery of function from brain stem compression in patients with acute subdural or epidural hematomas have been reported by Brendler and Selverstone (1970).

The following case provides an example of chronic bilateral subdural hematomas

Case 27-2. (Patient of Dr. Alex Danylevich). This 83-year-old white female was transferred from her local hospital because of increasing confusion. Two months prior to admission, she had been involved in a motor vehicle accident sustaining fractures of her ribs and left clavicle. She also struck her head and had a scalp hematoma in the right frontal area. She was admitted to her local hospital at that time for several days. She was described as having post-traumatic anterograde and retrograde amnesia and obtundation which cleared over her hospital stay. She returned to her usual activities. Two months after the trauma she re-entered her local hospital with a three day history of increasing confusion and lethargy. When she became mute she was transferred to St. Vincent Hospital. Serum sodium at her local hospital had been low at 124 mEq/liter and CSF protein was reported at 62 mg%. EEG was reported as diffusely slow.

Neurological examination:

1. *Mental status:* She was relatively lethargic but could be aroused to an alert state. The patient was mute and did not follow commands even when relatively alert.
2. *Cranial nerves:* Pupils were 2 mm. and reactive. Sudden paroxysmal nystagmoid deviations of the eyes to the right occurred during the exam.
3. *Motor system:* Strength was intact. Tone was increased in the right leg.
4. *Reflexes:* Deep tendon stretch reflexes were symmetrical. Plantar responses were extensor bilaterally.
5. *Sensory system:* Pain responses were intact.

Clinical diagnosis: Chronic subdural hematomas, probably bilateral.

Laboratory data:

1. The CT scan (Fig. 27-3) demonstrated significant bilateral chronic subdural collections much denser on the left where the lateral ventricle was obscured and shifted to the right. The right lateral ventricle and sylvian fissure were enlarged. There was a question of additional recent rebleeding into the subdural collection on the left.
2. Serum sodium was low at 117 mEq/liter. Serum osmolality was 236. Urine sodium was 53 mEq/liter.

Hospital course: Serum sodium was corrected. Then, bilateral subdural hematomas were removed via burr holes on the right and a bone flap on the left where substantial chronic membrane and fluid were found. Neurological examination eight hours after conclusion of the procedure, indicated an alert patient who had no apparent language disorder and no weakness. Follow-up CT scan, 6 days after surgery revealed re-expansion of the cerebral hemispheres. Considerable cortical atrophy was

now evident. This was presumably long-standing predating the subdural hematomas. She was transferred back to her local hospital, 10 days after surgery. At that point she was alert; ambulating with assistance and was able to feed herself. She did develop transient right face and hand focal motor seizures which were treated with anti-convulsants.

Comment: If the history of trauma two months previously had not been present with a prior hospital admission related to the trauma, the confused obtunded mute state in this patient might easily have been attributed to a metabolic encephalopathy (low serum sodium) or to the cortical atrophy of a senile dementia of Alzheimer's type. Many patients with primary cerebral disease will develop a low serum sodium due to inappropriate secretion of anti-diuretic hormone with retention of water and dilution of serum sodium. The mute state in this patient in retrospect probably reflected the severe involvement of the dominant left cerebral hemisphere. The sudden eye movements to the right probably represented focal seizure activity originating in the left frontal eye fields, not far from the cortical area providing the focus for the post operative seizures.

In some patients without a definite history of trauma, the predominant findings may be those of a progressive bilateral frontal lobe involvement with confusion, bilateral grasp reflexes, and a frontal lobe apraxia of gait. In such patients, the nature of the pathological process involving the frontal lobes may be uncertain. The differential diagnostic list may include metastatic disease, frontal parasagittal meningioma or frontal glioma.

There are patients who are at increased risk for subdural hematomas: patients receiving anticoagulant medications, or patients with bleeding disorders, e.g., as in leukemia. The problem is more common in the elderly, in chronic alcoholics, and in patients with Parkinson's disease perhaps because such population groups are more prone to unsteadiness and falls. In the patient with cortical atrophy as in Alzheimer's disease, the bridging veins may be stretched and thus more prone to tear. In addition, the patient is unable to recall minor trauma and is already confused. In addition, because of the atrophy, a large amount of blood may accumulate in the subdural space without producing early symptoms of headache and other symptoms.

The problem also exists in the infant during the first year of life. The picture presented, however, differs significantly from that seen in the adult because in the infant, separation of the sutures may occur, allowing the intracranial cavity to expand. The onset is then often nonspecific and nonfocal: an enlargement of the head, a failure to thrive, a failure to gain weight, a failure to reach developmental landmarks. At times, generalized seizures, vomiting, and papilledema may be noted. The etiology often relates to presumed birth trauma.

A related problem may also be seen in infants following meningitis. This is the problem of subdural effusions usually occurring in relation to *Haemophilus influenzae* meningitis. The diagnosis of both subdural hematoma and subdural effusions may be made in the infant by CT or MRI scan replacing the earlier technique of subdural taps. The cerebrospinal fluid in these cases is often found to be abnormal with the presence of blood or xanthochromia and an elevated protein content.

II TUMORS

The following case history provides an example of the course of a low grade glial tumor.

Case 27-3: This 41 year old right handed white widow was admitted to the hospital because of increasing frequency of seizures. At age 30, eleven years prior to admission, the patient experienced her first generalized convulsive seizures. The neurological examination and the electroencephalogram were normal. Four years prior to admission, the patient had a change in the character of her seizures, she began to experience focal seizures involving the right arm and leg. These would begin with the sensation of a "chill" or stiffening of the right leg and a "numbness" (a tingling) which would then spread to the lower back. At the same time, weakness would occur in the right leg followed by repetitive clonic movements of the right arm. During this time, the patient would be unable to talk distinctly but would be aware of her surroundings. Although the episode continued for several minutes, there was no apparent loss of consciousness. Examination by Dr. John Hills at that time revealed a slowness of response but no definite neurological deficits. The EEG was again normal. Neurological evaluation three years later (one year prior to admission) was again unremarkable although focal seizures were still occurring every 2-4 weeks. Evaluation 2 months prior to admission, now indicated a more increase in deep tendon stretch reflexes in the

right lower extremity and an equivocal plantar response on the right side .Hospital admission finally occurred because the weakness experienced in the right leg during the seizure was becoming more severe.

Neurological examination

1. *Mental status*: The patient was anxious and tremulous with moderate psychomotor retardation and poor attention span. Digit span was limited to 5 digits forward and 4 in reverse .However orientation, memory ,delayed recall , calculations and language function were all intact.
2. *Cranial nerves*: All were intact with no papilledema.
3. *Motor system*: Strength, gait and cerebellar signs were all normal.
4. *Reflexes*: Deep tendon reflexes were slightly increased on the right side. The plantar response on the right was equivocally extensor.
5. *Sensory system*: Intact except for a minimal bilateral decrease in sensation at the toes.

Clinical diagnosis: Left parasagittal tumor most likely a meningioma, low grade glial tumor such as oligodendroglioma or low grade astrocytoma considered possible but very unlikely.

Laboratory data:

1. Chest and skull x rays ,radioactive brain scan(Hg 197) and left carotid arteriogram were all normal.
2. *EEG* was now mildly abnormal because of occasional focal sharp waves ,left parietal parasagittal area.
- 3.*Pneumoencephalogram* demonstrated a slight downward depression left lateral ventricle suggesting a possible left parasagittal mass. The CSF obtained was normal.

Subsequent course: Since the brain scan and arteriogram were normal, a meningioma was considered unlikely and a low grade glioma was considered the most likely diagnosis. The lack of calcification on the skull x rays was considered a point against the diagnosis of an oligodendroglioma and more in favor of a low grade astrocytoma. Since the patient was relatively free of neurological deficit and the dominant hemisphere was involved, neurosurgical intervention was deferred .Her anticonvulsant medications were readjusted. Frequent office evaluations indicated that significant progression was occurring with increasing weakness of the right leg, and an inability to form letters in handwriting. .Four months after hospital discharge ,the patient now had a right central facial weakness ,a mild right hemiparesis, and increased deep tendon stretch reflexes on the right and a right Babinski sign. Speech was dysarthric with a minor degree of misnaming or inability to name objects. A left carotid arteriogram now indicated a deep left posterior frontal mass lesion. There was also a suggestion of abnormal vascularity in the region of the pericallosal and callosal marginal branches of the anterior cerebral artery. Surgical exploration of the left frontal area indicated slight discoloration of and widening of gyri. Probe counting located an area of increased uptake of isotope (P32) at 16X normal in the mid and posterior frontal area. A partial frontal lobectomy was performed from the level of the sphenoid wing laterally and forward but sparing the speech areas. However tumor was still present at the posterior margin of the resection . Histologic examination of the tumor removed indicated a grade I- II astrocytoma. Following surgery ,the right sided weakness progressively improved, speech was unchanged. Following hospital discharge the patient ,received a 3 month course of supervoltage radiation (7,500 roentgens)directed to the left frontal parietal area. When last evaluated 18 months after surgery, there was a moderate disorientation for time , a nominal aphasia a slowness in following commands ,a perseveration of speech and performance, a right central facial weakness and a clumsiness in following commands.

Comment: The onset of seizures at age 30 ,always raises the question of a possible brain tumor. The initial seizures however were generalized convulsive seizures and the neurological examination and the EEG were normal, thus decreasing the risk of a tumor. When focal seizures appeared at age 36,the risk of a tumor was significantly increased but still ,the exam and the EEG remained normal .In retrospect ,the slowness of response might have suggested some frontal lobe involvement. By age 41, it was evident that a focal process was slowly evolving with some involvement of parasagittal motor cortex. Again the psychomotor retardation and the deficit in digit span at a time that delayed recall was normal (possibly consistent with an impairment of working memory) might have suggested some degree of. prefrontal involvement. Certainly, by the time of surgical intervention, 11 years after onset of symptoms, the pace of progression had accelerated. This might have indicated some alteration in the basic biological activity of the tumor.

Finally a note about diagnostic techniques . This patient was initially seen in 1956 and hospitalized in late 1967. At the time CT scan and MRI were not yet available. Today, an adult with onset of seizures at age 30 would have undergone an MRI or at least a CT scan with contrast. The diagnosis would have been made much earlier in time but the eventual treatment and results of treatment would probably not differ significantly from those obtained in 1967. The role of radiotherapy in low grade gliomas remains controversial. There is a role once transformation to a higher grade of malignancy has occurred.

MALIGNANT GLIOMAS

The following case demonstrates the apparent acute (possibly stroke like) onset and rapid progression of a very malignant glioblastoma multiforme.

Case 27-4 (patient of Dr. Tom Mullins): This 68 year old right handed white male was admitted to St Vincent Hospital with an apparent 4 to 5 day history of difficulty in doing calculations and in speaking, “he could think of the word ,but had difficulty getting it out”.

Neurological examination :

1. *Mental status and language function*: Speech was limited to short phrases with loss of connectors and sentence structure. Writing was impaired but, repetition, comprehension, naming and reading were intact.
2. *Cranial nerves*: Intact.
3. *Motor system*: Strength and gait were intact .However fine motor movements of the right hand were impaired .
4. *Reflexes*: Tone was increased on the right. The right patellar reflex was increased. Bilateral Babinski signs were present.
5. *Sensory system*: Intact.

Clinical diagnosis: Diagnosis was uncertain .The abrupt onset suggested a possible vascular event such as an embolus in the middle cerebral artery territory but the overall pattern including bilateral Babinski signs without significant hemiparesis was unusual. Thus other possibilities had to be considered including focal herpes simplex encephalitis, tumor or a small lobar hemorrhage.

Laboratory data :

1. EEG : Focal left hemisphere delta and theta slow wave activity was present.
2. CT scan(Fig.27-7):A. The non enhanced study demonstrated a low density mass in the mass in the left frontal-parietal parasagittal region with areas of hemorrhage. B. The contrast enhanced study demonstrated an irregular rim of enhancement.
3. Angiogram indicated an avascular mass in the left frontal-parietal area.

Subsequent course: Dr. Alex Danylevich performed a subtotal resection of this tumor which was found to contain blood clot and cystic fluid. The histology of the tumor was glioblastoma multiforme (Fig.27-5). The patient subsequently received 4000cGy whole brain radiation and an additional 2000cGy to the tumor site. Three months following surgery ,the patient developed increasing obtundation. CT scan revealed a large left frontal necrotic mass. Fever, hypocalcemia and hypernatremia developed and he expired one month later.

Comment: This patient presented with what appeared to be an abrupt onset of language problems raising the question of a cerebrovascular accident. In retrospect , it was evident on the CT scan and at surgery that the acute onset reflected the hemorrhage and necrosis which had occurred within the tumor. This was a rapidly growing ,extremely malignant tumor which apparently had outstripped its blood supply despite the neovascularity.

III INFECTIONS

FOCAL

Subdural empyema

The following case provides an example of subdural empyema complicating frontal sinusitis.

Case 27-5. This forty-eight year old, right-handed, white male was referred for evaluation because of headaches and papilledema. For 3 weeks prior to admission, the patient had severe bifrontal headaches which were constantly present and interfered with sleep. One week prior to admission, the patient developed a fever of 105° with a white blood count (WBC) of 25,000. X-rays indicated "sinusitis". The patient was hospitalized at his local community hospital. Confusion soon developed. Three days prior to transfer to a neurologic unit, the patient had a series of seizures characterized by turning of the head and eyes to the left. Lumbar puncture had indicated clear cerebrospinal fluid with pressure of 300 mm. and protein increased to 65 mg./100 ml. The patient had chronic right nasal discharge for ten years. Eight weeks prior to admission, the patient, while stooping down, struck his right frontal areas but was not - unconscious. A right periorbital ecchymoses developed, and the patient also had the onset of bilateral frontal headaches.

General physical examination: Temperature was elevated to 101°. There was right periorbital edema. Excoriation of right nasal mucosa was present.

Neurological examination:

1. *Mental status:* The patient was alert but irritable and slightly confused. He was poorly attentive and failed to persist in carrying out motor activities. He was oriented grossly for time, place and person. Calculations were poorly performed. Delayed recall was defective.
2. *Cranial Nerves:* All were intact with the exception of the fundi. Low-grade papilledema was present and venous pulsations were absent.
3. *Motor System:* Strength was intact, but there was a slight drift downward of the outstretched left arm.
4. *Reflexes:* Deep tendon reflexes were somewhat brisker at left arm and leg (3+) as compared to the right (2+). Plantar responses were flexor. A bilateral grasp reflex was present.
5. *Sensory system:* Intact
6. *Skull & Neck:* There were slight tenderness over the right periorbital area. Minimal nuchal rigidity (resistance to passive flexion of the neck) was present.

Clinical diagnosis: Right frontal subdural empyema or brain abscess.

Laboratory data:

1. The *WBC* was increased to 14,350 cells per cubic mm., and the sedimentation rate was increased to 110 mm. in one hour.
2. *Sinus X-rays:* Bilateral maxillary and frontal sinusitis was present with resorption of bone.
3. *Electroencephalogram:* Focal 4 to 7 cps slows wave activity was present in the right parietal area suggesting focal damage. Moreover, focal voltage suppression (reduction of voltage) was present in the right anterior frontal area suggesting a possible subdural collection.
4. *Right carotid arteriogram* showed an apparent slight shift of the anterior cerebral vessels to the left suggesting a right hemisphere space-occupying lesion.

Hospital Course: Following these studies a right frontal trephine (burr) hole was placed by Dr. Robert Yuan. When the dura was incised, 5 cc. of yellow purulent material escaped from the subdural space and additional purulent drainage was aspirated. Additional burr holes were placed in the right occipital area where a few drops of subdural pus were encountered. No pus was obtained from the left subdural area. Subsequent cultures demonstrated *Staphylococcus aureus* as the responsible organism. The dura and cortex otherwise appeared unremarkable although cerebral edema was present. The patient was subsequently treated with appropriate antibiotics. His temperature gradually subsided to normal and his mental

status cleared. Three weeks later, a bilateral frontal sinusotomy was performed by Dr. Thomas Klein with drainage of the sinus. Histological examination of a section of sinus mucosa removed demonstrated intense chronic inflammation. The patient continued to improve. When seen in followup examination four months after admission, papilledema had subsided, no neurological findings were present except for a slight reflex asymmetry (slightly increased on the left).

Comment: This patient presented a definite history of chronic nasal sinus infection with a recent exacerbation. The role of trauma in the exacerbation is uncertain. It is clear, however, that the sinusitis had produced involvement of the adjacent bone with subsequent spread to the adjacent frontal subdural space. The severe headache experienced by the patient reflected not only the process of infection involving the sinus and meninges but presumably also the increase in intracranial pressure. The early involvement of the right frontal area was suggested by the initial symptoms of confusion and by the occurrence of focal seizures characterized by turning of the head and eyes to the left. The findings of the electroencephalogram suggested a subdural collection of fluid or pus in the right frontal area.

These clinical and laboratory impressions were confirmed by the subsequent surgical observations. In the present case the arteriogram suggested only a non-specific space-occupying lesion in the right frontal area. The more specific finding in these cases would involve the displacement of distal branches of the anterior and middle cerebral artery from the inner table of the skull as in a subdural hematoma. Today the CT scan or the MRI/MRA is the study of choice for confirming the diagnosis of a subdural collection. Additional review of subdural empyemas will be found in Miller et al 1987. In the pre-antibiotic era, infections involving the nasal sinuses could produce thrombophlebitis of the cortical veins and superior sagittal sinus. With that complication, infarction of that area of motor cortex representing the leg could occur resulting in unilateral or bilateral leg weakness as well as focal motor seizures. Infection of the nose or face or of the ethmoid or sphenoid sinuses could produce thrombophlebitis of the cavernous sinus resulting in the syndrome discussed in the cranial nerve chapter: unilateral or bilateral involvement of the cranial nerves found in the lateral wall of the cavernous sinus (III, IV, VI and the ophthalmic division of V). The ophthalmic vein may be obstructed producing edema of the eyelid and face. Obstruction of the retinal vein produces papilledema. Infection of the middle ear or mastoid may produce involvement of the transverse or lateral sinus. If this extends to the jugular vein, increased intracranial pressure may also occur. However increased intracranial pressure may follow any involvement of the other venous sinuses. At the present time, dural venous sinus thrombosis is usually more indicative of dehydration and other systemic conditions in the infant and in the adult of immunological disorders or of conditions that produce a state of hypercoagulation such as polycythemia, carcinoma, pregnancy or birth control drugs. (refer to Daif et al, 1995 and DeVeber et al, 2001)

CHAPTER 30 MEMORY

A case of Wernicke-Korsakoff syndrome is presented in case 30-1.

Case 30-1. Patient of Doctor John Sullivan and Doctor John Hills): This 62-year-old, white, right-handed stonecutter had been a known heavy alcoholic spree drinker for many years. The patient would drink large quantities of wine for 6 to 8 weeks at a time. Two years previously, the patient had been admitted to the Boston City Hospital because of delirium tremens (tremor and visual hallucinations). Two months prior to admission shortly following the death of a brother-in-law, the patient began his most recent drinking spree. He unaccountably found himself in Florida, not knowing where he was and

why he was there. Apparently, he had drifted aimlessly for 5 weeks with no definite food intake for a month. The patient was brought back by his family and hospitalized at his local community hospital with diplopia, ataxia and marked impairment of memory. The patient had complaints of numbness of his fingertips and unsteadiness of gait. The patient after beginning treatment was shortly thereafter referred to the Neurology Service at the New England Medical Center.

General physical examination: No abnormalities were present except for an enlarged liver with the edge palpated approximately 2-1/2 finger breadths below the costal margin.

Neurological examination:

1. Mental status:

- a. The patient was markedly disoriented for time and place. At times, the patient thought that he was in New Jersey; at other times, he stated correctly that he was in Boston.
- b. The patient, with suggestion, would recall his apparent travels that day to various other locations within and outside Boston (he was actually in the hospital). Confabulation was also evident when it was suggested that he had recently seen various fictitious persons.
- c. Remote memory; The patient was unable to state his age. The patient was able to provide his birth date correctly. He could not give his address or telephone number. When quizzed as to the President of the United States, he selected on multiple choices the previous president. At times, the patient often indicated to visitors that his mother and father were still alive, though both parents had been dead for over 20 years.
- d. Insight; He appeared to have little insight for his disorientation in time. He had no insight as to his condition or for the reason for his hospitalization.
- e. The patient's digit span was normal at 7 forward and 6 in reverse.
- f. The patient could name various objects correctly when these were presented to him and yet he was unable to retain any memory of which objects had been presented to him five minutes previously. He was unable to retain any information concerning a story that he had been requested to learn.
- g. The patient was able to do 2 and 3 figure additions and multiplications without difficulty. He was able to do the initial subtractions in the serial 7 test but then lost track of the number to be subtracted.
- h. The patient was able to read and to write without difficulty. He showed no constructional apraxia and no left-right confusion.

2. *Cranial nerves:* There was horizontal diplopia on right lateral gaze. The minor degree of separation of images, however, did not allow precise identification of the muscle involved. A minor weakness of the right lateral rectus was suspected.⁶ Horizontal nystagmus was present on lateral gaze, bilaterally and vertical nystagmus on vertical gaze.

3. *Motor system:* Strength was intact except for a minor degree of weakness in the distal portions of the lower extremities evident on ankle dorsiflexion and toe dorsiflexion.

The patient walked on a narrow base with eyes open and showed no evidence of an ataxia of gait. On a narrow base with eyes closed, the patient had a positive Romberg test.

No cerebellar findings were present.

4. *Reflexes:* Deep tendon reflexes were normal at triceps and biceps, decreased at radial periosteal. And absent at patellar and Achilles even with reinforcement.

⁶ The minor nature of the diplopia undoubtedly reflected the improved nutritional status that had occurred during the previous 5 days of hospitalization at his community hospital. We presume that if the patient had been examined prior to hospitalization, more marked lateral rectus palsy probably would have been delineated.

Plantar responses were flexor bilaterally.

No grasp reflex was present.

5. Sensory System: Pain and touch were decreased in the lower extremities below the mid calf. Vibratory sensation was absent at the toes and decreased over the tibia to a marked degree and to a lesser degree over the knees. There was to a lesser extent, a decrease in the upper extremities at the fingertips and wrists.

Position sense was decreased at fingers and toes.

Clinical diagnosis: Wernicke' encephalopathy plus nutritional poly neuropathy

Laboratory data: Complete blood count, liver functions and renal functions, CSF, EEG, and X-rays of the skull and chest were all normal.

Subsequent course: The patient was treated with thiamine, 50 MGS daily. There was a significant improvement in extraocular functions. The patient had no diplopia after the day of admission. There was no significant change in his mental condition or peripheral neuropathy. Evaluation 3 months later, indicated persistent disorientation for time and place and severe selective deficits in memory (delayed recall was still grossly defective).

Comment: This patient presents a relatively typical history of the Wernicke-Korsakoff syndrome. He had been a heavy alcoholic spree drinker. The major symptomatology that was apparent to the patient's family and to his physician, related to his marked confusion, severe impairment of memory and confabulation. The patient himself had no significant complaints and little insight into his disease. In some cases, the severe memory disturbances may be present without any definite evidence of confabulation. Not only the retentive memory for new material was impaired but also the patient's distant memory was also significantly impaired. In such cases with severe impairment of memory the prognosis for a complete recovery of mental status is very poor. The diplopia and nystagmus, as expected, resolved significantly with treatment with thiamine. The ataxia of gait, which had been present early in the case, had apparently resolved by the time of transfer from his local hospital. A significant peripheral neuropathy, mainly distal sensory, was present related to multiple B vitamin nutritional deficiency.

In many cases, the state of confusion in Wernicke's encephalopathy is preceded by or accompanied by a period of delirium tremens indicating alcohol withdrawal. The use of intravenous glucose feedings without supplemental intravenous thiamine during such a withdrawal state may actually increase the requirements for thiamine, thus exacerbating the thiamine deficiency state. For this reason, all patients under treatment for alcohol withdrawal (or admitted to the hospital with a recent past history of alcoholism) should be treated with high dosage vitamin therapy as well, on the presumption that they are candidates for nutritional deficiency.

A case of transient global amnesia is presented in case 30-2 below.

Case 30-2: This 55-year-old, right-handed, white male, college professor, awoke at 3:00 a.m. on the morning of admission in an uneasy and restless state. He asked his wife what day it was but then did not recall what she had told him. He did not know the month, kept repeating himself and asking the same questions. His wife arranged for him to be seen early in the morning by his family physician who lived a short distance away. The patient, who was familiar with the route, was unable to find his way there. When he arrived at the doctor's office, he was unable to explain why he had come. The patient apparently had forgotten about the incidents, which had occurred earlier that morning. He had no recollection that he had a grandchild born three weeks before. He could remember no significant events from this 3-week period prior to the onset of his illness. The patient's more remote recall and other intellectual capacities remained intact. The patient drove into Boston later that day but became lost despite the usually familiar route.

The patient had a past history of gout with an elevated serum uric acid level.

Neurological examination: Findings were essentially limited to the mental status examination.

When examined in the early afternoon, the patient was beginning to regain some of his ability to retain new information. The patient was generally oriented to person and place. However, he was disoriented for the day and month but was oriented for the year. The patient's store of information was quite intact suggesting a highly intelligent person.

The patient had marked difficulty with delayed recall. He could recall none of the 4 objects after 5 minutes. He could not remember any of the three test phrases given to him when asked about these 5

minutes later. He did recall in a vague manner that a memory test had been given him. As regards recent memory, the patient was unable to remember his visit to his family physician earlier in the day. Digit retention, however, was relatively well preserved; 6 forward and 5 backward. The patient had no defects in calculation. There was no evidence of a constructional apraxia. Language function was entirely intact.

Clinical diagnosis: Probable transient global amnesia

Laboratory data:

1. Complete blood count, serology, blood urea nitrogen, total cholesterol, uric acid skull and chest X-rays, EEG and complete CSF were all within normal limits.
2. The *brain scan* demonstrated a small area of increased uptake of radioisotope (Hg197) in the left temporal region.

Subsequent course: Over the several hours following admission, the patient gradually regained his ability to retain new information and to recall the events of the preceding 3 weeks, the more remote events being recalled first. The memory for the events of the day prior to admission was regained last. This pattern is referred to as a shrinking retrograde amnesia. The specific events that occurred on the morning of admission were never recalled. The following morning delayed recall was four-out-of-four objects after 8 minutes. The patient's mental status and neurological examination were otherwise within normal limits. A repeat brain scan, 3 months after the episode demonstrated considerable improvement, and all brain scan findings had resolved at 5 months. No additional episodes occurred during the one-year after the acute episode.

Comment: The patient's main deficit was in learning new information (anterograde amnesia) with the old stored long-term memory information still intact. During the episode there was a retrograde amnesia that initially extended back for three weeks. As recovery occurred, this retrograde amnesia disappeared. These relatively recent past memories were intact but transiently not accessible. The labile stage of long-term memory has been estimated to be a matter of 20-180 minutes. This case suggests that there is not a sharp border between the labile more recent stage and the remote stage of long-term memory or perhaps of the ability to access those memories. The patient could not remember what happened during the episode. That is suggestive of mesial temporal lobe involvement, in this case left hippocampal region in dominant hemisphere. The ability to perform calculations and language functions was otherwise intact. This would suggest that lateral temporal areas were not involved. The electroencephalogram was normal and consistent with such a lack of involvement of the lateral aspects of the cerebral hemispheres. Occasionally, the EEG will demonstrate a minor focal involvement of the temporal lobe. More often, as in this case, the study is normal. CT scan and MRI when performed are usually unremarkable. SPECT scan might well indicate transient focal involvement as indicated above. The brain scan in this case did suggest a transient abnormality, which would be consistent with an area of ischemia/ infarction, which resolved over the succeeding months. Such an episode must be distinguished from episodes of amnesia, which may occur in relation to, and following a temporal lobe seizure.

The effects produced by electrical stimulation of the hippocampus may also occur as relatively selective ictal and postictal phenomena in a complex partial seizure originating in mesial temporal lobe structures as illustrated in case history 30-3 which follows. Focal temporal lobe seizure phenomena were followed by a period of impaired recent memory with an inability to record new memories.

Case 30-3: This 68-year-old, white male one year prior to valuation fell, striking his occiput and transiently losing consciousness. Except for a persistent defect in his sense of smell, the patient had no apparent neurological defects following this injury. Approximately six months later, the patient had the first of a series of recurrent episodes of amnesia. These episodes occurred most often on awakening. On some, but not all, occasions the episodes were preceded by a sensation of gastric upset, a strange odor and a sensation of familiarity (*déjà vu*). The episodes of total amnesia would last 30 to 60

minutes. There would then be an impairment of memory for approximately one to two days. The patient was said during the episode of total amnesia and during the subsequent episode, to behave in an otherwise normal and rational manner. For example, he would be able to converse with his wife and others. During the episodes, he was said to be unable to remember tasks, which his wife had asked him to do during that day. A significant impairment of retentive memory would be apparent to his wife and to others. His memory for more distant and remote events was also impaired to a variable but lesser degree. The patient would then regain memory progressively over the course of the next one to two days. Apparently, memory was not regained in any orderly pattern from recent to remote or vice versa. The patient at no time had any abnormal movements suggestive of a generalized convulsion.

No automatisms had been noted and to others the patient would appear fully conscious during the episodes.

Neurological examination:

1. *Mental Status*: The patient was oriented for time, place, and person. Delayed recall was intact. The patient could remember 4-out-of-5 objects in 5 minutes. Remote memory was intact. Digit span was slightly impaired at 6 numbers forward and 4 in reverse.

2. *Cranial Nerves*: All areas were intact with the exception of cranial nerve I where olfaction was decreased for the odor of coffee grounds, bilaterally.

3. *Motor system, reflexes and sensory system*: *Intact*.

Clinical diagnosis: 1) Complex partial seizures (most likely post traumatic) with episodes of amnesia as an ictal and or post ictal phenomena. 2) Post traumatic anosmia.

Laboratory data: 1. *Skull X-rays, routine EEG, radioactive brain scan, fasting blood sugar and glucose tolerance tests, pneumoencephalogram and spinal fluid examination were normal..*

2. *The EEG obtained after a period of sleep deprivation revealed occasional multifocal spikes during sleep in the right anterior temporal area and to a lesser degree the left frontal-anterior temporal area.*

Subsequent course: The patient was treated with anticonvulsant medication. The episodes continued to occur once per month but were now of shorter duration, lasting only 15 to 20 minutes. The impairment of memory was less marked and involved only the ability to learn new material without prolonged periods of retrograde amnesia. After 8 months no additional episodes occurred. When seen three years after initial evaluation his neurological examination was unremarkable except for the defect in olfaction suggesting that more serious progressive disorder was not present.

Comment: In this case the episodes experienced by the patient could have posed a diagnostic problem if the occasional warning symptoms of olfactory aura, déjà vu and epigastric sensation had not been present. Most of the episodes experienced by the patient were not preceded by these clear symptoms of temporal lobe seizure, but were instead simply episodes of amnesia. Though the actual temporal lobe seizures apparently lasted only a matter of 30 to 60 minutes, some degree of impairment of memory was present for one to two days following the episode.

The etiology of the seizures in this case must relate to the patient's preceding head trauma. The loss of olfactory sensation following the trauma suggested that this trauma was of sufficient nature to tear the nerve filaments passing through the cribriform plate to the olfactory bulb on the orbital surface of the frontal lobe. Such trauma does produce contusions of the orbital frontal cortex and epileptogenic foci may result. We may also assume that this trauma may have been sufficient to produce some minor contusion of the anterior poles, inferior and medial surfaces of the temporal lobes against the bony walls of the middle fossa with a resultant scar and epileptogenic focus. The fact that olfactory hallucinations and the experience of déjà vu preceded some of the amnesic episodes

would make the temporal origin more likely. The routine electroencephalogram is not reliable in the detection of seizure discharges in either the mesial temporal or the orbital frontal areas. The electroencephalogram showed significant areas of discharge in the temporal lobe only under conditions of sleep deprivation which acts to precipitate seizure discharges in individuals who have an underlying predisposition for seizure discharges. For additional discussion, see Gallassie, et al (1988), Hughlings-Jackson (1889), Tassinari, et al (1991).

The following case history presents an example of presenile dementia.

Case 30-4: This 64 year old right handed white male formerly an administrative assistant for the veteran's administration and newspaper distributor was initially evaluated for impairment of recent memory. Initially, the wife indicated this had been progressive over 4 years, but she was subsequently able to date this back to age 54 years, 10 years previously. A review of his record indicated that another neurologist of our department had seen him 4 years previously with similar memory complaints. The neurological examination at that time demonstrated no focal features, but his mental status examination indicated an inability to recall any of four objects. There were minor changes in time orientation: his date was off by one month and the day of the week was incorrectly stated. In the interim, the memory problems had progressed. In addition there were now personality changes. He no longer participated in those activities which had previously been of great interest. He was also having some problems in finding words. There were no problems in the activities of daily living and he was not getting lost in his familiar environments.

Family history: There was no history of neurological disease in his siblings or father. His mother had died at the relatively young age of 48 of cancer.

Neurological examination:

1. *Mental status:* The mini mental status exam indicated a total score of 19 out of 30. He had particular problems in time orientation. He was able to do the immediate recitation of three objects and of a test phrase but could remember none of these on a delayed recall test. He also had difficulty copying a test figure. The patient was often tangential in his answers and demonstrated inappropriate joking.

2. *Cranial nerves:* intact

3. *Motor system* was intact as regards strength, gait and cerebellar functions. However premotor /frontal lobe functions were abnormal. He had a release of the instinctive grasp reflex. He had difficulties performing the Luria three stage motor sequences demonstrated by the examiner (slap thigh with palmar surface, then with ulnar edge of hand and then with ulnar surface of closed fist.).

4. *Reflexes:* deep tendon stretch reflexes, and plantar responses were physiologic.

5. *Sensory system:* intact

Clinical diagnosis: Alzheimer's disease

Laboratory data:

1. All screening studies such as *complete blood count, sedimentation rate, B -12, folate, thyroid functions and serological test for syphilis* were normal.

2. *CT scan* demonstrated significant dilatation of the temporal horns. (This change in the size of the temporal horns suggested hippocampal atrophy.) In addition there was a general increase in lateral ventricular size. There was also blunting of the angles of the frontal horns.

3. *SPECT scan* was within normal limits except for a slight decrease in perfusion in the left parietal region.

Subsequent course: The patient was begun on treatment with 5mg per day of donepezil (Aricept) a centrally acting acetylcholinesterase inhibitor and high dosage of vitamin E (a possible antioxidant). When re-evaluated at one month, his family reported improvement in memory; the mini mental status exam score was now 21 out of 30. At 10 weeks into treatment, the score had increased to 25 out of 30. There was particular improvement in the delayed recall section of the exam. There was however no change in personality. He still showed inappropriate jocularity when he could not answer a question and at times was tangential in his answers. Administration of the acetylcholinesterase inhibitor temporarily improved memory function for approximately 18 months. However by age 67, behavioral disturbance (agitation, aggression nocturnal wandering and sexual disinhibition) and urinary incontinence were becoming major problems. He could no longer be managed in his home and day care setting despite the

use of haloperidol. This resulted in his placement in a nursing home. At age 69, he was now described as relatively nonfluent, and very confused. He recognized his own name and occasionally recognized relatives but showed no other response to questions. He was usually restricted to a wheel chair, could walk with assistance. He was "stiff and afraid" when requested to walk.

Comment: This patient presents a typical example of the slowly progressive course of Alzheimer's disease. Memory problems had begun insidiously at approximately age 54. Initially these problems in the older adult may be attributed to a benign age related process in which there is minor difficulty in accessing information such as names although the ability to incorporate new information is still intact ("wait a minute, the name or word will come to me eventually"). When evaluated by a neurologist at age 60, the major finding was a severe deficit in delayed recall suggesting a process at the level of the hippocampus. The patient failed to return for follow up at that time and when he did reappear at age 64, he was now beginning to show changes in personality and frontal release signs suggesting involvement of the prefrontal and premotor areas. The use of a cholinesterase inhibitor produced some improvement in memory for about 18 months but had little effect on the changes in personality and behavior. The use of this agent has been estimated to postpone nursing home placement by approximately 15 months. Eventually by age 69, fifteen years after disease onset, gait and other motor functions were seriously affected.

The rationale for the use of cholinesterase inhibitors is based on the demonstration by Drachman and Leavitt (1974) that administration of scopolamine, an anticholinergic drug that crosses the blood brain barrier, would produce a transient syndrome similar in many respects to memory and cognitive changes of Alzheimer's disease. Subsequent studies demonstrated a marked loss of neurons in the basal forebrain nucleus of Meynert, a major source of cholinergic fibers to the cerebral cortex. (Whitehouse et al 1981 Rogers et al, 1985 editorial of Growden 1992). However, a simplistic cholinergic hypothesis is insufficient to explain all of the features of Alzheimer's disease. Administration of acetylcholine esterase inhibitors in mild cases (mini mental status score of 10-25) has only a limited value as in the present case. Other neuronal systems are involved (noradrenergic synapses are also involved. hippocampal system is severely involved).

The following case 30-5 provides an example of general paresis producing severe changes in cognitive function and personality.

Case 30-5 : This 59-year-old right-handed white male, cleaning establishment owner, five years prior to evaluation, manifested a personality change - increased rigidity and irritability. He would become enraged over trivial matters many times per day. During the last 1.5 years, this process accelerated. He became more antisocial, unable to interact with employees and customers. His level of comprehension declined. He became more aggressive towards his wife and children. He often manifested frank paranoia and suspiciousness, accusing his wife of unreal, sexual infidelity. During the last 1.5 years, a significant gait disturbance had also developed, with impairment of balance. A slowing in speech and a tremor of hands had developed over the previous year.

The patient had been born in Poland. All significant infections were denied. He had received injections of "liver" and B12 after the war "for anemia" but had received no recent B12 injections.

Neurological examination:

1. *Mental status:* The patient was oriented for time, place and person.

Delayed recall was markedly impaired none of five in five minutes without assistance, one of five with assistance. Repetitions and naming of objects were intact. Distant (remote) memory was good. The patient could list all major world leaders during World War II and all assassination attempts.

The patient was often tangential in his responses and often initiated irrelevant conversations.

Serial 7 subtractions could not be done but the patient could reverse 12 months of the year.

Abstract reasoning for similarities was poor.

He often got up from the bed and looked outside the curtain, checking the activities of his roommate.

2. *Cranial nerves:* Pupils were small, 2 mm., and irregular but did respond to light.

Twitching and grimacing of face, eyelids and tongue occurred. He also had a lid lag.

3. *Motor system*: Strength was intact. Gait was wide-based, with a positive Romberg test. The patient was quite tremulous with occasional myoclonic jerks. He could not do rapid alternating movements.

4. *Reflexes*: Deep tendon reflexes were normal (2+) in the upper extremities, trace at patellar and absent at Achilles. Plantar responses were flexor, bilaterally. There was no release of the grasp reflex. Other frontal release signs were absent.

5. *Sensory system*: Pain, touch and position sense intact. Vibration was markedly decreased at toes, and ankle with minor preservation at knees.

Clinical diagnosis: Progressive dementia and personality change. Multiple entities to be considered including (1) the combination general paresis and tabes dorsalis, (2) B12 deficiency, (3) frontal lobe tumor, (4) frontal dementia and (5) Lewy body dementia

Laboratory data: The abnormal findings included:

1. *Vitamin B12 level* was borderline low at 209 picograms/ml., *Schilling test*, however, demonstrated normal absorption (25.4% excretion of radioactive B12 in urine).

2. Serum serological test for syphilis (RPR) was reactive with the more specific FTA markedly reactive.

3. *Cerebrospinal fluid*: 98 white cells were present - all lymphocytes. CSF protein was elevated to 116 mgs.% (normal <45 mgs.%). Sugar was low at 44 mgs.% with a simultaneous blood sugar of 90. Spinal fluid serological test for syphilis (VDRL) was positive.

4. *CT scan* showed mild frontal and temporal atrophy

Subsequent course: The patient was hospitalized for two weeks and received high dosage intravenous penicillin therapy, three million units every four hours for 10 days (18 million units per day).

When seen again 2 months later, the patient and his family reported that gait and coordination had significantly improved. Memory and personality had not improved. He still had episodes of agitation and irritability. Reflex and sensory findings were unchanged. The patient had been inconsistent in taking any medication such as haloperidol, aimed at altering his agitation.

He failed to return again for 18 months. Paranoid ideation had become more prominent. He could no longer manage his fiscal affairs. Orientation and delayed recall were intact. There was minor tremor of the hands and an unsteadiness of gait. Romberg was positive although position and vibratory sensation were intact. Serum serology was now negative. Lumbar puncture now indicated no significant cells, a normal protein.

Subsequently he did require hospitalization for renal failure secondary to enlarged prostate and a neurogenic bladder. Spinal fluid VDRL and serum RPR serological tests for syphilis, were both nonreactive. Serum FTA ABS - a much more specific and more sensitive test for previous syphilis was still 3+ reactive.

Telephone follow-up 11 years after the initial episode indicated that personality and cognitive changes had essentially leveled off, irritability and hostility were less. He had no urinary problems. He was unsteady in walking, but was still able to drive small distances and was living at home. Additional information approximately 20 years after the initial evaluation indicated that he spoke very little, he no longer demonstrated agitation. His mobility was more limited. Of interest, one pupil no longer responded to light but did respond to accommodation. CT scan demonstrated greater atrophy.

Comment: This patient had clinical manifestations predominantly related to general paresis. Both the history and the examination also provided evidence of tabes dorsalis. Penicillin therapy resulted in a non-active state, as regards serum serology and any cellular activity in the spinal fluid. However, the damage to cerebral cortex was not reversed and continued to provide a significant problem, as regards personality function. Thus, once cognitive function has been altered, due to damage to and loss of neurons, the changes in memory and personality may be persistent. Disturbances of frontal lobe and limbic system function once initiated may continue to evolve.

Moreover once the patient reaches the late 60's and the 70's, apparent progression of neurological changes in memory and other cognitive functions may occur related to the combined effects of the previous acquired lesions of general paresis and the effects of even mild Alzheimer's disease. A double hit has occurred.

The following case provides an example of a patient whose initial symptoms related primarily to a severe alteration in personality function and social interactions. Features of Parkinson's disease were apparent on her examination. Diagnosis was uncertain but diffuse Lewy body dementia should be considered.

Case 30-6: This 60-year old, right handed separated white housewife, residing in a nursing home, was referred for evaluation of problems in walking, progressive behavioral change and memory disturbance. Six years previously at age 54, a change in behavior was first noted by her family. She began to accumulate papers about the house. She would leave the shades down all day, and expressed fears that people would break into her house. As a result, she became isolated from her neighbors and friends. Shortly thereafter, she made repeated phone calls to the local police and it was apparent that she was confused. After investigation, the police had to break into the house and take her to an emergency room. In the emergency room she was described as confused and frightened. Paranoid ideation was prominent with considerable self-referral ideation. Thought process was described as tangential, with considerable perseveration. There was poor insight and judgment was impaired. She was confused as to time and place and she could recall two of three objects in 5 minutes. She had great difficulty with serial sevens, often losing track of the number to be subtracted. Judgment and insight were poor. She would read a book by rapidly turning the pages, but then had little recall of what she had read. With treatment with haloperidol, lability of mood and paranoia decreased. A CT Scan demonstrated "mild cortical atrophy". The patient was then transferred to a nursing home with a diagnosis of Alzheimer's Disease. In retrospect, a gait problem had also been present in January 1984, about the time that her symptoms had begun, and prior to the use of haloperidol. The patient was walking flexed with small steps. These gait problems progressed so that she was unable to stand up from a chair and was unable to walk. She had become fearful of walking.

Family History - Indicated parents died at ages 70-80 years, without neurological disease. A sibling was age 79 without neurological disease.

Neurological examination:

1. *General:* A thin female appearing older than her stated age. She sat in a wheelchair with little facial expression and with little body movement. She was passive in the interview situation -allowing her husband to provide many answers.

2. *Mental Status:* She was oriented to the year but when requested to provide the month and day, she answered "it is the beginning of school time". As regards the location, she gave the name of the town where she formerly lived but could not name the town where the nursing home was located. She did name the nursing home and then said "its a jazzy place with more facilities, most of the people there are nice, some just sit around".

Asked to describe herself, she said, "I am nothing, I can't even take care of my child". She was, however, able to provide the name of her only daughter, now grown, and was able to indicate that the daughter had been born in 1945 in Philadelphia (all of which the husband verified as correct).

Asked to indicate her own birthplace and birth date, she indicated she herself had been born at home in Fitchburg in 1925 and then added, "I imagine everything has been tossed out there". When I asked "what had been tossed out?", she provided a tangential answer, "I do not know you" and then rambled on to a conversation topic about her husband's trip to Turkey on a "Fulbright" - some time in 1960 or 1970.

Delayed recall even with multiple choice assistance was zero out of five in five minutes. For serial seven subtractions, 100 - 7 "might equal 86 or might equal 55". She could name 3 out of 5 objects, could do repetitions, could write her name but not her address and refused to draw a house (? unwilling, ? unable).

3. *Cranial Nerves:* Intact except for a tremor of the closed eyelids and a positive glabellar sign. There was a lack of facial expression.

4. *Motor System*: Strength was difficult to assess, but appeared intact when maximal effort was made. Significant akinesia and bradykinesia were present. There was cogwheel rigidity of minor degree at wrist and elbow. There was variable resistance at hip and knee, which had primarily the character of frontal lobe type "Gegenhalten".
The patient had to be assisted to the standing position from her wheelchair. In the standing position, initially, her feet appeared to be stuck to the floor, as in a magnetic foot syndrome. Eventually, she was able to take small shuffling steps, as assistance was provided by holding her outstretched hands lightly. If unsupported, she tended to fall backwards - whether standing or walking.
 5. *Reflexes*: Deep tendon reflexes were physiologic at 2+ except for Achilles - 1+. Plantar responses were equivocal. There was marked release of the grasp reflex.
 5. *Sensory system*: Pain and vibration were intact. Position sense could not be tested.
- Clinical diagnosis:** Lewy body dementia , or a variant of frontal dementia.

Laboratory data:

1. *Metabolic surveys* were not remarkable in terms of electrolytes, BUN, creatinine, glucose, hepatic functions, vitamin B12, folate levels and thyroid functions.
2. Routine serum serological test and FTA absorption for syphilis were negative.
3. *Sedimentation rate* was moderately increased to 53 mm/hr. *Alkaline phosphatase* was elevated to 272 and bone scan suggested possible Paget's Disease.
4. *EEG* demonstrated a slow dominant awake activity of 6-7 Hz (compared to normal alpha rhythm of 8-13 Hz). In addition, rhythmic bilateral delta slow wave were present, most prominent in the frontal recording areas.
5. *CT Scan*, demonstrated marked cortical atrophy with enlargement of sulci, ventricular system and cisternal spaces.

Subsequent course:

The patient continue a slowly progressive course to the present time. According to her primary physician, she is essentially restricted to bed. She remains, from a medical standpoint, relatively clear of other medical problems and complications - at age 67, 13 years after onset of the disease.

Comment: The diagnosis in this case is uncertain . The patient at age 54 had the onset of a significant change in behavior which resulted in major problems in interpersonal relationships. Initially, she had been able to live by herself in her small seaside community. Eventually, however, the frequent night calls to friend, neighbors, and the police, resulted in her coming to medical attention. Even at that point, the patient's separated husband, who visited her frequently and supported her, appeared unaware of the patient's confusion and memory deficit. The husband had considerable difficulty appreciating the degree of disability. Such a pattern is not unusual.

In contrast to the previous case histories of this chapter, the memory problems were far beyond the selective involvement of recent memory seen in Wernicke's or hippocampal lesions. Moreover, a more diffuse involvement of other cognitive functions was present. As the disease progresses, motor aspects become prominent, indicating the effects of involvement of frontal and premotor areas. Mild "Parkinsonian" features may appear, due to either the medications employed (neuroleptic agents such as pheno thiazides, haloperidol, etc.) or to alterations in the frontal premotor basal, nuclei circuits or to loss of neurons, at the level of S. nigra or basal nuclei. Note however that the gait problems occurred prior to the use of haloperidol. The CT scan did not demonstrate the focal atrophy seen in frontotemporal dementia .Therefore the most likely diagnosis might be diffuse Lewy body dementia since personality changes were most prominent at onset, and Parkinsonian features developed early in the disease course. Contrast this case to the Alzheimer disease patient of case 30-4 in which the initial problems were restricted to changes in memory.

When seen at age 60 this patient was clearly late in her disease course. As indicated, remedial causes of the syndrome of progressive dementia must be ruled out. The effects of medication must be considered. Moreover, however, any masking depression should be treated. At this point in time, no specific therapy to reverse the progressive course of the disease is known.

Case 30-7: This 74-year-old right-handed widow presented to the emergency room at St Vincent hospital on 2-19-02 with an 8-10 week history of worsening memory problems. In December 2001, accompanied by her boyfriend she made her annual trip to Florida. Although she had been in her usual state of independent living prior to her departure, she was found to have serious problems with

memory on arrival. She was unaware as to where she was. In a telephone conversation with her daughter, “she was talking nonsense”. During the next 2 months, memory and word finding continued to deteriorate. She was taken to the emergency room of the local hospital in Florida where a CT scan without contrast on 02/07/02 demonstrated mild cortical atrophy but no acute process. Her son drove to Florida and found that her memory was poor and her conversation did not make sense. “My husband is in the service: my mother died last year.” However she could play cards with her grand daughter. Her gait was slow and stooped. She had urinary incontinence on her way to the bathroom.

She had no history of alcoholism and took various vitamins and herbs.

Family history: her brother had died of a brain tumor of unknown type.

Neurologic examination: The positive findings were the following:

1. *Mental status:* The patient was awake and alert. Overall Mini-Mental Status Score was 19/30. The major problems were in orientation and in delayed recall. She was able to indicate that she was in a hospital in Massachusetts. And the date was February. She registered 3 objects but could recall any in 3 minutes. She was however able to read, name objects, follow instructions, spell “world” backwards and copy a figure. She was unable to draw a clock with the hands set at 11:10.

2. *Cranial nerves:* intact

3. *Motor system:* Although strength and tone were normal, her gait was broad-based and shuffling.

4. *Reflexes:* Patellar and Achilles reflexes were absent but plantar responses were flexor.

5. *Sensory system:* Intact.

Clinical diagnosis: 1) Subacute dementia: etiology uncertain possibly of Alzheimer’s or Lewy body type. Various entities such as chronic subdurals, tumor etc to be ruled out 2) Peripheral neuropathy, most likely etiology at this age diabetes mellitus.

Laboratory data:

1. *Basic CBC and chemistries:* Normal except for an elevated fasting glucose.

2. *CT scan (Fig 30-10):* An enhancing 2.75 cm tumor with a necrotic center was present in the thalamus at the level of the upper third ventricle. There was bilateral involvement of the anterior and medial thalamus but with no involvement of the posterior thalamus or hypothalamus. The study suggested a lymphoma or glioblastoma

Subsequent course *Stereotaxic biopsy of the right thalamus:* Frozen section raised the question of a lymphoma or glioblastoma but special immunological stains were consistent with a glioblastoma. Necrosis and endothelial hyperplasia were present. The patient was treated with dexamethasone and radiotherapy with improvement in gait.

Comment: This patient presents an unusual cause of a progressive alteration in memory. As indicated earlier in this chapter those patients with Wernicke’s encephalopathy who progress to the Korsakoff syndrome had persistent pathology in the medial and anterior thalamus with sparing of the posterior thalamus. In this case the pathology was a rapidly progressive glioblastoma multiforme. As discussed above, an occasional patients, glioblastomas may also produce dementia and a change in personality by infiltrating the prefrontal areas and corpus callosum. Occasionally a patient with a more diffuse neoplasm gliomatosis cerebri may also present with a similar syndrome of dementia which may mimic Alzheimer’s disease. These are however rare causes compared to the more frequent degenerative disorders.

COMPLETE CASE HISTORIES FROM TEXTBOOK: *INTEGRATED NEUROSCIENCES*
PART IV. CASES; CEREBRUM VISION, DISEASES, MEMORY

CHAPTER 23: VISUAL SYSTEM

The following case is an example of a lesion involving the optic nerve, anterior to the optic chiasm.

Case History 23-1 (Fig 23-8).

This 53-year-old white right-handed housewife was referred for evaluation of progressive right-sided supraorbital headache of 23 years duration and decreasing acuity in the right eye. The loss of acuity had progressed to the point of almost total unilateral blindness. During the 3 years before admission, intermittent tingling paresthesia had been noted in the left face, arm, or leg. About 1 year before admission the patient had a sudden loss of consciousness and was amnesic for the events of the next 48 hours. She was hospitalized, but no explanation for the episode was clearly established, although cerebrospinal fluid protein was reported to be elevated (230 mg/dl).

The patient and her family reported some personality changes over a period of several years, including a loss of spontaneity and increasing apathy.

General Physical Examination: Unremarkable except for a minor degree of proptosis (downward protrusion of the right eye).

Neurologic Examination:

1. *Mental Status*: The patient was, in general, alert but at times would become lethargic. Her affect was flat. At times, she would laugh or joke in an inappropriate manner.
2. *Cranial Nerves*: There was anosmia for odors, such as cloves, on the right and a reduced sensitivity on the left.

Marked papilledema (increased intracranial pressure with protrusion of the optic disk and venous engorgement due to obstruction of the normal flow of CSF) was present in the left eye.

Pallor of the right optic disc was present, indicating optic atrophy. Visual acuity in the right eye was markedly reduced. The patient had only a small crescent of vision in the temporal field of the right eye, where only vague outlines of objects could be seen. A slight left central facial weakness was present.

3. *Motor Systems*: Intact although movements on the left side were slow.

4. *Reflexes*: A release of grasp reflex was present on the left side.

5. *Sensory system*: Intact

Clinical diagnosis: Subfrontal meningioma arising from olfactory groove or inner third sphenoid wing.

Laboratory data:

1. *Skull* x-rays demonstrated erosion of the dorsum sellae. Special lamniograms demonstrated hyperostosis of the sphenoid bone (planum sphenoidale) suggesting a meningioma originating from the sphenoid bone.

2. *EEG* demonstrated focal 2-4 Hz slow waves in the right anterior temporal and anterior lateral frontal area.

3. *Brain scan (Hg 197)* revealed a heavy uptake of isotope in the right posterior subfrontal area.

4. *Arteriograms* indicated that the anterior cerebral arteries were shifted backwards, posteriorly and the left. A tumor blush was present on the venous phase in the right subfrontal area extending back to the optic nerve groove (Fig 23-8). These findings were felt to be most consistent with an olfactory groove meningioma.

Hospital course: Dr. Samuel Brendler performed a bifrontal craniotomy which exposed a well-encapsulated smooth tumor attached to the medial third of the sphenoid wing. After intracapsular removal of 90 to 95% of the tumor, the right optic nerve could be visualized. The small portion of the tumor attached to the bone could not be removed because of considerable bleeding from the bone. Examination 4 months after surgery, indicated right anosmia and right optic atrophy were present.

Comment

If one considered only the patient's primary complaint, decreasing vision in the right eye, and the findings of right optic atrophy and left-sided papilledema (Foster-Kennedy syndrome), then the most probable diagnosis was inner-third sphenoid meningioma. The preservation of a small crescent of vision in the temporal field is consistent with compression of the optic nerve on its lateral surface. By the time of hospitalization, the lesion was quite large and had extended into the subfrontal area, producing anosmia on the right and some changes in personality. At this point, the various diagnostic studies suggested only a subfrontal mass and did not clearly differentiate between an olfactory-groove meningioma and a sphenoid-wing meningioma. One might suggest, in retrospect, that the degree of involvement of the right optic nerve was much more pronounced than the changes in prefrontal functions, and therefore, the inner-third sphenoid-wing location was more likely.

The surgical approach in any case was the same. The eventual recovery of vision in such cases is uncertain because the effects of compression often are not reversible.

The following case 23-2 provides an example of a macroadenoma of the pituitary producing a bitemporal adenoma..

Case 23-2. Patient of Dr. Martha Fehr. This 45-year-old man had an 18-month history of a progressive alteration in vision. He was unable to see objects in the right or left periphery of vision. He was concerned that in the process of driving he might hit pedestrians stepping off the sidewalks in the periphery of vision. He had also experienced over 6-8 months, progressive headaches, loss of energy and libido.

Neurological examination: Normal except for a bitemporal hemianopia.

Clinical diagnosis: Pituitary adenoma compressing the optic chiasm.

Laboratory data:

1. *Endocrine studies:* all were normal including prolactin, am cortisol, and thyroid functions.

2. *MRI:* A large macroadenoma measuring 3 cm in diameter extended outside of the sella turcica to compress the optic chiasm (fig. 23-11).

Subsequent course: Dr. Gerald McGuillicuddy performed a gross total trans sphenoidal resection of the tumor, with a significant improvement in vision. Three years later, the patient again had visual symptoms and eye pain. MRI scans indicated regrowth of tumor with possible impression on the right optic nerve. He was treated with radiotherapy.

Comment: Note that males are more likely to present with large pituitary adenoma compressing the optic chiasm. Women are more likely to present with microadenomas or small macroadenomas since they are more likely to be seen at an earlier stage due to an initial complaint of amenorrhea. Thus complaints of decreased libido in men are likely to be mentioned only in retrospect and not as an early presenting complaint.

The following case illustrates the effects of a space-occupying lesion in the occipital lobe. One should compare these findings to those reported earlier in Case 23-1, in which there was a lesion in the visual system anterior to the optic chiasm.

Case 23-3: This 47-year-old white, right-handed, real estate salesman was referred for evaluation of headache and visual disturbance. One month before admission the patient had a cough with some blood present in the sputum (hemoptysis). Five days before admission the patient developed a generalized headache, which was

precipitated by coughing or straining and which awakened him or prevented him from sleeping.

Two days before admission, the patient noted blurring in the left inferior quadrant of his field of vision.

The day before admission, he noted complete loss of vision in this quadrant. On the day of admission, the headache increased, and the patient was unable to see anything in the left visual field.

He had experienced no weakness, no disturbance of memory, and no language disturbance.

Past history was significant. The patient had multiple pulmonary infections, treated with antibiotics.

Neurologic examination:

1. Mental status: Intact

2. *Cranial nerves* were intact, except that blurring of disc margins was present bilaterally, with venous engorgement, indicating early papilledema.

A left non congruous homonymous hemianopia was present (Fig. 23-14A).

3. Motor system: Intact

4. Reflexes: *Deep tendon reflexes were slightly more active on the left. The plantar response on the left was extensor that on the right was flexor*

Laboratory data:

1. *Electroencephalogram* was abnormal because of frequent focal 3 to 4 cps, slow waves in the right occipital area and to a lesser degree, in the right posterior parietal area, consistent with focal damage in the right occipital area.

2. *Cerebrospinal fluid* pressure was elevated to 210 mm H₂O. The number of white blood cells was increased to 97 lymphocytes (upper normal limit is 5 to 7 lymphocytes). Protein was increased to 75 mg/dl (upper normal limit is 45 mg/dl). Glucose was 75 mg/dl (normal when compared to blood sugar of 95 mg/dl).

3. *Imaging* (radioactive brain scan Hg 197) demonstrated an enhanced region in the posterior and medial aspect of the right hemisphere (occipital and adjacent parietal lobes).

Subsequent course: The patient was treated with antibiotics (cephalothin sodium, penicillin, and streptomycin). Visual fields, EEG, and spinal fluid findings improved. Within 3 weeks the field defect had resolved to a non congruous left inferior quadrantanopia (Fig. 23-14B).

Ten days later the patient was readmitted to the hospital with a three-day history of right eye pain, sweats, and chills. Neurologic examination now revealed a recurrence of blurred optic-disc margins, a left homonymous hemianopia and a slight increase in deep tendon reflexes on the left. Imaging studies now revealed a large space-occupying lesion in the right parietal/occipital region, displacing the right lateral ventricle forward and downward.

After 10 days treatment with antibiotics (penicillin and streptomycin), a craniotomy was performed by Dr. Bertram Selverstone. A mass could be palpated medially in the right occipital and adjacent posterior parietal area. The abscess and a large surrounding area of hard granulomatous cortex and white matter were removed. (The etiologic organism was subsequently found to be a *microaerophilic streptococcus*.)

Postoperatively, the patient continued on treatment with penicillin. Follow-up examination 6 months after surgery was normal, except for the left homonymous hemianopia (Fig. 23-14C).

Comment: The rapid evolution of neurologic signs and symptoms in this case; the early development of papilledema, and the progressive changes in the electroencephalogram and brain scan; is consistent with the diagnosis of brain abscess. The primary infection in this case was probably in the lung.

The initial visual symptoms of inferior field involvement (quadrantanopia) suggested that the abscess, in its early stages, involved predominantly the superior portion of the optic radiation in the posterior parietal/occipital area or the superior bank of the calcarine fissure. With progression of the lesion, the entire optic radiation or the entire calcarine cortex was involved. The lesion found at surgery had destroyed or damaged both these areas.

The treatment of a brain abscess requires appropriate pre- and postoperative use of antibiotics. Many of these patients develop focal seizures at some time after successful surgical treatment of the abscess. Although prophylactic anticonvulsant medication, such as diphenylhydantoin (Dilantin), has been routinely administered, the value of such treatment remains unclear.

Note an important negative finding in this case: at no time did the patient experience any language disturbance. Reading and writing remained intact, as did the capacity for to construct drawings. This case involving the right occipital lobe should be compared with Case History 21-2, in which a focal lesion of the left occipital lobe was present.

The following is another example of the effects of a lesion in the occipital lobe with very different consequences than those seen in the previous case. The lesion clearly involved the cerebral cortex producing focal seizure activity.

Case 23-4. (Fig 23-15): This 18-year-old left-handed single white female restaurant employee was referred for reevaluation of a seizure disorder. While living in the south western United States, the patient had the onset of her seizures at age 14 when she had a sequence of five seizures in less than 12 hours. Each began with flashing lights, “like Christmas tree lights,” all over her visual field, plus the sensation that peoples’ faces were moving. She then would have an apparent grand mal seizure.

She was hospitalized. The neurological examination was reported as normal. An electroencephalogram report noted occasional focal sharp and slow waves in the left hemisphere. The CT scan was interpreted as essentially within normal limits. In retrospect, there was a question of some mottled hypodensity in the left occipital area, not clearly distinguished from artifact. The patient was treated with carbamazepine (Tegretol), 400 mg in the morning, and 230 mg at hour of sleep. In the interim, she apparently had done quite well with no additional grand mal seizures. She had rare episodes of “fear attacks,” which would last 23 to 25 minutes. The last attack had occurred 2 years ago, but as recently as two months ago, she had had one episode of flashing lights. A recent EEG was normal.

Past history was negative, except her birth weight was ten pounds, three ounces, and there was a problem of breathing at birth. She had always done poorly in school. Her family history did not suggest possible causes for a seizure disorder.

Neurologic examination: Normal.

Clinical diagnosis: Seizures of focal origin occipital cortex, (flashing lights and movement of the lights) probably left hemisphere based on the reports received of the EEG. There was subsequent spread of discharge into the temporal lobe based on the report of “fear attacks”

Subsequent course

The patient did well for 3 years then had a recurrence of a generalized convulsive seizure possibly related to omission of medication. Six weeks later, she reported two additional episodes characterized by flashing lights, then movement of the lights away from a center circle, then dizziness, then a

sensation of unreality. She also had other episodes of feeling unreal accompanied by fear. There were no olfactory hallucinations and no other visual or auditory hallucinations. The neurologic examination now demonstrated a minor right central facial weakness not present previously.

Laboratory data:

1. *EEG*: remained normal.
2. *MRI scan*: now revealed a small tumor at the left occipital pole with surrounding edema (Fig. 23-15). On CT scan, this tumor appeared partially calcified but did show enhancement. Angiograms suggested tumor vascularity of a type seen with meningiomas.

Subsequent course: Dr. Bernard Stone removed a discrete encapsulated tumor that appeared to be a meningioma. Subsequent microscopic examination, however, indicated a rare type of indolent follicular adenocarcinoma of the thyroid, which sometimes spreads as a single lesion to brain and remains quiescent for many years. In the postoperative period, a non-congruous right-inferior-field defect was present (partial quadrantanopia). The blood level of thyroid-stimulating hormone (TSH) was elevated. A thyroid nodule was found. A thyroidectomy was performed, and thyroid replacement medication was prescribed. No additional seizures were observed over the next 18 months. A metastatic lesion in the lumbar vertebral body subsequently appeared.

Comment: This patient presented many of the features of focal seizures arising in the occipital cortex: flashing lights, movement of objects and secondary generalization. Some of the seizure phenomenology such as “fear attacks,” dizziness, and “feeling unreal” suggested that spread into the temporal lobe was sometimes occurring. The student should now compare and contrast the cases presented in the previous chapter on the limbic system to this case to be able to note the differences seen after lesions in these adjoining cortical regions.

CHAPTER 24: SPEECH, LANGUAGE FUNCTION, APHASIAS, AGNOSIAS, APRAXIA

The following case, 24-1 presents an example of a selective non fluent aphasia of aphasia. An embolus to the superior division of the left middle cerebral artery produced marked weakness of the face tongue and distal right upper extremity and a severe selective nonfluent aphasia. The

hand weakness rapidly disappeared, the right central facial weakness, an apraxia of tongue movements and some expressive difficulties persisted.

Case 24-1: This 55-year-old, right-handed white housewife while working in her garden at 10:00 a.m. on 04-15-69, the day of admission suddenly developed a weakness of her right side and was unable to speak. Apparently, the right-sided weakness affected predominantly the face and arm since the patient was able to walk. The past history was significant. In 1960, nine years previously, the patient had been admitted to the hospital with a three-year history of progressive congestive heart failure secondary to rheumatic heart disease (mitral stenosis with atrial fibrillation). An open cardiectomy was performed with a mitral valvuloplasty (the valve opening was enlarged). A thrombus found in the left atrial appendage was also removed. Postoperatively, the patient was given an anticoagulant, bishydroxycoumarin (Dicumarol). Although atrial fibrillation continued, she did well until the day of admission. Prothrombin time at the time of admission was close to normal; that is, the patient was not in a therapeutic range for anticoagulation.

General physical examination: Blood pressure was moderately elevated to 170/80. Pulse was 110 and irregular (atrial fibrillation). Examination of the heart revealed the findings of mitral stenosis: a loud first sound, a diastolic rumble and an opening snap at the apex as well as the atrial fibrillation.

Neurological examination:

1. Mental status and language function:
 - a. The patient was alert.
 - b. She had no spontaneous speech and could not use speech to answer questions and could not even use yes or no to provide answers. She could not repeat words.
 - c. The patient was, however, able to indicate answers to questions by nodding (yes) or shaking her head (no), if questions were posed in a multiple choice situation. In this manner it was possible to determine that she was grossly oriented for time, place and person.
 - d. The patient was able to carry out spoken commands and simple written commands, such as, "hold up your hand, close your eyes." However, she had significant difficulty in performing voluntary tongue movements (such as "wiggle your tongue"; "stick out your tongue") on command.
2. Cranial nerves:
 - a. The patient tended to neglect stimuli in the right visual field.
 - b. She was unable to look to the right on command although the head and eyes were not grossly deviated to the left at rest.
 - c. A marked right supranuclear (central) type facial weakness was present.
 - d. The patient had difficulty in tongue protrusion. When the tongue was protruded it deviated to the right. The patient was unable to wiggle the tongue.
3. *Motor system:* Strength: there was a marked weakness without spasticity in the right upper extremity, most prominent distally. Some shoulder movements were possible; no hand or finger movements could be made. There was a minor degree of weakness involving the right lower extremity (75 percent of normal).
4. Reflexes:
 - a. Deep tendon stretch reflexes were increased on the right in the arm and leg.
 - b. Plantar responses were both extensors; more prominent on the right.
 - c. The abdominal reflex was absent on the right; present on the left.
5. Sensory:
 - a. Pain, touch and vibration were intact.
 - b. It was difficult to test other modalities but tactile localization appeared to be intact.

Clinical diagnosis: Embolus from heart to left middle cerebral artery

Laboratory data:

1. *Skull X-rays* were normal.
2. *EEG* was normal (48 hours after admission).
3. Cerebrospinal fluid was normal.
4. *Electrocardiogram* revealed atrial fibrillation

Hospital course: Within 24 hours a significant return of strength in the right hand had occurred; independent finger movements could be made. Within 48 hours after admission the patient was able to

repeat single words but still had almost no spontaneous speech. She appeared aware of her speech disability and would manifest some frustration. She was able to carry out two- or three-stage commands although tongue movements and perseveration remained a problem. Within 6 days of admission the patient used words, phrases and occasional short sentences spontaneously. She was better able to repeat short sentences. At this time strength in the right arm had returned to normal, but a right central facial weakness was still present. More detailed language evaluation two weeks after admission indicated the persistence of expressive disabilities consisting of word-finding and apraxic components. The apraxic components were evident on tongue placement and alternating tongue movements. Although complete sentences were used, sentence formulation in spontaneous speech was slow and labored with word finding difficulties. Repetition was better performed. In reading sentences aloud, substitutions or word omissions were made. The patient did well in naming common pictures and in matching printed words to spoken words or printed words to pictures. She could write from dictation and would often respond preferentially in writing when difficulty in speaking was encountered. No left-right confusion was present. Minor difficulties with simple arithmetic were reported. A right central facial weakness was still present.

Comment: There would appear little doubt that this patient had the sudden passage of an embolus (presumably from the left atrial appendage) into the left middle cerebral artery. In view of the selective face and arm weakness with a predominant expressive aphasia, the involved vessels must have been cortical branches such as the prerolandic and rolandic originating from the superior division of the middle cerebral artery. From the onset, it was clear that although some receptive components might be present, these were minor. The major problem was a severe nonfluent aphasia. As the hand weakness disappeared, the only other residual neurological findings were those of a right central facial weakness and an apraxia of tongue movements. Such findings would, of course, be consistent with a relatively selective involvement of Broca's area in the inferior frontal gyrus.

Why did such a rapid improvement occur in motor function and of the visual field? Most likely, the embolus fragmented and passed into the cortical branches supplying Broca's area.

With the passage of time, this type of patient would continue to show some degree of improvement (Mohr, 1973). Improvement could continue to occur over a two-year period. Although lesions of Broca's area may produce the acute onset of a nonfluent aphasia, rapid amelioration of the deficit occurs even when the acute lesion involves underlying white matter, as well as the superficial cortex.

In the following case 24-2, a more persistent anterior aphasia is demonstrated.

Case 24-2: On May 30, 1985, at midday, this 37-year-old right-handed woman with a past history of rheumatic fever, rheumatic heart disease and "an irregular pulse"(atrial fibrillation) had the sudden onset of loss of speech, central weakness of right face, an inability to protrude the tongue and a right hemiparesis. Although hemiparesis, face and tongue problems disappeared within a week, recovery of speech was slower and limited. At one week, she could produce some two syllable words.

Neurological examination at 17 months revealed the following residual findings:

1. *Language function:* Spontaneous speech was slow and relatively scanty. She could name objects slowly without difficulty, could do some simple repetitions and could write from dictation. She could carry out two and three stage commands. She could read slowly aloud but had little comprehension of what she read.
2. *Reflexes:* A residual right Babinski sign and right-sided hyperreflexia were present.

Clinical diagnosis: Anterior aphasia: embolic infarct of superior division of middle cerebral artery.

Laboratory data:

Although initial CT scans in May 1985 had been reported as negative; the MRIs in November 1986 and June 1990 demonstrated the infarct which included Broca's area, as well as adjacent frontal areas with predominant involvement of frontal operculum (inferior frontal gyrus) and adjacent middle frontal gyrus. In addition, a minor independent infarct was present in right occipital area (presumably embolic to the calcarine artery).

Subsequent course: Similar findings were present at 5 years, June 1990).

A brain section from a patient (Case 24-3) with a persistent nonfluent aphasia (is presented in Figure 24-4.

Case 24-3: This 69-year-old, right-handed male expired in 1965. In 1961 and 1963, The patient, had experienced transient episodes of right hemiparesis and aphasia, both followed by complete recovery. In 1964, a more persistent right hemiparesis and aphasia had developed.

General physical examination: No left carotid pulsation was present.

Neurologic examination(1965):

1. **Language functions:** Speech was nonfluent with only a small verbal output. A significant nominal aphasia with paraphasias was present. Reading was limited. Comprehension of spoken language was good. A marked apraxia was present for movements of tongue, lips and hands.
2. **Motor system:** Right hemiparesis with associated reflex findings.
Post mortem findings: Left carotid occlusion with old infarction, predominantly of left middle cerebral territory with lesser involvement of anterior cerebral territory. Note that minor cortical infarcts are also present involving cortex of right hemisphere.
(Courtesy of Dr. John Hills,; and Dr. Jose Segarra.)

Case 24-4 provides an example of a patient with a Wernicke's type aphasia

Case 24-4: This 40-year-old, right-handed white male had experienced a series of myocardial infarctions beginning 10 months prior to consultation. Angiographic studies indicated occlusion of the right coronary artery and the left anterior descending coronary artery with stenosis of the circumflex artery. The patient was subsequently admitted and a coronary artery bypass procedure was performed using extracorporeal circulation. Although the patient was stated to have tolerated the procedure well, the anesthetist noted that the patient was nonreactive 15minutes after the last administration of halothane anesthesia. When the patient did wake up, he was quite agitated requiring the use of agents to reduce agitation. Throughout the postoperative period, the patient continued in a disoriented and combative manner. Because of the patient's acutely psychotic state, transfer to the psychiatry service was actively planned. Because there were certain organic features to the patient's illness, a neurological consultation was obtained. The neurology resident in reviewing the progress notes discovered a notation that shortly after surgery the patient had transient difficulty in using his right arm.

Neurological examination:

1. **Mental status:**
 - a. The patient was an alert but agitated white male. Additional inquiries indicated that his agitation related to his inability to write a letter to his mother.
 - b. The patient's speech was fluent and usually grammatical. He made use of many paraphasias and neologisms (nonsense words). He often appeared unaware of his errors.
 - c. The patient was unable to name single objects such as pencil, cup, and spoon though he could recognize and demonstrate their use.
 - d. The patient could read occasional individual words; for example, cat, house. He could not comprehend or carry out, either spoken or written commands.
 - e. His attempts at spontaneous writing produced only a few letters. He was unable to write words or phrases from dictation. He did significantly better when asked to copy a printed sentence or phrase.
- f. Repetition of spoken phrases or sentences was poor.
- g. Calculations of even a simple nature were poorly performed.
2. **Cranial nerves:** II-XII was intact.
3. **Motor system:** No actual weakness was present. Gait was intact.
4. **Reflexes:**
 - a. A minor increase in deep tendon stretch reflexes was present on the right side.
 - b. The plantar response on the right was equivocal. The left was flexor.
5. **Sensation:** Pain, touch and vibration were intact.

Clinical diagnosis: Wernicke's type of fluent aphasia probably secondary to an embolus to the inferior division of the middle cerebral artery.

Comment: This patient who was seen before the era of modern neuroimaging provides an example of the clinical picture described by Wernicke. The use of the heart pump for open-heart surgery was associated with a high incidence of cerebral

emboli. The incidence of this complication has decreased as technical advances have been made and as “time on the pump” has decreased. As we have stressed, for solving neurological problems, the details of the history are important if the appropriate diagnosis is to be made. In the patient who is unable to provide a history, the careful review of progress notes and of nurses notes will often provide the clue that allows diagnosis.

The following case history 24-5 demonstrates such a sequence of involvement in a tumor infiltrating the posterior temporal inferior parietal area starting with a conduction aphasia.

Case 24-5: This 42-year-old right handed truck driver noted fatigue and irritability 6-8 weeks prior to admission. Three to four weeks prior to admission, he noted he was using words which he did not mean to use and certain words would not come to him. He had two generalized convulsive seizures; each proceeded by a ringing sensation in the ears, during the week prior to admission.

Neurological examination:

1. Mental status and language function

- a. The patient was alert and oriented to time, place and person.
 - b. He was cooperative and able to carry out the four-step command: “stick out your tongue, close your eyes, hold up your hand and touch the thumb to your ear”. There was however evidence of a significant left-right confusion when laterality was introduced e.g. “left hand to right ear”.
 - c. The ability to do even simple calculations was markedly impaired with or without paper e.g. $100-9=99$.
 - d. Memory was impaired; with immediate recall object recall limited to 2/5 objects and delayed recall in 5 minutes limited to 0/5. Digit span was limited to 2 forward and 0 in reverse. (normal would be 7 forward and 6 in reverse).
 - e. There was little evidence of an expressive aphasia. Flow of speech was slow with only minor mispronunciations. Reading was slow but with few errors. The patient’s did have minor difficulty in naming objects-a mild nominal aphasia. The patient’s greatest difficulty was in repetition of simple test phrases. There were moderate defects in drawings of a house and a clock but few errors in copying simple figures. There was a significant dysgraphia with marked difficulty in writing a simple sentence spontaneously or in writing from dictation. On the other hand, the patient was much better able to copy a simple sentence. Significant errors were made in spelling.
2. **Cranial nerves:** All were intact except for a mild right central facial weakness.
 3. **Motor system:** Strength, gait and cerebellar functions were all intact.
 4. **Sensory system:** Pain, touch, vibration, stereognosis, simultaneous stimulation, graphesthesia, and position sense were all intact, but point localization was impaired on the right side.

Clinical Diagnosis: Fluent posterior aphasia, disconnection syndrome plus elements of Gerstmann’s syndrome (left right confusion, dyscalculia, dysgraphia) plus seizures of focal origin (Heschl’s gyrus posterior temporal lobe) with secondary generalization. All suggested a lesion in the left posterior temporal-posterior parietal area.

Etiology was uncertain but tumor (glioma) or embolus to inferior division of left middle cerebral artery possible.

Laboratory data:

1. Skull and chest x-rays were normal.
2. **EEG:** Focal 4-5 Hz slow wave activity was present in the left parietal and posterior temporal areas.
3. **Brain scan (radioactive Hg 197):** Increased up take of isotope in the left posterior temporal –parietal area measuring 4x5 cm.
4. **Left carotid arteriogram:** Vascular mass in the region of the angular gyrus with tumor stain in the area.

Subsequent course: Papilledema soon developed and Dr. Robert Yuan performed a craniotomy. Although the cortex appeared externally normal, a firm mass could be palpated

slightly above and posterior to the angular gyrus. At 2 cm below the surface, firm yellow tumor tissue was encountered. All visible tumor and adjacent cortex of the angular and supramarginal gyri were removed and a partial left temporal lobectomy was performed. Histologic examination indicated a highly malignant glial tumor with active mitosis and necrosis (a glioblastoma multiforme). Post operatively, the patient had a marked expressive and receptive aphasia. By 30 days after surgery, the patient had a significant improvement in fluency, he continued to have a severe posterior type of aphasia. He was unable to carry out simple commands. His speech was incoherent, with nonsense words and neologisms. He appeared unaware of his errors and did not appear frustrated by his failure to follow commands. In addition to this Wernicke's type aphasia, the patient was unable to repeat words of two syllables. He could do no calculations, had severe difficulties in copying drawings and was unable to even write his name. The patient received radiotherapy but his condition continued to worsen with the development of a progressive expressive and receptive aphasia and hemiparesis all suggesting the spread of a rapidly growing glioblastoma. Coma, pupillary changes and respiratory changes then intervened suggesting the effects of herniation of the residual temporal lobe. Death occurred 7 months after onset of symptoms, and 5 months following surgery.

Comment: The early language and mental status disturbances in this patient were most severe in those tasks requiring repetition. Thus the patient could repeat no more than two digits, was unable to repeat any of the test phrases and was unable to write from dictation at a time when he could copy a sentence. Any expressive aphasia was minor, and he was fluent. He had no evidence of Wernicke type aphasia, since he could carry out a four-stage command without difficulty. Reading was relatively well preserved compared to writing, calculations and drawing construction. All of these findings suggest (1) the speech reception Wernicke's area was disconnected from the motor association areas for speech and writing Broca's areas 44,45 and the related areas of the premotor cortex and (2) the inferior parietal areas associated with writing, calculations, drawing, and the ability to distinguish left and right were damaged. The lesion found at surgery was deep to the angular and supramarginal gyri, the location of the arcuate sulcus. The seizures that finally brought the patient to neurological attention were originating in Heschl's gyrus of the temporal lobe, which would be adjacent to the area of the tumor.

The clinical state at 30 days following surgery reflected the additional effects of ablation of the Wernicke's area as well as the accentuation of the preoperative state. There had been the transient appearance of an expressive aphasia probably reflecting minor effects of the procedure on Broca's area.

The neurosurgical approach to the management of a glioblastoma particularly those involving the speech areas of the dominant hemisphere have changed in 35 years since this patient was seen. A limited stereotaxic biopsy under CT scan guidance would be undertaken and the patient would then be treated with dexamethasone and radiotherapy. The end results would have been similar and actually may even have occurred earlier. The postoperative quality of language function may have been transiently better. Unfortunately this patient had a very malignant and aggressive tumor. The median survival of glioblastomas with surgery alone is 26 weeks, with the addition of radiotherapy; 52-60 weeks. Median means that 50% of patients are going to survive less than these median figures.

The following case (24-6) provides a case of posterior aphasia with the lesion documented with CT scan.

Case 24-6: This 57-year-old female, with a long history of hypertension in the summer of 1985, had a brief episode of difficulty in word finding and a more prolonged episode in December 1985 with confusion, "visual problems", "inappropriate speech and difficulty finding the appropriate words". Following an additional episode in March 1986, she had persistent problems in reading and apraxia of the right hand.

Neurological examination (May 1986): The following abnormalities were present:

1. *Language function:* Spontaneous speech was usually quite fluent. She described the room, the environment and her friend. In contrast, capacity for repetition was very poor both as regards spoken and written speech. Spontaneous writing was very poor except for name and address

Reading to herself aloud was poor with little comprehension. She was able, however, to follow single one stage spoken or written commands but unable to do a sequence of commands. Naming of objects was well performed.

2. *Cranial nerves*: Extinction occurred in the right visual field for bilateral simultaneous stimuli.
3. *Motor system*: No hemiparesis was present.
4. *Reflexes*: Right-sided hyperreflexia and a right Babinski sign were present.

Clinical diagnosis: Posterior aphasia, infarction left posterior temporal and parietal areas, probably due to embolic occlusion of inferior division of the left middle cerebral artery.

Laboratory data:

1. *CT scan*: Infarct left posterior temporal and parietal areas (Fig. 24-6).
2. *Angiograms*: Occlusion of the left internal carotid artery. All anterior and middle cerebral artery branches filled from the right carotid. An artery to artery embolus was presumed.

The following case 24-7 would suggest this type of unilateral lesion producing a transient and partial but selective type of dyslexia.

Case 24-7: Seven days prior to admission, following a period of athletic activity, this 15-year-old, right-handed white male high school student had the onset of a 48-hour period of sharp pain in the left jaw and the supraorbital area. The next day the patient began to complain of blurring of vision and the following day had the onset of vomiting. Four days prior to admission, the patient noted that he was unable to read and to translate his Latin lessons. No definite aphasia was apparent. Two days prior to admission, the patient had the sudden onset of severe left facial pain, accompanied by tingling paresthesias of the right leg. The patient became stuporous and then unresponsive for approximately 90 minutes. An examination of spinal fluid at that time revealed pressure elevated to 290 mm of csf with 250 fresh blood cells.

Neurological examination:

1. *Mental status*: All aspects, including language function were intact.
2. *Cranial nerves*:
 - a. Examination of the fundus showed several small flame shaped hemorrhages. Visual fields were intact.
 - b. A slight, right, supranuclear-type (central) facial weakness was present.
3. *Motor system*: Intact
4. *Reflexes*: Deep tendon reflexes and superficial reflexes were symmetrical and physiologic.
5. *Sensory system*: Primary and cortical modalities were intact.
6. *Neck*: A slight degree of resistance was present on flexion of the neck (nuchal rigidity) consistent with the presence of blood in the subarachnoid space.

Clinical diagnosis: Subarachnoid hemorrhage of uncertain etiology. In view of age and the transient dyslexia, and the transient paresthesias of the right leg, an arteriovenous malformation in the left parasagittal parietal-occipital area might be suspected.

Laboratory data:

Arteriograms: An arteriovenous malformation was present in the left occipital region. The main arterial supply was the posterior temporal branch of the left posterior cerebral artery. The malformation drained into the lateral sinus. The posterior portion of the anterior cerebral artery was shifted across the midline, indicating a hematoma as well as the malformation.

Subsequent course: On that evening after his admission, the patient had the sudden onset of a bifrontal headache. For a 2- to 3-minute period, the patient was unconscious with deviation (repetitive driving) of both eyes to the right, and with sweating and slowing of the pulse rate. Over the next two days an increase in blurring of the optic disc margins was noted (early papilledema). Four days after admission, the patient suddenly complained of being unable to see from his right eye. He became restless and agitated. Additional headache and neck pain with numbness of right arm and leg were reported. Examination now disclosed a dense right visual field defect (homonymous hemianopsia). The deep tendon reflexes were now slightly more active on the right. Funduscopic examination suggested that

recent additional subarachnoid bleeding had occurred since new retinal hemorrhages were present. The next day (five days after admission), the patient was noted to have a significant reading disability (dyslexia), although other language functions were intact.

Because of the progressive evolution of neurological findings due to an expanding intracerebral hematoma, Doctor Robert Yuan performed a craniotomy. Blood was present in the subarachnoid space. The left lateral occipital cortical surface had numerous areas of bluish discoloration indicating an intracerebral clot. The main arterial vessel was a lateral and inferior branch of the posterior cerebral artery, bearing no relationship to the calcarine region. The draining vein was located in the occipital-temporal area, close to the tentorium. At a depth of 1 cm, a hematoma of 50 cc of clot was found. The clot extended down to the occipital horn of the lateral ventricle but did not enter the ventricle. The malformation, hematoma and related cerebral tissue of the lateral occipital area were removed. The calcarine area remained intact at the end of the procedure. Over a period of several days, the visual field deficits disappeared.

Detailed language and psychological testing approximately two weeks after surgery indicated that language function was intact except for reading. Oral reading was very slow (4 times slower than normal for a test paragraph), halting and stumbling. Comprehension of the material read was good. Minor errors were made in the visual recognition of letters. This was reflected in occasional errors in spelling. Visual recognition and naming of objects was intact. Auditory and tactile recognition of sounds, words, letters, sentences, questions, commands and so forth was intact. Calculations were intact. No right-left confusion or finger agnosia was present. Writing and drawing were intact but slow. Repetition of speech and spontaneous speech were intact.

Follow-up evaluation at 20 and 30 months indicated that, although the patient was doing well in school, receiving A's and B's with excellent grades in mathematics, he still was described as slow in reading compared to his level prior to illness. No actual errors were made in reading when this was tested.

Comment: The arteriovenous malformation in this case had involved and eventually required surgical removal of the lateral occipital area of the dominant hemisphere. The hematoma in the occipital lobe extending in from the lateral surface to the occipital horn was so located as to compress the optic radiation passing to the calcarine cortex or perhaps even to indirectly compress the calcarine cortex. Such a hematoma would also interfere with association fibers passing from left occipital areas to temporal parietal areas and with callosal radiation fibers passing from the occipital region (area 18) of the right hemisphere to the occipital and parietal areas of the dominant hemisphere. Following surgery, the patient had a relatively good recovery with the minor difficulties in reading; (a selective dyslexia) as perhaps the only indication of any damage to these fiber systems.

The complaint of the patient at the time that the right homonymous hemianopsia appeared was of blindness in the right eye. It is not uncommon for patients to localize field defects in this manner to the eye of the same side. The same may sometimes be true of patients with discharging lesions in the occipital area; the flashing lights and lines may be localized to the contralateral eye rather than to the contralateral visual field.

The episode on the night of admission is of interest because it suggests a focal adverse seizure, in this case presumably originating from areas 18 and 19 of the left hemisphere.

Geschwind (1965) has reviewed many of the previously reported cases of selective dyslexia. It is uncertain whether the information from area 18 of the non-dominant hemisphere passes to the non-dominant angular gyrus and then crosses to the dominant temporal parietal areas or whether these fibers pass instead directly to area 18 of the dominant hemisphere with information then conveyed to the dominant temporal parietal areas. He finally concludes that both pathways are probably operative. The relatively minor nature of the final residual deficit in the present case would be consistent with such multiple pathways. In addition, non-fatal hemorrhages always produce less damage than infarcts of comparable size. Finally, Coslett (2000) has reviewed various recovered pure cases of dyslexia where the right hemisphere may have played a role in reading. Such patients do better with concrete nouns than abstract nouns, verbs and functors (pronouns, prepositions, conjunctions and interrogatives). It should be noted that a relatively selective dyslexia in the absence of a severe general visual agnosia might occur. Geschwind has suggested that whether a general visual agnosia or dyslexia occurs may depend on the degree of disconnection of the dominant speech areas from the parietal and occipital areas of the non-dominant hemisphere. In the patient who already has left occipital cortex damage, dyslexia may require only damage to the splenium of the corpus callosum, whereas visual agnosia may require more extensive damage to the posterior body of the corpus callosum as well. As noted bilateral

visual association lesions (areas 18 and 19) would also produce a visual agnosia. (See also Coslett and Saffran 1989 and Friedman and Albert 1985).

In addition there are patients who have acquired dyslexia which is unrelated to the processing of the visual information input. These patients have a central (rather than the peripheral dyslexia of the pure alexia syndrome discussed above). The central dyslexic patient has an impairment of the “deeper” or “higher” reading functions by which visual word forms mediate access to meaning or speech production mechanisms. This problem is reviewed in detail by Coslett (2000).

Feinberg and Farah (2000) review the general topic of agnosias.

CHAPTER 26: VASCULAR SYNDROMES OF THE CEREBRAL HEMISPHERES

The following case history presents a young adult with severe carotid stenosis and infarction of the territories of both the anterior and middle cerebral arteries.

Case 26-1: This 23 year old right handed female on birth control pills, smoking one pack of cigarettes per day, on June 15, 1985 shortly after intranasal “snorting” of cocaine complained of gradually increasing right sided headache and then fell to the floor with a flaccid left hemiplegia with the head and eyes deviated to the right **Neurological examination:**

1. *Mental status:* The patient denied any illness and could not explain why she was in the hospital.
2. *Cranial nerves:* There was a left homonymous hemianopsia, deviation of head and eyes to the left and a left central facial weakness.
3. *Motor system:* A flaccid left hemiparesis was present.
4. *Reflexes:* deep tendon reflexes were initially depressed on the left side. Plantar responses were extensor bilaterally.
5. *Sensory system* a severe left hemisensory deficit, with a neglect of the left side of space and body was present.

Clinical diagnosis: Total right middle cerebral artery territory infarct.

Laboratory data:

1. *Initial CT Scan* demonstrated hypodensity (infarction in right frontal and parietal areas).
2. *Right carotid angiogram* demonstrated severe stenosis of the supraclinoid segment of the right internal carotid artery with severe stenosis of the M-1 segment of the right middle cerebral artery and multiple areas of narrowing of the remainder of the right MCA. *Left carotid angiogram* indicated only limited cross filling of the distal right middle and anterior cerebral arteries.

Subsequent course: On 6-21-85, 6 days after admission the previously alert patient suddenly developed a decreased level of consciousness and a fixed, dilated right pupil suggesting that tentorial herniation had been produced by severe edema or hemorrhagic transformation of the infarct. CT Scan now demonstrated massive infarction and edema-right anterior and middle cerebral artery territories plus-transtentorial and sub falx herniation (Fig.26-6). With emergency management of the increased intracranial pressure-(monitor and osmotic agents) the patient became more alert and was transferred to a rehabilitation facility.

Comment: This young woman had as a major risk factor, the intranasal snorting of cocaine. The vasospasm induced by this agent was sufficient to produce severe stenosis of the internal carotid and the initial segment of the middle cerebral artery. The multiple areas of narrowing seen in the branches of the MCA may well have represented emboli from these more proximal sources. Whether the severe stenosis of the M1 portion also involved an embolic event from the siphon remains unclear. It is clear that the severe stenosis of the carotid artery produced infarction of both the MCA and ACA territories. In this case there was insufficient cross flow from the left carotid supply to prevent infarction. As we will see in case 26-3 massive infarcts of the MCA territory plus or minus adjacent territories constitute a serious threat to life due to massive edema and or hemorrhagic infarction with the risk of herniation. The use of cocaine and of crack cocaine may be associated coronary or cerebral artery vasospasm. In addition to cerebral infarcts, cerebral hemorrhage may also occur, particularly with crack cocaine.

The following case history concerns a patient with severe stenosis at the carotid bifurcation producing both retinal and hemispheric TIA's.

Case 26-2: This 54-year-old, right-handed, white male had experienced intermittent episodes of blurring and blacking out of vision in the left eye for at least 7 years. Each episode would last 30 to 60 seconds and would occur twice per month. Ten days prior to admission, the patient had the onset of numbness of the right side of the face accompanied by minor weakness of the right face, arm, and leg. There was also a transient difficulty

in speech (possibly dysarthria, possibly difficulty in word finding). Symptoms cleared completely in 45 to 60 minutes with the exception of residual numbness of the right side of the face.

Family history: The patient's mother died of a "stroke" at age 66 years, and his father, of heart disease at age 57.

General physical examination:

- (1) Blood pressure was slightly increased to 160/100 in both arms. Pulse rate and rhythm were normal
- (2) Bruits (murmurs) were present over each carotid artery, but the heart was normal with no murmurs.
- (3) The retinal artery pulsation was easily obliterated by pressure on the globe of the left eye. No significant changes occurred on compression of the right globe.
- (4) Peripheral pulses were poor in the lower extremities.

Neurological examination: Mental status, language function, cranial nerves, motor system, reflexes, and sensory system were all normal except for a minor right central facial weakness.

Clinical diagnosis: Carotid stenosis with retinal and hemispheric TIA's.

Laboratory data:

1. Hemoglobin, serological tests for syphilis, skull and chest x-rays, electroencephalogram, and brain scan were all normal. Cholesterol was elevated to 284 mg%.

2. *Arteriography (aortic arch study)* demonstrated a complete occlusion at the origin of the left internal carotid artery. A right brachial arteriogram demonstrated filling of the left anterior and middle cerebral arteries by cross flow through the anterior communicating artery from the right side. Additional studies also demonstrated filling of the intracranial portion of the left internal carotid artery from the left posterior communicating artery.

Subsequent course: Ten days after that hospital admission, a left carotid endarterectomy was performed by Dr. Allan Callow with a restoration of blood flow following removal of the occlusive lesion (atherosclerosis with recent thrombosis) at the carotid bifurcation.

Comment: The location of disease in the left carotid artery was clearly indicated by the episodes of left eye visual disturbances followed by symptoms on the contralateral side of the body. The development of symptoms in the face, with disturbance of speech is consistent with total occlusion of the carotid artery, with greater involvement of the middle cerebral territory than of the anterior cerebral territory. The fact that this patient, with progressive stenosis of the carotid artery, had symptoms for many years only in the ophthalmic-retinal artery distribution, is explained by the excellent collateral flow into the anterior and middle cerebral arteries from the anterior communicating bypass. In addition collateral flow would enter the common carotid artery from the posterior communicating artery above the take off of the ophthalmic artery.

It should be apparent that the final complex of neurological symptoms and signs, occurring with occlusion of the carotid artery, will depend on the total pattern of cerebral blood flow in the individual patient. In many patients total occlusion of the carotid artery will produce an infarction of that portion of the cerebral hemisphere supplied by the carotid artery (primarily the middle cerebral territory). In others, a benign outcome is the result (Bornstein and Norris, 1989). With the development of imaging techniques such as CT and MRI scan - has come the recognition that small silent infarcts may occur in patients with non symptomatic stenosis of the carotid artery (Norris and Zhu, 1992).

In this case, the occurrence of symptoms in the right side of the face plus the difficulty in speech might raise the question of a possible embolus to a branch of the MCA from the thrombus at the bifurcation. A perfusion deficit would have produced problems primarily in the border zone (the area of the arm).

In this particular case, earlier evaluation of the patient might well have resulted in a demonstration of occlusive disease of the extracranial portion of the carotid artery

prior to total occlusion. For such patients surgical therapy is feasible. To restore blood flow 20 days after occlusion as in this case is unusual.

A question which remains unanswered in this case is whether this patient would have proceeded eventually to a completed lasting hemiparesis. Kase et al (1991) have summarized the various studies. The rate of completion of the stroke over a 40 month period varied from 2% (Marshall, 1964) to 51%.

The following case demonstrates a case in which the patient began with carotid TIA's progressed to a carotid border zone syndrome of infarction and then involved additionally all of the middle cerebral artery territory.

Case 26-3 (Pt. of Dr. Thomas Mullins): This 72-year old right-handed white male was admitted for evaluation of two episodes of right upper extremity weakness, each of two hours duration, beginning 2 days prior to admission. Following the first episode, the patient had persistent left-right disorientation, a deterioration in writing (dysgraphia), could not understand what he had read and had transient slurring of speech.

Neurological examination:

1. *Mental status and language function:* Intact for alertness and orientation. Language was fluent with intact repetition, and object naming; however, reading comprehension, writing, and left-right orientation were all impaired.
2. Cranial nerves: Intact.
3. Motor system, reflexes and sensory system were all entirely intact.
4. *Carotids:* A bruit was present on the left.

Clinical diagnosis: Carotid artery stenosis with TIA's reflecting decreased perfusion in the border zone followed by thrombosis and passage of emboli to the inferior division of the middle cerebral artery.

Laboratory Data:

1. CT scan and EKG were normal
2. An *arteriogram* performed on the day following admission demonstrated the following:
 - (a) The left internal carotid artery was completely occluded just above the bifurcation (Fig. 26-7A).
 - (b) The left external carotid artery did fill the left internal carotid artery at the siphon through anastomosis about the orbit (Fig. 26-7B). However, there was a cutoff just below the siphon suggesting that the thrombus (clot) at the bifurcation had extended to this level. Moreover, the left middle and anterior cerebral arteries failed to fill in this manner.
 - (c) The left posterior cerebral artery did originate from this segment of the otherwise occluded carotid siphon segment but with no retrograde filling into the basilar artery (Fig. 26-7B).
- 4) The right carotid artery filled not only the right middle cerebral and anterior cerebral artery but also was the source of the right posterior cerebral artery (Fig. 26-7C).
- 5) The right carotid system also supplied the left anterior cerebral artery and to a limited extent the left middle cerebral artery (Fig. 26-7D).

Subsequent course: On the day following admission, weakness in the right hand at wrist and finger extensors recurred. During the arteriogram, the patient was noted to have additional problems with speech. Weakness in the right upper extremity increased. Despite subsequent anticoagulation, additional progression occurred with total paralysis of the right upper extremity, aphasia and a right homonymous hemianopsia. A *repeat CT scan*, 72 hours after these events, demonstrated acute infarction with severe edema involving the entire cortical and deep territory of the middle cerebral artery and the cortical territory of the posterior cerebral artery but with relative sparing of the anterior cerebral artery territory and of the thalamic territory of the posterior cerebral artery (Fig. 26-8). Coma developed secondary to the herniation effects on the brainstem and the patient expired 8 days after admission.

Comment: This patient clearly had hemispheric carotid border zone TIA's followed by persistent symptoms that suggested involvement of the inferior division of the middle cerebral artery to the inferior parietal lobule. These latter persistent symptoms may well have been embolic from the thrombus at the level of the carotid bifurcation. There then was progression of the border zone findings

followed by involvement of the entire middle cerebral artery territory and of the cortical territory of the posterior cerebral artery. The end result was a massive cerebral infarct with considerable swelling. Such massive swelling with herniation of temporal lobe through tentorium and secondary brainstem compression is the major cause of acute death in patients dying after acute carotid artery or massive middle cerebral artery infarctions (31%). Other causes of death are pneumonia (29%), cardiac arrest (17%), pulmonary embolus (13%) (Bounds et al 1981).

Not all patients with acute carotid infarcts continue to progress. In the series of Jones and Milliken (1976), 39% of patients remained stable. Thirty-five percent had gradual improvement and 19% had a progressing deficit over 48 hours.

The following case history illustrates such an occlusion with massive infarction of the entire territory of the middle cerebral artery.

Case 26-4: This 61-year-old, right-handed black housewife one week prior to admission, suddenly fell to the floor while taking a bath and lost consciousness. She was picked up off the floor by her son who found that she was unable to move her left arm and leg. She was unable to walk and had regained no function in these extremities. Her speech had been thick, but no aphasia had been present. No headache had been noted.

Past history: Hypertension had been present for three years. Five days prior to admission, she had been switched to a new antihypertensive medication. There was no history of heart disease. Both parents had died of heart disease and hypertension.

General physical examination: Blood pressure was 150/100, pulse was regular at 84. Blood pressure was 150/100, the pulse was 84 and regular.

Neurological examination:

1. *Mental status:* The patient was obtunded and slow to respond. However, she was grossly oriented to time, place, and person.

2. *Cranial nerves:*

- a. The head and eyes were deviated to the right. The patient could not move the eyes to the left on command. However, on vestibular stimulation, the eyes could be moved to the left.
- b. The patient neglected stimuli in the left visual field. The pupils did respond to light.
- c. Papilledema was present bilaterally particularly in the right fundus where a recent hemorrhage was present.
- d. There was a decrease in pain sensation or a neglect of painful stimuli on the left side of the face.
- e. A marked left central facial weakness was present.

3. *Motor system:* A complete flaccid paralysis of the left arm and leg was present. The patient was unable to sit up without support.

4. *Reflexes:* Deep tendon reflexes were increased on the left compared to the right. The left plantar response was extensor.

5. *Sensory system:* All modalities of sensation were decreased on the left side of the body.

Clinical diagnosis: Acute occlusion of the stem of the middle cerebral artery, possibly embolic, although primary occlusions of intracranial arteries may occur in the non-Caucasian population. Hypertensive intracerebral hemorrhage was a less likely possibility.

Laboratory data:

1. *Chest and skull x-rays* were negative but the *electrocardiogram* showed left ventricular hypertrophy.
2. *Electroencephalogram* indicated focal damage throughout the right hemisphere—most prominent in the right frontal area, (focal 3 to 5 Hz slow waves). In addition there was a relative absence of electrical activity in the right temporal area (Fig. 2-23) consistent with a severe degree of destruction of this area.
3. Brain scan 3 days after admission showed a significant but diffuse uptake of isotope (Hg^{197}) in the right hemisphere. A repeat brain scan on 9 days after admission showed a more marked uptake measuring 11x6x6 cm., extending from the right frontal area to the posterior parietal area. Uptake extended from the surface to the deep midline (Fig. 26-14).
4. Cerebrospinal fluid contained no significant cells. Protein was moderately increased to 57 mg./100 ml. Pressure at the lumbar area was 150 mm. of csf.
6. Right brachial arteriogram revealed a complete occlusion of the right middle cerebral artery at its origin (Fig. 26-15).

Hospital course: The patient showed no significant improvement during a four week hospital course.

Comment: The patient had a sudden occlusion of the right middle cerebral artery with massive infarction of the entire area of the right hemisphere supplied by the middle cerebral artery. Such massive infarctions are often, as in this case, associated with a significant degree of cerebral edema with the development of papilledema. At times the degree of swelling of the cerebral hemisphere may be sufficient to displace the pineal or the anterior cerebral artery. It is also possible in this case that the infarct was secondarily hemorrhagic. In many cases of hemorrhagic infarction the spinal fluid does not contain red blood cells.

The equal involvement of arm, leg and face was consistent with the involvement of the penetrating branches of the middle cerebral artery with resultant infarction in the posterior limb of the internal capsule. The deviation of head and eyes to the right indicates destruction of area 8 of the right hemisphere or of the fibers descending from this area, through the corona radiata. Involvement of the cortex in addition to this the internal capsule is also indicated by the findings on the brain scan and electroencephalogram and by the neglect of visual and tactile stimuli on the left side. As regards the etiology, an embolus to the middle cerebral artery is the most likely etiology although in a non-Caucasian patient, primary occlusion could not be ruled out. Today this patient would probably have been treated with t-PA presuming that she had arrived at an emergency room capable of administration of this agent within 3 hours of onset of symptoms and did not have contraindications in terms of preexisting conditions or of CT scan findings (hemorrhage or massive infarction -refer to Brott & Boguslavsky, 2000).

Prognosis for survival during the acute state of the first week depends on the degree of edema patients with massive middle cerebral artery territory infarcts due to MCA occlusion who already had early CT scan evidence of brain swelling within 24 hours of the ictus. Fifty five percent of these patients expired, overwhelmingly of herniation effects. Patients older than 45 years had a poorer prognosis than younger patients. Infection of the lungs is a serious complication of large infarcts and a major cause of death during the second week. If the patient survives, prognosis for recovery is related to the size of infarct. Less than 3 cm. infarcts may be associated with a good recovery; greater than 3 cm. with severe disability (Olson, 1991). This patient had already survived for one week prior to reaching the neurologic center. Although she continued to survive, her prognosis for recovery remained poor.

The following case history illustrates many aspects of ischemia within the cortical distribution of the posterior cerebral artery. This patient demonstrates the general rule that posterior cerebral cortical infarcts are usually embolic.

Case 26-5: This 55 year old ambidextrous married white female research coordinator at approximately 11:30 AM on the day of admission suddenly developed blurring of vision possibly all over her field of vision, possibly in her left visual field, possibly in her left eye. A coworker checked her vision, and found that she had a left visual field defect. Shortly thereafter, she developed tingling paresthesias of the left face arm and leg.

Past history: Hypertension treated with hydrochlorothiazide and Lasix.

Physical examination: Blood pressure was elevated to 160/70. Weight was elevated to 264 pounds. A small ecchymosis was present under the toenail of the left second digit.

Neurological examination, (3 hours after onset):

1. Mental status: Intact.

2. *Cranial nerves:* A non-congruous left homonymous hemianopsia was presented greater in the left temporal field than the right nasal field.

3. Motor system: Intact.

4. *Reflexes:* Deep tendon stretch reflexes were decreased in the lower extremities (patella, 1+ and Achilles, 0). Plantar responses were equivocal, with the left probably extensor.

5. *Sensory system:* There was decreased pain and errors were made in graphesthesia over the left foot.

6. *Vascular:* There were no bruits over the carotids and subclavian areas and the blood pressures in the two arms were equal.

Clinical diagnosis: Posterior cerebral artery ischemia and possible infarct, probably embolic, involving the right calcarine cortex and thalamus or a lacunar event involving the right thalamus.

Laboratory data:

1. Duplex scans of the carotid and vertebral arteries and CT scan of the head on the day of the event were normal. RPR, ESR, TSH, proteins C, S, antithrombin 3 and all anticardiolipin antibodies were normal.
2. *MRI*, 4 days after onset (Fig.26-18) :small area of increased signal in the right occipital lobe in region of the visual cortex consistent with an infarct in distribution of the calcarine artery.
3. *MRA* (Fig.26-19): decreased flow in the distal right posterior cerebral artery probable embolic occlusion with filling of distal branches by anastomotic flow.
4. *Holter monitoring* demonstrated multiple brief episodes of paroxysmal atrial fibrillation.
5. The routine *transthoracic echocardiogram* demonstrated no clear cut abnormalities. However the *transesophageal echocardiogram* demonstrated a definite patent foramen ovale with right to left shunting.

Subsequent course: Reevaluation of the patient 22 hours after the onset of symptoms demonstrated clearing of all neurologic findings. When seen 2 weeks after the event her only complaint related to some problems in reading. This patient already been receiving aspirin at the time of the event and this was discontinued. She was begun on lifelong systemic anticoagulation with coumadin by the consultant cardiologist Dr. Filiberti since she had two conditions associated with embolization: paroxysmal atrial fibrillation and patent foramen ovale with right to left shunting. The patient did well over the subsequent 5 years.

Comment: When initially evaluated, the posterior cerebral artery location was clear but the pathophysiology was not. The subsequent imaging studies clearly indicated a small infarct involving the calcarine artery territory. Whether the previous sensory findings indicated some involvement of the posterior cerebral penetrating supply to the ventral posterior lateral nucleus of the thalamus remains unclear. The decreased flow in the right posterior cerebral artery was clearly demonstrated. In general as with the middle cerebral artery, cortical infarcts of the posterior cerebral artery territory, in the Caucasian population are almost always embolic. In this case the patient had two possible sources for emboli and was placed on long term anticoagulation.

The following case 26-6 presented at the onset with a transient bilateral posterior cerebral ischemia but with more severe residual symptoms reflecting unilateral posterior cerebral disease.

Case 26-6. This 75-year-old, white, right-handed widow developed sudden headache on the day prior to admission, with nausea, vomiting, and a poorly described bilateral disturbance of vision. She was found by a relative the morning of admission complaining of total blindness and of severe headache. She was noted to be confused and incoherent (believed she was in New Jersey rather than Massachusetts). She was able to walk only with assistance.

Past history: A minor degree of hypertension had been noted several days prior to admission.

Physical examination: The patient was an obese female with blood pressure elevated to 170/100. She was holding her head complaining of headache.

Neurological examination:

1. Mental status:
 - a. The patient was restless and disoriented for time and place.
 - b. There were difficulties in cooperation so that detailed testing of mental status could not be performed.
 - c. Simple calculations were poorly performed.
 - d. Digit span was markedly limited.
 - e. There was no left-right confusion and no evidence of aphasia.
2. Cranial nerves:
 - a. Initially the patient was unable to detect objects (e.g., a face or lights) in either visual field. Within six hours, a change had occurred. Although conjugate extraocular movements were full, the patient tended to keep her eye deviated to the right and failed to follow objects introduced from the periphery of the left visual field. The eyes could be deviated to the left on command.
 - b. The pupils responded to light.
3. Motor system:
 - a. Strength was grossly intact.

- b. A slight unsteadiness (ataxia) of gait was present.
- 4. Reflexes:
 - a. Deep tendon reflexes were grossly symmetrical.
 - b. A Babinski response was present on the left; a probable Babinski sign was also present on the right.
- 5. *Sensory system*: All modalities were intact.

Clinical diagnosis: Ischemia bilateral posterior cerebral arteries, cortical branches, probably embolic.

Laboratory data:

1. *Hematocrit* was normal. *Total cholesterol* was elevated to 312 mg./100 ml. The *glucose tolerance test* was consistent with diabetes mellitus.
2. Chest and skull x-rays and the electrocardiogram were normal.
3. The *electroencephalogram* demonstrated focal 3 to 4 cps slow waves in the right posterior parietal occipital area with rare slow waves in the right posterior temporal area consistent with focal damage in this area.
4. *Lumbar puncture* indicated clear spinal fluid with no cells and a normal protein of 18 mg./ml.

Hospital course: The patient had a significant improvement in headache and a clearing of confusion with a return of mental status to her normal level. Her hospital stay was prolonged by the development of thrombophlebitis of the left femoral vein. At the time of hospital discharge, one month after admission, there was still a residual left field defect (homonymous hemianopsia) with preservation of vision in the macular area (macular sparing). Follow-up evaluation approximately 14 months after discharge indicated no significant neurological findings except for the residual left field defect (homonymous hemianopsia with macular sparing) (Fig. 23-16).

Comment: The initial symptom of total blindness suggested bilateral posterior cerebral ischemia. The development of confusion and disorientation is also consistent with bilateral posterior cerebral ischemia. The nausea, vomiting, and minor ataxia of gait may well have indicated ischemia of the brain stem, suggesting that the basic occlusive process may have originated at a lower point in the basilar artery. The residual and most severe degree of involvement was certainly within the territory of the right calcarine artery.

The occurrence of severe headache is not usually considered in connection with ischemic-occlusive disease. A review of our cases of posterior cerebral occlusion indicates that the occurrence of severe headache is often a prominent symptom. Often in these cases prior to lumbar puncture, the diagnosis of subarachnoid hemorrhage was considered.

At the present time evaluation would include a CT or MRI scan. Other examples of posterior cerebral artery cortical infarcts are presented in the visual system chapter with appropriate CT scans.

The following case 26-7 provides an example of an intracerebral hematoma of unknown etiology in a young patient.

Case History 26-7. This 33-year-old white, right-handed, male linotype operator, at approximately 8:30 p.m. had the sudden onset of numbness of the left side of his mouth. At 10:30 p.m. he developed a severe right frontal headache and noted sudden onset of numbness of the left upper extremity which rapidly spread to involve the entire left side. Marked weakness of the left arm and leg developed. Evaluation that evening at his local community hospital indicated a dense left homonymous hemianopia, a marked left central facial weakness, an absence of any voluntary movement of the left arm and leg and no awareness of painful stimulation of the entire left side. A left Babinski sign was present. Lumbar puncture revealed opening pressure elevated to 235 mm. of water; and 50 fresh red blood cells per cubic mm. The patient was subsequently transferred to the neurosurgical service at New England Center Hospital.

Past history: There were no remarkable features as regards hypertension, renal disease, or diabetes mellitus. No history of drug use was obtained.

Physical examination: The patient was moderately obese with a normal blood pressure of 110/85. Examination of the heart revealed no abnormalities. No rigidity of the neck was present. There were no murmurs over the cranium.

Neurological examination:

1. **Mental status:** Orientation, speech and the ability to provide a coherent history were all intact.
 2. **Cranial nerves:**
 - a. Examination of the fundi showed no hemorrhage or papilledema.
 - b. A dense left homonymous hemianopsia was present.
 - c. Sensation was defective on the left side of the face, as well as the left side of the body.
 - d. A left central facial weakness was present.
 - e. The tongue deviated to the left.
 3. **Motor system:**
 - a. A dense flaccid paralysis of the left arm and leg was present.
 - b. There was no resistance to passive motion in the left arm and leg. and little in the left lower extremity (that is, a flaccid paralysis was present).
 - c. Cerebellar tests were negative.
 4. **Reflexes:**
 - a. Deep tendon reflexes were absent in the left upper extremity but increased in the left lower extremity
 - b. A Babinski sign was present on the left. The plantar on the right was flexor.
 - c. No grasp reflexes were present.
 5. **Sensation:**
 - a. There was no perception of pinprick or of tactile stimulus on the entire left side of the body.
 - b. Position and vibratory sensation were absent on the on the left.
- Clinical diagnosis:** Intracerebral hematoma right putamen-thalamus or embolus stem of MCA with hemorrhagic transformation.

Laboratory data:

1. Hematocrit, white blood count, and differential were all within normal limits. Sedimentation rate was normal.
2. *Tests of bleeding time, clotting time, and prothrombin time* were all within normal limits.
4. *Skull x-rays* revealed a shift of the pineal, 7 mm. from right to left.
5. *Electroencephalogram* revealed frequent focal 4 to 5 cps slow waves in the right hemisphere most prominent in the frontal and parietal areas consistent with focal damage in these areas.
6. *Arteriograms* (right common carotid) revealed a 12 mm. shift of the pericallosal branch of the anterior cerebral artery. The internal cerebral vein was also shifted 8 mm. from right to left. The middle cerebral branches emerging through the sylvian fissure were depressed. There was no evidence of an abnormal arteriovenous shunt or of an aneurysm. Cortical vessels and veins in the suprasylvian area were stretched over relatively avascular areas. The conclusion was a space-occupying mass in the right posterior frontal parietal area consistent with an intracerebral hematoma.

Subsequent course:

On the day of admission, the patient was taken to the operating room. A right parietal burr hole was made. The underlying cortex was noted by the neurosurgeon, Dr. Robert Yuan, to bulge prominently. A needle was inserted to a depth of 1 cm. into the cortex where 25 cc. of old, dark red blood under pressure was expelled. Free drainage of blood continued through a catheter which remained in place for 2 days.

Return of voluntary movement in the left lower extremity at the hip and knee was noted on the day following surgery. Reevaluation of neurological status 2 weeks after surgery, revealed continued improvement. The left homonymous hemianopsia was no longer present but the patient did have some difficulty in reading (losing the left half of the line of print). A left central facial weakness was present; voluntary hand-foot movements on the left were still not possible. Proximal muscle groups (shoulder, hip, knee) had returned to 60 per cent of normal strength. Deep tendon reflexes were now hyperactive in the upper and lower left extremities with a left Babinski sign. A dense

sensory deficit remained on the left side with no perception of pain, touch, vibration, and position in the upper and lower extremities. Reevaluation 4 weeks after surgery, revealed a return of pain and temperature sensation but continued deficits in proprioception. Reevaluation by Dr. Yuan 4 months after surgery, indicated a return of strength in the left hand with a strong grip. The gait was typical of a spastic hemiplegia. Reflexes were unchanged. Sensory examination revealed a return of primary modalities such as vibration and pain, but marked errors in cortical modalities, such as position sense, were made. Follow-up 7 months after surgery indicated an excellent return of strength on the left side but continued incoordination in the left hand due to deficits in proprioception.

Comment:

This patient from several standpoints presents a number of unusual features not seen in the typical case of intracerebral hemorrhage. The patient was relatively young (33 years old) and had no history of hypertension. He had none of those conditions such as leukemia, bleeding disorders, and the like which predispose to intracerebral hemorrhage. The arteriogram provided no evidence of an intrinsic or a secondary metastatic brain tumor. Moreover, histological examination of the tissue and drainage material obtained at the time of surgery failed to reveal tumor cells. No aneurysm was demonstrated on angiography. Although no arteriovenous malformation was demonstrated at the time of arteriography, such a malformation may have been present previously but destroyed in the process of hemorrhage. The significance of the minor prodromal sensation of numbness of the face remains uncertain. This may have reflected an initial small area of ischemia with secondary hemorrhage.

Where was the initial site of hemorrhage? In this case, the hemorrhage apparently originated in the subcortical white matter of the parietal lobe presenting as a lobar hemorrhage. The pattern of initial evolution of symptoms and the final pattern of sensory deficit is perhaps more consistent with such a parietal lobe location. From the prognostic standpoint, he did not lapse into coma and did not have compromise of brain stem functions as so often occurs when there is tentorial herniation or an extension of the hemorrhage into the ventricular system. That these various events did not occur, may in part relate to the drainage of the hematoma by the neurosurgeon with removal of this supratentorial mass lesion. The management of intracerebral hemorrhages is discussed in greater detail by Ojemann and Heros, (1983).

The following three cases provide examples of subarachnoid hemorrhage from aneurysms at the three major sites: posterior communicating-internal carotid (Case 26-8), middle cerebral bifurcation (Case 26-9) and anterior communicating –anterior cerebral junction (Case 26-10)

Posterior communicating- internal carotid junction.(Figs. 26-24)

Case 26-8: This 66-year-old white housewife, five days prior to admission, had the sudden onset of a severe bicipital bifrontal headache associated with vomiting. The headache was constantly present for 3 days but was increased by coughing. At the same time, she noted an alteration of vision in the right eye. She noted also a drooping of the right eyelid. The headache subsided, only to recur one night prior to admission as a severe occipital headache associated with vomiting. There was no past history of hypertension. The patient was admitted to her community hospital. A lumbar puncture revealed the presence of subarachnoid blood and the patient was transferred to the neurology/neurosurgical services of the New England Medical Center on 10/2/66.

General physical examination: The patient was an obese female with blood pressure of 140/80 and complaints of severe headache. Her temperature was normal.

Neurological examination:

1. *Mental status:* The patient was alert with mental status intact.
2. Cranial nerves:
 - a. Fundus: Blurred discs were present bilaterally, being greater on the right. No venous pulsations were present on the right.
 - b. Nerve III: The right pupil measured 4 mm. and was not reactive to light on direct or consensual stimulation.. The left pupil measured 2mm and was reactive to light. Ptosis of the right eyelid was present. At rest on forward gaze, there was outward deviation of the right eye. The patient was unable to adduct the right eye on left lateral gaze and failed to move this eye on upward or downward gaze. Other extraocular movements were intact.

c. Nerve VII: Minimal flattening of the right nasal labial fold was present.

3. *Motor system*: Strength, coordination, and gait were intact.
 4. *Reflexes*: Deep tendon: A minimal relative increase was present on the right. Plantar responses: The left was flexor, the right was equivocal.
 5. *Sensation*: All modalities were intact.
 6. *Neck*: Mild nuchal rigidity was present (resistant to passive flexion of head onto chest).
- Clinical diagnosis**: Subarachnoid hemorrhage due to an aneurysm at the posterior communicating–internal carotid junction.

Laboratory data:

1. Skull and chest x-rays were normal.
2. Studies of bleeding time, clotting time, and prothrombin time were all within normal limits.
3. *Arteriograms* revealed an aneurysm of the right internal carotid artery just below its junction with the posterior communicating artery. There was no left-to-right flow through the anterior communicating artery. There was narrowing of the anterior cerebral arteries near their origin bilaterally. This suggested to the radiologist the possibility of vasospasm, secondary to the presence of subarachnoid blood.

Hospital course:

Because the history suggested several episodes of bleeding, surgical therapy was selected. A right temporal craniotomy was performed by Dr. Robert Yuan with clipping of the neck of the aneurysm. The temporal lobe was retracted revealing a 13 mm.-long saccular aneurysm, arising from the internal carotid artery close to the junction with the posterior communicating artery. Distally the aneurysm enlarged into a large sac which was hidden behind the oculomotor nerve. This nerve was bulging at the point where the aneurysm, which was clipped, was well formed. The more distal sac of the aneurysm was thin and showed signs of previous rupture with yellow staining of the adjacent meninges. The sac of the aneurysm was covered with Gelfoam. Postoperatively, significant deficits as compared to the preoperative neurological status were evident. The level of consciousness waxed and waned with periods of alertness alternating with periods of apathy and drowsiness. Twenty days after surgery, she was described as sitting with both eyes closed, continuously grasping and palpating the arm of the chair with the right hand, less frequently with the left. There was a marked bilateral release of an instinctive grasp reflex. There was increased resistance in both upper extremities, at times described as plastic rigidity, at times as the “Gegenhalten,” associated with bilateral frontal lobe disease. No spontaneous voluntary movements of the left leg occurred. Bilateral Babinski signs were present. A bilateral resting tremor of the hands and of the head was also present. At times inappropriate jocularity was present. All of these findings suggested a bilateral front lobe syndrome with infarction in the territory of the anterior cerebral arteries and additional involvement of the basal ganglia. The complete paralysis of the right third nerve remained at preoperative level. At the time of hospital discharge, one month after surgery, the frontal lobe findings and the weakness in the left leg remained prominent.

Comment:

The presence of severe headache in association with a mild degree of nuchal rigidity suggests meningeal irritation. Such irritation could indicate a subarachnoid hemorrhage or a meningitis (inflammation of the meninges due to bacterial or viral infection). The sudden onset of the headache is more consistent with a subarachnoid hemorrhage. The lack of fever and of accompanying or prodromal systemic findings is also against the diagnosis of meningitis. Finally, the clearly focal third nerve findings are more in favor of the diagnosis of subarachnoid hemorrhage (although focal or multifocal neurological findings may develop as complications of a bacterial meningitis).

In this case, the significant findings on neurological examination related to the right third cranial nerve. The third cranial nerve is particularly subject to compression by aneurysms of the posterior communicating artery because having emerged from the midbrain it pursues an anterior course towards the cavernous sinus in a close parallel relationship to the posterior communicating artery. In general, compressive lesions of the third nerve produce initially an alteration in pupillary constrictor functions, then involvement of the levator palpebrae and finally involvement of the superior, medial and inferior

rectus, and inferior oblique muscles. The initial alteration in vision in the right eye and ptosis of the right eyelid at the onset of headache are then consistent with a compressive lesion. The patient at the onset of symptoms did not report a diplopia.

The third nerve as it emerges from the midbrain also passes in close relationship to the posterior cerebral and superior cerebellar arteries, but aneurysms of these vessels are much less common than those which occur in relation to the posterior communicating artery and internal carotid artery.

These findings with extrinsic compressive disease of the third nerve are to be contrasted with the pattern of intrinsic brain stem involvement of the third nerve nucleus where medial rectus or superior rectus function is more likely to be initially compromised.

The patient had minimal findings suggesting involvement of the left corticospinal and corticobulbar tracts: minimal right central facial weakness, minimal increase in deep tendon reflexes on the right side, and an equivocal right plantar response. The findings may have been produced by a slight shift of the brain stem to the left due to the small mass of aneurysm on the right side of brain stem. With such a shift, compression of the left cerebral peduncle against the tentorium might occur. In any case, these findings were minimal. The significant findings in this case clearly related to the third cranial nerve and it is these findings which allowed localization of the lesion prior to arteriography.

As regards the postoperative course, it is evident that this patient had severe involvement of the frontal lobes presumably as a result of bilateral infarction within the territory of the anterior cerebral arteries. In retrospect, the narrowing of the anterior cerebral arteries at their origin, presumed secondary to "spasm" noted at the time of arteriography, may have provided a clue as to the development of the complication. The neurosurgeon, faced with the decision as to the best time to intervene, would prefer as the ideal situation, the moment when arterial spasm has not yet developed or is no longer present but bleeding has not yet recurred. In reality the risk of recurrent hemorrhage is so great that the aneurysm should be clipped as soon as possible for example the day of presentation. Vasospasm can now be treated with calcium channel blockers and after clipping by increasing the blood pressure to increase perfusion. The typical angiographic appearance of aneurysms in this location is demonstrated in Figure 26-24. Occasionally large aneurysms can be demonstrated on the CT scan.

Middle cerebral bifurcation (Fig 26-25).

Case 26-9: This 46-year-old, right-handed, white, married male, was admitted to the neurology/neurosurgical services of the New England Medical Center on 6/10/66. He presented a history that 10 days prior to admission, he had the sudden onset of a severe, throbbing, supraorbital and vertex headache. The headache began while the patient was in bed in the early stages of sexual intercourse. The patient noted no weakness except that his tongue "felt funny" in articulation for approximately one minute. There was a transient difficulty in speech during this period.

Past history: Mild hypertension had been present.

General physical examination: Blood pressure was 160/100.

Neurological examination:

1. *Mental status* was intact.
2. *Cranial nerves* were intact.
3. *Motor system* was intact.
4. *Reflexes* were physiologic
5. *Sensory system* was intact.
6. Headache could be precipitated by *head movement*.
7. With *cervical flexion*, pain occurred in the neck and lumbar area occurred.

Laboratory data:

1. Skull and chest x-rays were normal.
2. *Electroencephalogram* revealed focal damage in the lateral aspect of the left hemisphere (focal 3 to 5 cps slow waves).
3. *Lumbar puncture* on the day following admission revealed opening pressure elevated to 270 mm. of water and closing pressure to 210 mm. of csf. The fluid was xanthochromic (yellow discoloration). In addition 38 fresh red blood cells per cubic mm. were present. Protein was elevated to 80 mg./100 ml. Hinton was negative.

4. *Arteriography* revealed a bilobed aneurysm at the trifurcation of the left middle cerebral artery measuring 8 x 4 mm. Spasm and narrowing of the proximal anterior and middle cerebral arteries were noted.

Hospital course:

On the day following admission, the patient complained of a few-minute episodes of numbness in the right face, tongue, and right upper extremity with thickness of speech. Examination now revealed right central facial weakness and slight slurring of speech. The patient also now complained of additional neck pain on extreme forward flexion. On June 12, 1966, the patient had another short episode beginning with numbness over the right thumb, spreading to the right hand and then to the angle of the mouth.

Because of the several episodes which occurred, following hospital admission, involving the right face, tongue, and hand in association with the finding of fresh red blood cells in the spinal fluid, it was considered likely that bleeding from the aneurysm was continuing to occur. Surgical therapy was therefore considered necessary to prevent additional (and possibly fatal) subarachnoid hemorrhage. On May 20, 1966 a left frontotemporal craniotomy was performed by Dr. Robert Yuan with subsequent plastic coating of the entire aneurysm to reinforce its wall. There was evidence of recent hemorrhage in the subarachnoid space with yellow discoloration of the meninges. In order to expose the aneurysm, it was necessary to remove the anterior tip of the temporal lobe back to a distance of 2.5 cm. There was a small amount (5 to 10 cc.) of intracerebral blood clot in the superior temporal region close to the aneurysm. The aneurysm itself had no actual neck that could be clipped. Several middle cerebral branches appeared to arise from the dome or lateral wall of the aneurysm.

In the postoperative period, the patient initially did well. A minor expressive aphasia was present, but the patient was alert and well oriented. However, fever and jaundice developed. With the development of significant alterations of liver functions approximately 7 days after surgery, the patient became confused and agitated. The prothrombin time fell to 3 per cent of normal and there was evidence of bleeding into the gastrointestinal tract at this time. The prothrombin deficit was corrected by administration of vitamin K. It was unclear, however, as to whether any minor intracranial bleeding occurred during this time. Some improvement in liver functions occurred, and the patient became more alert but continued to manifest inappropriate behavior, emotional lability, and disturbance of memory. He left the hospital against medical advice one month after surgery, on July 20, 1966.

The patient was readmitted to the hospital approximately one month later on August 13, 1966. For two days, the patient had been less active, appeared confused, glassy eyed, and failed to communicate. The degree of obtundation cleared when adequate dosage of the anticonvulsant medication, Dilantin, was administered. This fact taken on conjunction with the electroencephalogram, which demonstrated frequent focal spikes (excessive neuronal discharge) in the left temporal area (Fig. 29-1C) led to the conclusion that the episode which precipitated his readmission might well have represented a prolonged seizure discharge. The electroencephalogram also demonstrated an increase in slow wave activity in the left hemisphere, particularly the left temporal area indicating a possible increase in damage in the left temporal area. This appeared to be correlated with apparent progression of the patient's aphasia which was now receptive as well as expressive in nature. At the time of discharge, a severe expressive aphasia was still present.

Comment:

The sudden onset of severe headache during exercise or exertion (sexual intercourse in this case) is characteristic of subarachnoid hemorrhage. The location of the aneurysm was suggested by the symptoms relevant to the tongue and speech during the initial episode. The episode on June 11, 1966, involving numbness of the right face, tongue, and right upper extremity, could only indicate disease within the territory of the left middle cerebral artery. The lumbar puncture at this time indicated not only evidence of the initial leakage of blood 10 days prior to admission (an elevation of cerebrospinal fluid protein and a xanthochromia), but also fresh red blood cells suggesting that additional leakage of blood had occurred.

The nature of the episodes which occurred on June 11 and 12 is not certain. Most likely these were ischemic in nature related to decrease in blood flow as a result of clot formation within the aneurysm or from spasm of the adjacent portion of the middle cerebral artery. At times, however, symptoms such as rapidly spreading numbness occurring in episodes may suggest focal epileptic discharge. The development of an area of excessive discharge would not be unusual since this aneurysm involves those

middle cerebral artery branches which are supplying the cerebral cortex. In addition hemorrhage within the Sylvian fissure is likely to damage the surrounding cerebral cortex. Blood and iron are epileptogenic.

The patient's course following surgery was complicated by the development of severe liver dysfunction. The etiology of this problem was never clear, the various studies suggesting either a toxic hepatitis related to various drugs and anesthetic agents or a variety of obstructive jaundice. What the patient's eventual recovery would have been had this problem not developed is uncertain. It is clear, however, that during this post-

operative period the patient did develop significant impairment of language functions, possibly related to infarction or oozing of blood in areas supplied by the middle cerebral artery. It is also evident that a seizure focus had developed in this area. Such seizure foci may have developed in relation to the preoperative hematoma noted in the temporal lobe, in relation to the surgical manipulation of the area, or in relation to the postoperative complications.

Today (2002), the history presented by this patient would have prompted an immediate CT scan and a lumbar puncture if the CT scan were negative. An arteriogram would have been performed immediately after these studies. Surgery would have been performed immediately after the evaluation of the angiographic studies to prevent the recurrent episodes of bleeding.

Anterior communicating -anterior cerebral junction(Figs. 24-26, 24-27, 24-28)

Case History 26-10. . (Patient of Dr. John Sullivan). This 49-year-old, right-handed truck driver was transferred from his local community hospital for evaluation of subarachnoid hemorrhage.

The patient had experienced occasional frontal headaches for the previous 5 years. In June, 1965, while changing a tire, he had a severe throbbing frontal headache which cleared after thirty minutes. Since that time he had experienced daily throbbing frontal headaches, usually present on arising in the morning. On September 4, 1965, the patient had the onset of a particularly severe headache which began while he was engaged in heavy work on a boat. There was associated stiffness of the neck, nausea, vomiting, and a general sensation of weakness.

Evaluation at his local community hospital revealed papilledema (blurred optic disk margins on funduscopic examination). Nuchal rigidity was present. The lumbar puncture demonstrated grossly bloody cerebrospinal fluid. He was subsequently transferred to the neurology/neurosurgical services of the New England Medical Center on 9/7/65.

Past history:

1. Hypertension had been noted in June, 1965.
2. The patient's father had died at age 59 of a cerebrovascular accident.

General physical examination:

1. Blood pressure was moderately elevated to 180/100. Pulse was 60.
2. No bruits (murmurs) were present over the skull.
3. A significant degree of nuchal rigidity was present. The neck could not be actively or passively flexed.

Neurological examination:

1. Mental status:
 - a. The patient was somnolent but could be aroused, although attention span was noted to be shortened.
 - b. He was oriented for place and situation but confused as to time.
 - c. Digit span was shortened to 5 forward and 4 in reverse.
 - d. The patient was unable to do calculations.
2. Cranial nerves:
 - a. Sense of smell was decreased on the right side.
 - b. Disk margins were indistinct on examination of the fundus. Arterioles were tortuous and irregular.
3. Motor system:
 - a. Strength and tone were intact.
 - b. Cerebellar tests were normal.
4. Reflexes:
 - a. Deep tendon reflexes were symmetrical.

- b. Plantar responses were flexor.
- 5. Sensory system: All modalities were intact.

Laboratory data:

1. Bleeding, clotting, and prothrombin times were all normal. Platelets were normal on smear.
2. Chest and skull x-rays were normal.
3. *Arteriograms* demonstrated an aneurysm of the anterior communicating artery which extended posteriorly and to the right. The aneurysm filled from the left carotid circulation.

Hospital course: During the evening of September 11, 1965, the patient became lethargic and would not speak or obey commands. Blood pressure rose to 240 mm. systolic. The patient became totally unresponsive with pupils fixed and dilated and with incontinence of urine. Deep tendon reflexes were exaggerated with plantar responses extensor. Within minutes, the patient became responsive again; pupils were reactive, although the right remained sluggish. The patient made purposive movements and obeyed commands. Lumbar puncture subsequently indicated grossly bloody spinal fluid. The patient remained confused and less alert with a tendency to fall asleep.

On September 17, 1965, the patient again suddenly complained of violent headache and lost consciousness for approximately 30 minutes. The right pupil became dilated, and the right eye deviated to the right suggesting a right medial rectus weakness. The blood pressure again rose to 240/140. As previously, the patient regained consciousness. Although confused, he had no clearly lateralizing signs. Subsequent lumbar puncture again revealed the presence of fresh red blood cells.

Because repeated episodes of bleeding had occurred, surgical therapy was undertaken. On September 21, 1965 a left frontal craniotomy was performed by Dr. Robert Yuan. The left frontal pole was resected exposing the left anterior cerebral artery and the aneurysm which arose from the anterior communicating artery. The medial surface of the right frontal lobe was cystic and contained 20 cc. of hematoma. The hematoma was evacuated. The aneurysm was reinforced by spraying with a plastic coating.

Neurological examination approximately 1 week after surgery indicated that the patient was confused and disoriented, with a "rather negative response" refusing to follow directions and to speak to examiners. Blood pressure was noted to be extremely labile with a drop of 50 mm. of mercury systolic when the patient moved from prone to sitting position. Equivocal Babinski signs were present, and the patient was incontinent of urine and feces.

Reevaluation on November 17, 1965, approximately two months after surgery, indicated that although the patient was ambulatory and able to take care of his daily needs, he remained confused for time and place. When the patient was examined 6 months after surgery, confusion was no longer present; intellectual functions were consistent with his education.

Approximately 2 years after surgery, the patient, who had recently been married, reported that he was impotent, unable to obtain an erection.

Comment:

In this case, the history of sudden onset of severe headache and stiffness of the neck, precipitated by exertion, clearly suggested a subarachnoid hemorrhage originating from the rupture of an intracranial aneurysm. It is likely that several episodes of subarachnoid bleeding occurred in June and September of 1965. While the clinical findings of somnolence and confusion with a decrease in olfaction on the right may have suggested the possibility of an anterior communicating-artery location, these were certainly not firm diagnostic clues. The episodes characterized by sudden alteration in blood pressure, while nonspecific, might have raised the question of orbital-frontal, anterior cingulate, or hypothalamic effects (areas within the distribution of the anterior-cerebral arteries).

The negativity of the patient following surgery undoubtedly indicated preoperative and operative damage to the orbital and prefrontal areas. The bilateral Babinski signs and the incontinence of urine and feces in the postoperative period probably reflected damage to the parasagittal motor and premotor areas within the distribution of the anterior cerebral arteries. The impotence may have reflected damage at the frontal or hypothalamic level.

Today, an initial episode such as occurred in June 1965 would have prompted a CT scan and a lumbar puncture if that study had been negative. Of course many exertional headaches are not a result of

subarachnoid hemorrhage. Nevertheless the more serious entity must be ruled out at the emergency room level, since the mortality and morbidity of the frequent recurrent hemorrhage are so high. Again the use of early arteriography and early surgery are to be emphasized.

Case 26-11 illustrates many of the neurologic aspects of bacterial endocarditis.

Case 26-11: This 34-year old right hand married white male hair dresser was admitted with a one month history of night sweats, fever to 102-103° F., generalized aches and pains. Within the previous 3-4 months, the patient had undergone repeated dental procedures for dental infection. He had been reported to have a mild heart murmur 2-3 years prior to admission. His urine had recently become dark. The day prior to admission he had noted a small hemorrhagic lesion on the dorsum of his left hand.

Physical exam:

1) Skin: A small indurated red lesion dorsum left hand and a small red lesion under the nail bed 3rd left toe.

2) Heart: A grade IV/VI high-pitched holosystolic murmur was present at the apex; and a high-pitched II/VI murmur at the base; both not previously noted to this degree.

3) Temperature was elevated to 101° F

Neurological examination: Entirely within normal limits.

Clinical diagnosis: Bacterial endocarditis with systemic emboli but without neurological symptoms at this point.

Laboratory data:

1) **CBC:** Anemia with hematocrit 31 and hemoglobin of 10.1.
White blood count was 9900 with differential of 78% poly-morphonuclears and 9 atypical lymphocytes.

2) Sedimentation rate was elevated to 38 mm.

3) **Urinalysis** indicated 8-10 red blood cells per high power field.

4) All three **blood cultures** drawn on the day of admission produced growth of streptococcus viridans (alpha hemolytic).

5) **Echocardiogram** indicated a prolapsed mitral valve with probable mitral insufficiency. In addition, irregular densities on the mitral leaflets suggested vegetations.

Hospital course: All of these findings were consistent with a diagnosis of subacute bacterial endocarditis with evidence of microemboli to extremities (skin lesions) and to kidneys (hematuria). The patient was begun on high dosage intravenous penicillin (24 million units per day) with an excellent response as regards fever and general symptoms. Thirteen days after admission he again developed a temperature elevation. The following day, at 2 p.m., he abruptly developed difficulty with speech and a right hemiplegia. Over the next 2 hours this rapidly evolved to the following neurological state.

Neurological examination:

1) Mental Status and Language Function

a) The patient was drowsy - holding the left side of his head as though in pain.

b) He was mute.

c) He was unable to carry out any spoken or written commands.

2) Cranial Nerves

a) The patient neglected the right visual field and had no response to threat in the field.

b) The fundoscopic exam indicated blurring of the disc margins on the left.

c) Right central facial weakness was present.

d) Pain sensation was decreased on the right side of the face.

3) **Motor System:** A flaccid right hemiparesis was present although some purposive withdrawal of the right arm and leg occurred on painful stimulation.

4) Reflexes

a) Deep tendon reflexes were increased bilaterally but right were greater than left with clonus of the right ankle.

- b) The right plantar response was extensor, the left flexor.
 - 5) *Sensation*: A right-sided hypalgesia was present. Other modalities could not be tested.
 - 6) Neck and Skin
 - a) No nuchal rigidity was present.
 - b) New splinter hemorrhages were present under the nails of the upper extremities.
- Neurological diagnosis:** Cerebral embolus left middle cerebral artery, with possible mycotic aneurysm and possible hematoma left middle cerebral artery secondary to bacterial endocarditis.

Laboratory data:

An immediate CT Scan (Fig. 26-30) demonstrated a large intracerebral hematoma involving the left basal ganglia and insula with massive shift of the left hemisphere to the right.

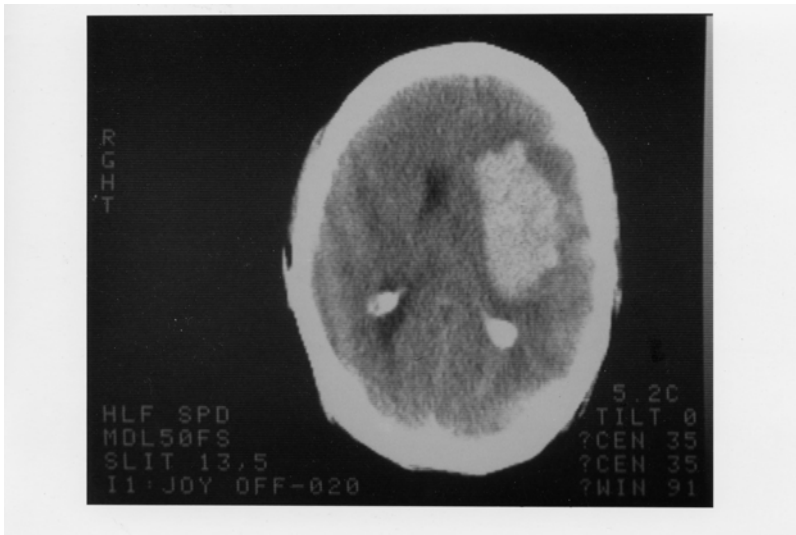
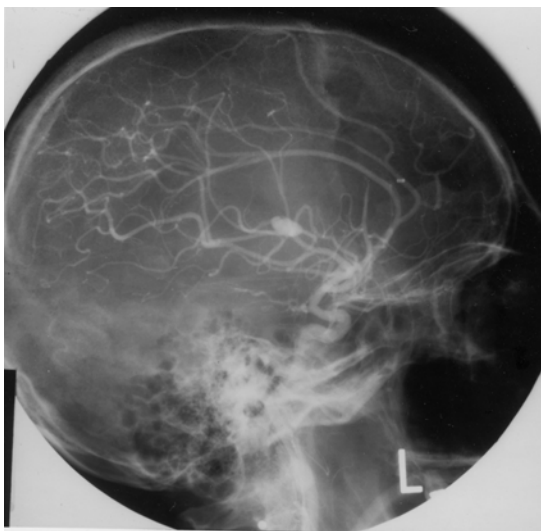


Figure 26-30.

2. An immediate arteriogram: (Fig. 26-31A) demonstrated a small aneurysm (arrow) arising from a small branch of the left middle cerebral artery (MCA) within the Sylvian fissure. A large avascular area surrounded this aneurysm with upward and lateral displacement of anterior cerebral arteries, medial displacement of lenticular striate, branches of the MCA and lateral and downward placement of the cortical MCA branches.



Subsequent course: That evening Dr. Robert Johnson removed a large intracerebral clot. Over the next 2 weeks the patient began to have some improvement in his right hemiparesis and aphasia. However two weeks after surgery, he developed right-sided focal status epilepticus. The patient had been receiving Phenytoin (Dilantin) but the level was low. Intravenous Phenytoin, intravenous Dexamethasone and Mannitol were administered. The CT scan now demonstrated a larger hemorrhage surrounded by edema. The patient was taken to surgery and additional old clot and a small amount of recent clots were removed. The patient failed to respond. He developed fixed dilated pupils and bilateral Babinski signs. The arteriogram (Fig.26-31 B,C) was repeated and now demonstrated a much larger aneurysm (measuring 11 mm vs 4-5 mm in previous films). There was also evidence of additional shifts of the anterior cerebral artery and internal cerebral vein. Anterior-frontal branches of the middle cerebral artery were occluded. Regression occurred and 8 days later patient met brain death criteria with absence of all brainstem reflexes, no spontaneous respirations and an absence of all cerebral electrical activity (silent EEG).

Comment: This patient presents a panorama of almost all of the cerebral complications of bacterial endocarditis including:

- a) Multiple septic emboli to brain, kidney, and small peripheral arteries;
- b) Mycotic aneurysm;
- c) Intracerebral hematoma
- d) Eventual mortality.

The mycotic aneurysm with eventual rupture was not a feature noted on presentation but instead was a late complication. (A silent unruptured aneurysm may well have been present on admission.) This subacute delayed presentation is more common in streptococcal endocarditis as opposed to the more virulent staphylococcal infections where acute intracranial presentations are the rule.

In this case, the aneurysm when initially discovered was small and associated with an intracerebral hemorrhage.

The aneurysm continued to enlarge after evacuation of the initial hematoma and eventually additional hemorrhage occurred. Not all patients with mycotic aneurysm will have intracranial hemorrhage. In the series of Brust et al (1990), 41% were associated with rupture. Of 20 aneurysms followed with angiography or CT scan, ten became smaller or disappeared, 10 remained unchanged or enlarged despite an adequate treatment course with antibiotics. In the present case, initial rupture occurred almost 2 weeks after admission and beginning of antibiotic treatment.

The recommended approach in patients with endocarditis to avoid the fatal complications of mycotic aneurysm rupture is to perform 4 vessel angiography in those patients with endocarditis who develop neurological symptoms. If a mycotic aneurysm is found, prompt surgical treatment (clipping) should be performed. Unfortunately many patients with mycotic aneurysms have no neurological symptoms prior to rupture. To perform angiography in all patients with bacterial endocarditis, would not be practical and would fail to detect aneurysms that developed after the studies. However, when long-term anticoagulation is planned in patients on the completion of antibiotic treatment to prevent additional emboli, angiography should be performed or repeated. The entire role of anticoagulation in bacterial endocarditis remains unclear. (See Salgade et.al 1987 and Hart et.al 1987, 1990). MRI may have an increasing role in non-invasive diagnosis, since MRI angiography should be able to detect aneurysms greater than 2-3 mm in diameter

Figure 26-32. Arteriovenous malformation in the right parietal area demonstrating the abnormal tangle of vessels and infarction of the surrounding cerebral cortex and white matter.

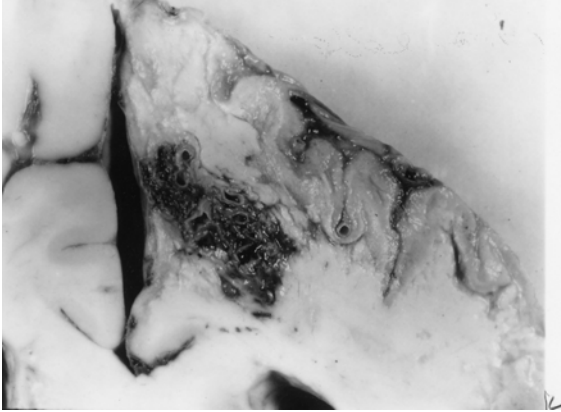


Figure 26-32. In this case, the malformation was fed mainly by the right anterior cerebral artery and drained into the superior sagittal sinus. This 46-year-old woman had, as a primary problem, subarachnoid hemorrhage from an anterior-communicating saccular aneurysm, with other unruptured aneurysms at left posterior communicating, and right superior cerebellar. (Courtesy of Dr. John Hills).

Case history 26-12 provides an example of a long-term unruptured arteriovenous malformation presenting as a seizure disorder.

Case 26-12: This 51-year old right-handed female experienced two nocturnal generalized convulsive seizures 6 years prior to evaluation . Evaluation by Dr. Robert Bazemore at that time revealed a significant 30-year history of minor episodes: “little sensations”. The patient described sudden strange feelings as though moving in slow motion. With other episodes she would feel at a distance from her surroundings with a sense of detachment at times with a strange odd smell. After 2-3 minutes the “spell” would alter, she would feel depressed with a sense of terrible fear. The patient also had a long history of migraine headaches (bilateral throbbing) which were often preceded by visual auras more prominent in the right visual field. The neurological examination was normal. She was treated with anticonvulsant (Phenytoin). When seen by the author for other unrelated neurological problems 6 years later , the interval history indicated no additional generalized seizures but complex partial seizures had continued.

Neurological examination: entirely within normal limits.

Clinical diagnosis : Simple and complex partial seizures of temporal lobe origin .

Laboratory data:

1. The *CT scan without enhancement* now demonstrated a calcified lesion in the anterior-medial right temporal lobe which enhanced with contrast (Fig. 26-32A). Large early draining veins were also noted (Fig. 26-32B).

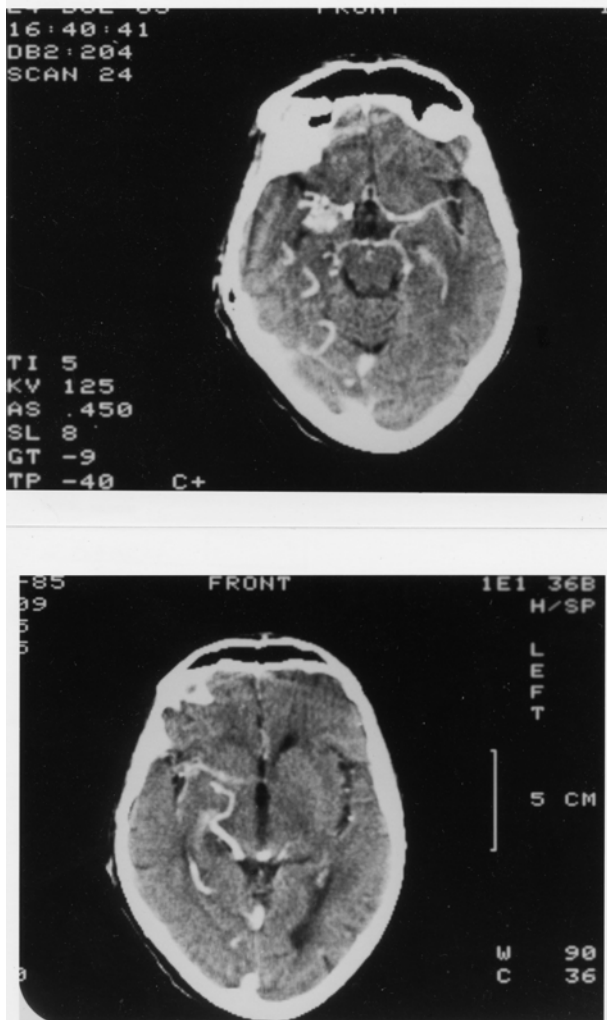


Figure 26-33. Arteriovenous malformation. Right anterior temporal:
Case History 24-12 CT Scan. This 51-year-old right-handed female
was evaluated in 1983. She had generalized seizures in 1977 and 36-
year history of complex partial seizures. She would feel "weird
sensations" and detached with a "strange odd smell", then a sense of
terrible fear. She also had a history of migraine headaches preceded
by visual auras, and a normal neurological examination. was not
remarkable. The CT Scan without contrast demonstrated a calcified
lesion in the right anterior temporal lobe (not shown).
A). With contrast a large enhancing lesion was present in the deep
Sylvian fissure area - involving anterior medial temporal areas, uncus
and adjacent insula.
B) At a higher level of section a large draining vein was visualized (see
also fig 26-35 and text for details).

Subsequent angiographic studies confirmed the anterior venous malformation with supply from right internal carotid, middle cerebral and anterior choroidal arteries (26-33A) and the presence of shunting into a large early draining vein (26-33B).

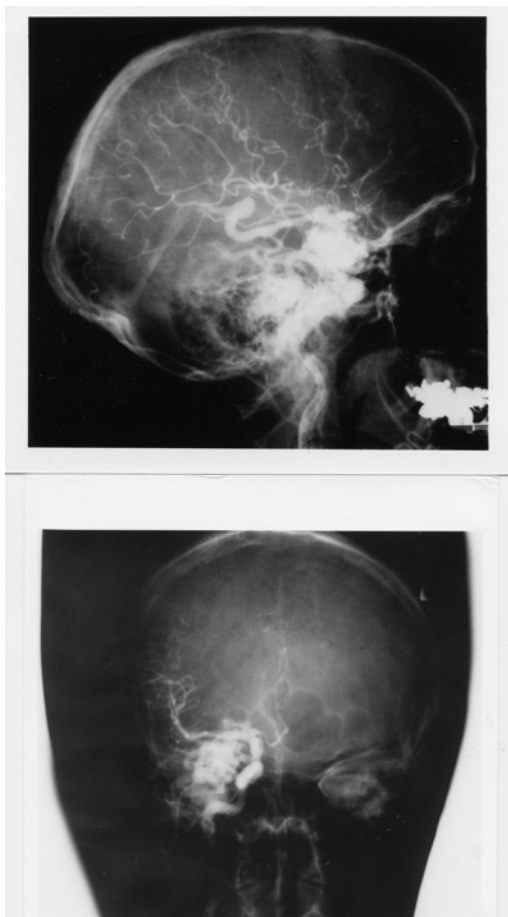


Figure 26-34. Arteriovenous malformation: Right anterior temporal lobe. Right carotid arteriograms. Case History 24-12

- A) Malformation - supplied by right internal carotid, middle cerebral, and anterior choroidal branches.
- B) There is early shunting of arterial blood into a large draining vein. See Text and Fig. 26-34 for details.

Comment: This patient presented with classical complex partial seizures originating in the right temporal lobe. No definite evidence of either subarachnoid or intracerebral hemorrhage was present over 35 years. With the use of CT and MRI scan, more of these lesions are being identified in an unruptured state in patients investigated for seizures and headaches.

Considerable controversy remains as to the appropriate therapy for the unruptured cerebral arteriovenous malformation (compare Aminoff, 1987 and Heros and Yong-Kwang, 1987). Long-term follow-ups - 12-20 years - does suggest a 25-39% risk of hemorrhage with a mortality from that hemorrhage of 10-14%. The risk of recurrent hemorrhage the first year is 6% with the subsequent annual risk for hemorrhage for both ruptured and unruptured 3% per year (see also Crawford et al, 1986, Brown et al 1988, Rigamont, et al 1988).

Surgical therapy involved excision after ligation or embolization of feeding vessels (Stein and Wolpert, 1986, Stein and Mohr, 1988, and Mohr, et al 1986).

CHAPTER 27: NON VASCULAR SYNDROMES : TRAUMA, TUMORS, INFECTIONS, TOXIC METABOLIC AND SYSTEMIC DISORDERS

I TRAUMA

Case 27-1 presents an example of an epidural hematoma seen in 1963 prior to modern neuroimaging.

Case 27-1: This twenty-two-year-old, white airman, during a winter storm, was involved in an auto accident at 11:30 p.m., in which he struck his head against the windshield. He also sustained minor abrasions of the shoulder, hands and chest. The patient apparently was dazed, perhaps unconscious, for a matter of seconds to minutes. He was taken by ambulance to the emergency room of the nearby army hospital where a brief evaluation indicated that the patient was alert, without definite neurological findings, and apparently without significant injuries. Skull X-rays did indicate a linear fracture over the right temporal area which did not, however, definitely cross the major groove of the middle meningeal artery. The patient was, therefore, admitted to the intensive care ward for head injury observation.

The patient was apparently alert upon his arrival on the ward. It should be noted, that the major attention of the physicians in the emergency room and of the nurses on the intensive care ward was given to four other patients from the same accident who sustained very severe and obvious injuries. However, by 5 a.m., the patient was reported by the nurses to be agitated and confused.

Neurological examination: (8 a.m.)

1. *Mental Status:* The patient was agitated and unable to cooperate. He was sitting up in bed, holding his head, moaning and hyperventilating to a marked degree. He answered only occasional questions and then with a yes or no.

2. *Cranial Nerves:* intact except

Fundi: The examination was negative but incomplete.

Pupils: There was a bilateral but sluggish response to light. A minimal asymmetry was present. The right pupil was perhaps slightly larger and slightly more sluggish than the left.

3. *Motor System:* All limbs were moved spontaneously. There was a variable increased resistance to passive motion, but this was apparently due to the patient's inability to cooperate.

4. *Reflexes:* Deep tendon reflexes were increased bilaterally. Plantar responses were bilaterally equivocal.

5. *Sensation:* Pain sensation appeared to be intact.

6. *Neck:* There was variable resistance to attempted flexion.

7. *Head:* The patient moaned when palpated over left or right temporal areas.

Neurological diagnosis : Possible evolving acute bilateral epidural or subdural hematoma

Subsequent course: The patient was to be evaluated by the civilian neurosurgical consultant, whose arrival was delayed by several other emergencies and a snowstorm. In the meantime, progression occurred.

Neurological examination (4 p.m.): The patient was now deeply comatose with little response to stimulation. The pupils were now bilaterally fixed and dilated. The four limbs were extended in a decerebrate posture with significant spasticity on passive motion. The degree of spasticity in the upper limbs could be modified by tonic neck maneuvers. The plantar responses were bilaterally extensor. Spontaneous respirations were now irregular and infrequent, and the patient required the assistance of a mechanical respirator.

Neurological diagnosis: Acute tentorial herniation with brain stem compression secondary to epidural hematoma.

Subsequent course: A general surgeon immediately performed definitive therapy. Bilateral burr holes were placed. An epidural hematoma over the right temporal-parietal area was evacuated and the

bleeding middle meningeal artery branch was coagulated and ligated with a significant rapid improvement in the patient's status. Follow-up examination approximately two months later indicated that the patient had returned to active duty but was experiencing some problems related to changes in recent memory and to changes in motivation and personality. No significant motor or sensory findings were present. Minor and inconsistent asymmetry of deep tendon reflexes was present.

Comment: This patient followed the usual pattern of a short lucid period followed by the rapid progression of confusion, agitation, coma and brain stem deterioration of function. As indicated by Plum and Posner (1980), the development of hyperventilation is often indicative of a midbrain-upper pontine stage of damage from an expanding supratentorial lesion. The early appearance of hyperventilation followed by bilaterally fixed dilated pupils and a decerebrate state may well indicate that the supratentorial lesion was producing a more central downward compression of the midbrain and less of a lateral uncal-type compression. In any case, it is evident that brain stem compromise was progressing rapidly. So rapidly, in fact, that therapy had to be undertaken immediately. In such a case, there was no longer time for the transfer of the patient to a specialized treatment center and no longer any time for specialized laboratory studies. Today, such a patient would have undergone CT scan studies at the time of emergency room evaluation or at the first sign of change in mental status. Similar cases of recovery of function from brain stem compression in patients with acute subdural or epidural hematomas have been reported by Brendler and Selverstone (1970).

The following case provides an example of chronic bilateral subdural hematomas

Case 27-2. (Patient of Dr. Alex Danylevich). This 83-year-old white female was transferred from her local hospital because of increasing confusion. Two months prior to admission, she had been involved in a motor vehicle accident sustaining fractures of her ribs and left clavicle. She also struck her head and had a scalp hematoma in the right frontal area. She was admitted to her local hospital at that time for several days. She was described as having post-traumatic anterograde and retrograde amnesia and obtundation which cleared over her hospital stay. She returned to her usual activities. Two months after the trauma she re-entered her local hospital with a three day history of increasing confusion and lethargy. When she became mute she was transferred to St. Vincent Hospital. Serum sodium at her local hospital had been low at 124 mEq/liter and CSF protein was reported at 62 mg%. EEG was reported as diffusely slow.

Neurological examination:

1. *Mental status:* She was relatively lethargic but could be aroused to an alert state. The patient was mute and did not follow commands even when relatively alert.
2. *Cranial nerves:* Pupils were 2 mm. and reactive. Sudden paroxysmal nystagmoid deviations of the eyes to the right occurred during the exam.
3. *Motor system:* Strength was intact. Tone was increased in the right leg.
4. *Reflexes:* Deep tendon stretch reflexes were symmetrical. Plantar responses were extensor bilaterally.
5. *Sensory system:* Pain responses were intact.

Clinical diagnosis: Chronic subdural hematomas, probably bilateral .

Laboratory data:

1. The CT scan (Fig. 27-3) demonstrated significant bilateral chronic subdural collections much denser on the left where the lateral ventricle was obscured and shifted to the right. The right lateral ventricle and sylvian fissure were enlarged. There was a question of additional recent rebleeding into the subdural collection on the left.
2. Serum sodium was low at 117 mEq/liter. Serum osmolality was 236. Urine sodium was 53 mEq/liter.

Hospital course: Serum sodium was corrected. Then, bilateral subdural hematomas were removed via burr holes on the right and a bone flap on the left where substantial chronic membrane and fluid were found. Neurological examination eight hours after conclusion of the procedure, indicated an alert patient who had no apparent language disorder and no weakness. Follow-up CT scan ,6 days after surgery revealed re-expansion of the cerebral hemispheres. Considerable cortical atrophy was

now evident. This was presumably long-standing predating the subdural hematomas. She was transferred back to her local hospital, 10 days after surgery. At that point she was alert; ambulating with assistance and was able to feed herself. She did develop transient right face and hand focal motor seizures which were treated with anti-convulsants.

Comment: If the history of trauma two months previously had not been present with a prior hospital admission related to the trauma, the confused obtunded mute state in this patient might easily have been attributed to a metabolic encephalopathy (low serum sodium) or to the cortical atrophy of a senile dementia of Alzheimer's type. Many patients with primary cerebral disease will develop a low serum sodium due to inappropriate secretion of anti-diuretic hormone with retention of water and dilution of serum sodium. The mute state in this patient in retrospect probably reflected the severe involvement of the dominant left cerebral hemisphere. The sudden eye movements to the right probably represented focal seizure activity originating in the left frontal eye fields, not far from the cortical area providing the focus for the post operative seizures.

In some patients without a definite history of trauma, the predominant findings may be those of a progressive bilateral frontal lobe involvement with confusion, bilateral grasp reflexes, and a frontal lobe apraxia of gait. In such patients, the nature of the pathological process involving the frontal lobes may be uncertain. The differential diagnostic list may include metastatic disease, frontal parasagittal meningioma or frontal glioma.

There are patients who are at increased risk for subdural hematomas: patients receiving anticoagulant medications, or patients with bleeding disorders, e.g., as in leukemia. The problem is more common in the elderly, in chronic alcoholics, and in patients with Parkinson's disease perhaps because such population groups are more prone to unsteadiness and falls. In the patient with cortical atrophy as in Alzheimer's disease, the bridging veins may be stretched and thus more prone to tear. In addition, the patient is unable to recall minor trauma and is already confused. In addition, because of the atrophy, a large amount of blood may accumulate in the subdural space without producing early symptoms of headache and other symptoms.

The problem also exists in the infant during the first year of life. The picture presented, however, differs significantly from that seen in the adult because in the infant, separation of the sutures may occur, allowing the intracranial cavity to expand. The onset is then often nonspecific and nonfocal: an enlargement of the head, a failure to thrive, a failure to gain weight, a failure to reach developmental landmarks. At times, generalized seizures, vomiting, and papilledema may be noted. The etiology often relates to presumed birth trauma.

A related problem may also be seen in infants following meningitis. This is the problem of subdural effusions usually occurring in relation to Haemophilus influenzae meningitis. The diagnosis of both subdural hematoma and subdural effusions may be made in the infant by CT or MRI scan replacing the earlier technique of subdural taps. The cerebrospinal fluid in these cases is often found to be abnormal with the presence of blood or xanthochromia and an elevated protein content.

II TUMORS

The following case history provides an example of the course of a low grade glial tumor.

Case 27-3: This 41 year old right handed white widow was admitted to the hospital because of increasing frequency of seizures. At age 30, eleven years prior to admission, the patient experienced her first generalized convulsive seizures. The neurological examination and the electroencephalogram were normal. Four years prior to admission, the patient had a change in the character of her seizures, she began to experience focal seizures involving the right arm and leg. These would begin with the sensation of a "chill" or stiffening of the right leg and a "numbness" (a tingling) which would then spread to the lower back. At the same time, weakness would occur in the right leg followed by repetitive clonic movements of the right arm. During this time, the patient would be unable to talk distinctly but would be aware of her surroundings. Although the episode continued for several minutes, there was no apparent loss of consciousness. Examination by Dr. John Hills at that time revealed a slowness of response but no definite neurological deficits. The EEG was again normal. Neurological evaluation three years later (one year prior to admission) was again unremarkable although focal seizures were still occurring every 2-4 weeks. Evaluation 2 months prior to admission, now indicated a more increase in deep tendon stretch reflexes in the

right lower extremity and an equivocal plantar response on the right side .Hospital admission finally occurred because the weakness experienced in the right leg during the seizure was becoming more severe.

Neurological examination

1. *Mental status*: The patient was anxious and tremulous with moderate psychomotor retardation and poor attention span. Digit span was limited to 5 digits forward and 4 in reverse .However orientation, memory ,delayed recall , calculations and language function were all intact.
2. *Cranial nerves*: All were intact with no papilledema.
3. *Motor system*: Strength, gait and cerebellar signs were all normal.
4. *Reflexes*: Deep tendon reflexes were slightly increased on the right side. The plantar response on the right was equivocally extensor.
5. *Sensory system*: Intact except for a minimal bilateral decrease in sensation at the toes.

Clinical diagnosis: Left parasagittal tumor most likely a meningioma, low grade glial tumor such as oligodendroglioma or low grade astrocytoma considered possible but very unlikely.

Laboratory data:

1. Chest and skull x rays ,radioactive brain scan(Hg 197) and left carotid arteriogram were all normal.
2. *EEG* was now mildly abnormal because of occasional focal sharp waves ,left parietal parasagittal area.
- 3.*Pneumoencephalogram* demonstrated a slight downward depression left lateral ventricle suggesting a possible left parasagittal mass. The CSF obtained was normal.

Subsequent course: Since the brain scan and arteriogram were normal, a meningioma was considered unlikely and a low grade glioma was considered the most likely diagnosis. The lack of calcification on the skull x rays was considered a point against the diagnosis of an oligodendroglioma and more in favor of a low grade astrocytoma. Since the patient was relatively free of neurological deficit and the dominant hemisphere was involved, neurosurgical intervention was deferred .Her anticonvulsant medications were readjusted. Frequent office evaluations indicated that significant progression was occurring with increasing weakness of the right leg, and an inability to form letters in handwriting. .Four months after hospital discharge ,the patient now had a right central facial weakness ,a mild right hemiparesis, and increased deep tendon stretch reflexes on the right and a right Babinski sign. Speech was dysarthric with a minor degree of misnaming or inability to name objects. A left carotid arteriogram now indicated a deep left posterior frontal mass lesion. There was also a suggestion of abnormal vascularity in the region of the pericallosal and callosal marginal branches of the anterior cerebral artery. Surgical exploration of the left frontal area indicated slight discoloration of and widening of gyri. Probe counting located an area of increased uptake of isotope (P32) at 16X normal in the mid and posterior frontal area. A partial frontal lobectomy was performed from the level of the sphenoid wing laterally and forward but sparing the speech areas. However tumor was still present at the posterior margin of the resection . Histologic examination of the tumor removed indicated a grade I- II astrocytoma. Following surgery ,the right sided weakness progressively improved, speech was unchanged. Following hospital discharge the patient ,received a 3 month course of supervoltage radiation (7,500 roentgens)directed to the left frontal parietal area. When last evaluated 18 months after surgery, there was a moderate disorientation for time , a nominal aphasia a slowness in following commands ,a perseveration of speech and performance, a right central facial weakness and a clumsiness in following commands.

Comment: The onset of seizures at age 30 ,always raises the question of a possible brain tumor. The initial seizures however were generalized convulsive seizures and the neurological examination and the EEG were normal, thus decreasing the risk of a tumor. When focal seizures appeared at age 36,the risk of a tumor was significantly increased but still ,the exam and the EEG remained normal .In retrospect ,the slowness of response might have suggested some frontal lobe involvement. By age 41, it was evident that a focal process was slowly evolving with some involvement of parasagittal motor cortex. Again the psychomotor retardation and the deficit in digit span at a time that delayed recall was normal (possibly consistent with an impairment of working memory) might have suggested some degree of. prefrontal involvement. Certainly, by the time of surgical intervention, 11 years after onset of symptoms, the pace of progression had accelerated. This might have indicated some alteration in the basic biological activity of the tumor.

Finally a note about diagnostic techniques . This patient was initially seen in 1956 and hospitalized in late 1967. At the time CT scan and MRI were not yet available. Today, an adult with onset of seizures at age 30 would have undergone an MRI or at least a CT scan with contrast. The diagnosis would have been made much earlier in time but the eventual treatment and results of treatment would probably not differ significantly from those obtained in 1967. The role of radiotherapy in low grade gliomas remains controversial. There is a role once transformation to a higher grade of malignancy has occurred.

MALIGNANT GLIOMAS

The following case demonstrates the apparent acute (possibly stroke like) onset and rapid progression of a very malignant glioblastoma multiforme.

Case 27-4 (patient of Dr. Tom Mullins): This 68 year old right handed white male was admitted to St Vincent Hospital with an apparent 4 to 5 day history of difficulty in doing calculations and in speaking, “he could think of the word ,but had difficulty getting it out”.

Neurological examination :

1. *Mental status and language function*: Speech was limited to short phrases with loss of connectors and sentence structure. Writing was impaired but, repetition, comprehension, naming and reading were intact.
2. *Cranial nerves*: Intact.
3. *Motor system*: Strength and gait were intact .However fine motor movements of the right hand were impaired .
4. *Reflexes*: Tone was increased on the right. The right patellar reflex was increased. Bilateral Babinski signs were present.
5. *Sensory system*: Intact.

Clinical diagnosis: Diagnosis was uncertain .The abrupt onset suggested a possible vascular event such as an embolus in the middle cerebral artery territory but the overall pattern including bilateral Babinski signs without significant hemiparesis was unusual. Thus other possibilities had to be considered including focal herpes simplex encephalitis, tumor or a small lobar hemorrhage.

Laboratory data :

1. EEG : Focal left hemisphere delta and theta slow wave activity was present.
2. CT scan(Fig.27-7):A. The non enhanced study demonstrated a low density mass in the mass in the left frontal-parietal parasagittal region with areas of hemorrhage. B. The contrast enhanced study demonstrated an irregular rim of enhancement.
3. Angiogram indicated an avascular mass in the left frontal-parietal area.

Subsequent course: Dr. Alex Danylevich performed a subtotal resection of this tumor which was found to contain blood clot and cystic fluid. The histology of the tumor was glioblastoma multiforme (Fig.27-5). The patient subsequently received 4000cGy whole brain radiation and an additional 2000cGy to the tumor site. Three months following surgery ,the patient developed increasing obtundation. CT scan revealed a large left frontal necrotic mass. Fever, hypocalcemia and hypernatremia developed and he expired one month later.

Comment: This patient presented with what appeared to be an abrupt onset of language problems raising the question of a cerebrovascular accident. In retrospect , it was evident on the CT scan and at surgery that the acute onset reflected the hemorrhage and necrosis which had occurred within the tumor. This was a rapidly growing ,extremely malignant tumor which apparently had outstripped its blood supply despite the neovascularity.

III INFECTIONS

FOCAL

Subdural empyema

The following case provides an example of subdural empyema complicating frontal sinusitis.

Case 27-5. This forty-eight year old, right-handed, white male was referred for evaluation because of headaches and papilledema. For 3 weeks prior to admission, the patient had severe bifrontal headaches which were constantly present and interfered with sleep. One week prior to admission, the patient developed a fever of 105° with a white blood count (WBC) of 25,000. X-rays indicated "sinusitis". The patient was hospitalized at his local community hospital. Confusion soon developed. Three days prior to transfer to a neurologic unit, the patient had a series of seizures characterized by turning of the head and eyes to the left. Lumbar puncture had indicated clear cerebrospinal fluid with pressure of 300 mm. and protein increased to 65 mg./100 ml. The patient had chronic right nasal discharge for ten years. Eight weeks prior to admission, the patient, while stooping down, struck his right frontal areas but was not - unconscious. A right periorbital ecchymoses developed, and the patient also had the onset of bilateral frontal headaches.

General physical examination: Temperature was elevated to 101°. There was right periorbital edema. Excoriation of right nasal mucosa was present.

Neurological examination:

1. *Mental status:* The patient was alert but irritable and slightly confused. He was poorly attentive and failed to persist in carrying out motor activities. He was oriented grossly for time, place and person. Calculations were poorly performed. Delayed recall was defective.
2. *Cranial Nerves:* All were intact with the exception of the fundi. Low-grade papilledema was present and venous pulsations were absent.
3. *Motor System:* Strength was intact, but there was a slight drift downward of the outstretched left arm.
4. *Reflexes:* Deep tendon reflexes were somewhat brisker at left arm and leg (3+) as compared to the right (2+). Plantar responses were flexor. A bilateral grasp reflex was present.
5. *Sensory system:* Intact
6. *Skull & Neck:* There were slight tenderness over the right periorbital area. Minimal nuchal rigidity (resistance to passive flexion of the neck) was present.

Clinical diagnosis: Right frontal subdural empyema or brain abscess.

Laboratory data:

1. The *WBC* was increased to 14,350 cells per cubic mm., and the sedimentation rate was increased to 110 mm. in one hour.
2. *Sinus X-rays:* Bilateral maxillary and frontal sinusitis was present with resorption of bone.
3. *Electroencephalogram:* Focal 4 to 7 cps slows wave activity was present in the right parietal area suggesting focal damage. Moreover, focal voltage suppression (reduction of voltage) was present in the right anterior frontal area suggesting a possible subdural collection.
4. *Right carotid arteriogram* showed an apparent slight shift of the anterior cerebral vessels to the left suggesting a right hemisphere space-occupying lesion.

Hospital Course: Following these studies a right frontal trephine (burr) hole was placed by Dr. Robert Yuan. When the dura was incised, 5 cc. of yellow purulent material escaped from the subdural space and additional purulent drainage was aspirated. Additional burr holes were placed in the right occipital area where a few drops of subdural pus were encountered. No pus was obtained from the left subdural area. Subsequent cultures demonstrated *Staphylococcus aureus* as the responsible organism. The dura and cortex otherwise appeared unremarkable although cerebral edema was present. The patient was subsequently treated with appropriate antibiotics. His temperature gradually subsided to normal and his mental

status cleared. Three weeks later, a bilateral frontal sinusotomy was performed by Dr. Thomas Klein with drainage of the sinus. Histological examination of a section of sinus mucosa removed demonstrated intense chronic inflammation. The patient continued to improve. When seen in followup examination four months after admission, papilledema had subsided, no neurological findings were present except for a slight reflex asymmetry (slightly increased on the left).

Comment: This patient presented a definite history of chronic nasal sinus infection with a recent exacerbation. The role of trauma in the exacerbation is uncertain. It is clear, however, that the sinusitis had produced involvement of the adjacent bone with subsequent spread to the adjacent frontal subdural space. The severe headache experienced by the patient reflected not only the process of infection involving the sinus and meninges but presumably also the increase in intracranial pressure. The early involvement of the right frontal area was suggested by the initial symptoms of confusion and by the occurrence of focal seizures characterized by turning of the head and eyes to the left. The findings of the electroencephalogram suggested a subdural collection of fluid or pus in the right frontal area.

These clinical and laboratory impressions were confirmed by the subsequent surgical observations. In the present case the arteriogram suggested only a non-specific space-occupying lesion in the right frontal area. The more specific finding in these cases would involve the displacement of distal branches of the anterior and middle cerebral artery from the inner table of the skull as in a subdural hematoma. Today the CT scan or the MRI/MRA is the study of choice for confirming the diagnosis of a subdural collection. Additional review of subdural empyemas will be found in Miller et al 1987. In the pre-antibiotic era, infections involving the nasal sinuses could produce thrombophlebitis of the cortical veins and superior sagittal sinus. With that complication, infarction of that area of motor cortex representing the leg could occur resulting in unilateral or bilateral leg weakness as well as focal motor seizures. Infection of the nose or face or of the ethmoid or sphenoid sinuses could produce thrombophlebitis of the cavernous sinus resulting in the syndrome discussed in the cranial nerve chapter: unilateral or bilateral involvement of the cranial nerves found in the lateral wall of the cavernous sinus (III, IV, VI and the ophthalmic division of V). The ophthalmic vein may be obstructed producing edema of the eyelid and face. Obstruction of the retinal vein produces papilledema. Infection of the middle ear or mastoid may produce involvement of the transverse or lateral sinus. If this extends to the jugular vein, increased intracranial pressure may also occur. However increased intracranial pressure may follow any involvement of the other venous sinuses. At the present time, dural venous sinus thrombosis is usually more indicative of dehydration and other systemic conditions in the infant and in the adult of immunological disorders or of conditions that produce a state of hypercoagulation such as polycythemia, carcinoma, pregnancy or birth control drugs. (refer to Daif et al, 1995 and DeVeber et al, 2001)

CHAPTER 30 MEMORY

A case of Wernicke-Korsakoff syndrome is presented in case 30-1.

Case 30-1. Patient of Doctor John Sullivan and Doctor John Hills): This 62-year-old, white, right-handed stonecutter had been a known heavy alcoholic spree drinker for many years. The patient would drink large quantities of wine for 6 to 8 weeks at a time. Two years previously, the patient had been admitted to the Boston City Hospital because of delirium tremens (tremor and visual hallucinations). Two months prior to admission shortly following the death of a brother-in-law, the patient began his most recent drinking spree. He unaccountably found himself in Florida, not knowing where he was and

why he was there. Apparently, he had drifted aimlessly for 5 weeks with no definite food intake for a month. The patient was brought back by his family and hospitalized at his local community hospital with diplopia, ataxia and marked impairment of memory. The patient had complaints of numbness of his fingertips and unsteadiness of gait. The patient after beginning treatment was shortly thereafter referred to the Neurology Service at the New England Medical Center.

General physical examination: No abnormalities were present except for an enlarged liver with the edge palpated approximately 2-1/2 finger breadths below the costal margin.

Neurological examination:

1. Mental status:

- a. The patient was markedly disoriented for time and place. At times, the patient thought that he was in New Jersey; at other times, he stated correctly that he was in Boston.
- b. The patient, with suggestion, would recall his apparent travels that day to various other locations within and outside Boston (he was actually in the hospital). Confabulation was also evident when it was suggested that he had recently seen various fictitious persons.
- c. Remote memory; The patient was unable to state his age. The patient was able to provide his birth date correctly. He could not give his address or telephone number. When quizzed as to the President of the United States, he selected on multiple choices the previous president. At times, the patient often indicated to visitors that his mother and father were still alive, though both parents had been dead for over 20 years.
- d. Insight; He appeared to have little insight for his disorientation in time. He had no insight as to his condition or for the reason for his hospitalization.
- e. The patient's digit span was normal at 7 forward and 6 in reverse.
- f. The patient could name various objects correctly when these were presented to him and yet he was unable to retain any memory of which objects had been presented to him five minutes previously. He was unable to retain any information concerning a story that he had been requested to learn.
- g. The patient was able to do 2 and 3 figure additions and multiplications without difficulty. He was able to do the initial subtractions in the serial 7 test but then lost track of the number to be subtracted.
- h. The patient was able to read and to write without difficulty. He showed no constructional apraxia and no left-right confusion.

2. *Cranial nerves:* There was horizontal diplopia on right lateral gaze. The minor degree of separation of images, however, did not allow precise identification of the muscle involved. A minor weakness of the right lateral rectus was suspected.⁶ Horizontal nystagmus was present on lateral gaze, bilaterally and vertical nystagmus on vertical gaze.

3. *Motor system:* Strength was intact except for a minor degree of weakness in the distal portions of the lower extremities evident on ankle dorsiflexion and toe dorsiflexion.

The patient walked on a narrow base with eyes open and showed no evidence of an ataxia of gait. On a narrow base with eyes closed, the patient had a positive Romberg test.

No cerebellar findings were present.

4. *Reflexes:* Deep tendon reflexes were normal at triceps and biceps, decreased at radial periosteal. And absent at patellar and Achilles even with reinforcement.

⁶ The minor nature of the diplopia undoubtedly reflected the improved nutritional status that had occurred during the previous 5 days of hospitalization at his community hospital. We presume that if the patient had been examined prior to hospitalization, more marked lateral rectus palsy probably would have been delineated.

Plantar responses were flexor bilaterally.

No grasp reflex was present.

5. Sensory System: Pain and touch were decreased in the lower extremities below the mid calf. Vibratory sensation was absent at the toes and decreased over the tibia to a marked degree and to a lesser degree over the knees. There was to a lesser extent, a decrease in the upper extremities at the fingertips and wrists.

Position sense was decreased at fingers and toes.

Clinical diagnosis: Wernicke' encephalopathy plus nutritional poly neuropathy

Laboratory data: Complete blood count, liver functions and renal functions, CSF, EEG, and X-rays of the skull and chest were all normal.

Subsequent course: The patient was treated with thiamine, 50 MGS daily. There was a significant improvement in extraocular functions. The patient had no diplopia after the day of admission. There was no significant change in his mental condition or peripheral neuropathy. Evaluation 3 months later, indicated persistent disorientation for time and place and severe selective deficits in memory (delayed recall was still grossly defective).

Comment: This patient presents a relatively typical history of the Wernicke-Korsakoff syndrome. He had been a heavy alcoholic spree drinker. The major symptomatology that was apparent to the patient's family and to his physician, related to his marked confusion, severe impairment of memory and confabulation. The patient himself had no significant complaints and little insight into his disease. In some cases, the severe memory disturbances may be present without any definite evidence of confabulation. Not only the retentive memory for new material was impaired but also the patient's distant memory was also significantly impaired. In such cases with severe impairment of memory the prognosis for a complete recovery of mental status is very poor. The diplopia and nystagmus, as expected, resolved significantly with treatment with thiamine. The ataxia of gait, which had been present early in the case, had apparently resolved by the time of transfer from his local hospital. A significant peripheral neuropathy, mainly distal sensory, was present related to multiple B vitamin nutritional deficiency.

In many cases, the state of confusion in Wernicke's encephalopathy is preceded by or accompanied by a period of delirium tremens indicating alcohol withdrawal. The use of intravenous glucose feedings without supplemental intravenous thiamine during such a withdrawal state may actually increase the requirements for thiamine, thus exacerbating the thiamine deficiency state. For this reason, all patients under treatment for alcohol withdrawal (or admitted to the hospital with a recent past history of alcoholism) should be treated with high dosage vitamin therapy as well, on the presumption that they are candidates for nutritional deficiency.

A case of transient global amnesia is presented in case 30-2 below.

Case 30-2: This 55-year-old, right-handed, white male, college professor, awoke at 3:00 a.m. on the morning of admission in an uneasy and restless state. He asked his wife what day it was but then did not recall what she had told him. He did not know the month, kept repeating himself and asking the same questions. His wife arranged for him to be seen early in the morning by his family physician who lived a short distance away. The patient, who was familiar with the route, was unable to find his way there. When he arrived at the doctor's office, he was unable to explain why he had come. The patient apparently had forgotten about the incidents, which had occurred earlier that morning. He had no recollection that he had a grandchild born three weeks before. He could remember no significant events from this 3-week period prior to the onset of his illness. The patient's more remote recall and other intellectual capacities remained intact. The patient drove into Boston later that day but became lost despite the usually familiar route.

The patient had a past history of gout with an elevated serum uric acid level.

Neurological examination: Findings were essentially limited to the mental status examination.

When examined in the early afternoon, the patient was beginning to regain some of his ability to retain new information. The patient was generally oriented to person and place. However, he was disoriented for the day and month but was oriented for the year. The patient's store of information was quite intact suggesting a highly intelligent person.

The patient had marked difficulty with delayed recall. He could recall none of the 4 objects after 5 minutes. He could not remember any of the three test phrases given to him when asked about these 5

minutes later. He did recall in a vague manner that a memory test had been given him. As regards recent memory, the patient was unable to remember his visit to his family physician earlier in the day. Digit retention, however, was relatively well preserved; 6 forward and 5 backward. The patient had no defects in calculation. There was no evidence of a constructional apraxia. Language function was entirely intact.

Clinical diagnosis: Probable transient global amnesia

Laboratory data:

1. Complete blood count, serology, blood urea nitrogen, total cholesterol, uric acid skull and chest X-rays, EEG and complete CSF were all within normal limits.
2. The *brain scan* demonstrated a small area of increased uptake of radioisotope (Hg197) in the left temporal region.

Subsequent course: Over the several hours following admission, the patient gradually regained his ability to retain new information and to recall the events of the preceding 3 weeks, the more remote events being recalled first. The memory for the events of the day prior to admission was regained last. This pattern is referred to as a shrinking retrograde amnesia. The specific events that occurred on the morning of admission were never recalled. The following morning delayed recall was four-out-of-four objects after 8 minutes. The patient's mental status and neurological examination were otherwise within normal limits. A repeat brain scan, 3 months after the episode demonstrated considerable improvement, and all brain scan findings had resolved at 5 months. No additional episodes occurred during the one-year after the acute episode.

Comment: The patient's main deficit was in learning new information (anterograde amnesia) with the old stored long-term memory information still intact. During the episode there was a retrograde amnesia that initially extended back for three weeks. As recovery occurred, this retrograde amnesia disappeared. These relatively recent past memories were intact but transiently not accessible. The labile stage of long-term memory has been estimated to be a matter of 20-180 minutes. This case suggests that there is not a sharp border between the labile more recent stage and the remote stage of long-term memory or perhaps of the ability to access those memories. The patient could not remember what happened during the episode. That is suggestive of mesial temporal lobe involvement, in this case left hippocampal region in dominant hemisphere. The ability to perform calculations and language functions was otherwise intact. This would suggest that lateral temporal areas were not involved. The electroencephalogram was normal and consistent with such a lack of involvement of the lateral aspects of the cerebral hemispheres. Occasionally, the EEG will demonstrate a minor focal involvement of the temporal lobe. More often, as in this case, the study is normal. CT scan and MRI when performed are usually unremarkable. SPECT scan might well indicate transient focal involvement as indicated above. The brain scan in this case did suggest a transient abnormality, which would be consistent with an area of ischemia/ infarction, which resolved over the succeeding months. Such an episode must be distinguished from episodes of amnesia, which may occur in relation to, and following a temporal lobe seizure.

The effects produced by electrical stimulation of the hippocampus may also occur as relatively selective ictal and postictal phenomena in a complex partial seizure originating in mesial temporal lobe structures as illustrated in case history 30-3 which follows. Focal temporal lobe seizure phenomena were followed by a period of impaired recent memory with an inability to record new memories.

Case 30-3: This 68-year-old, white male one year prior to valuation fell, striking his occiput and transiently losing consciousness. Except for a persistent defect in his sense of smell, the patient had no apparent neurological defects following this injury. Approximately six months later, the patient had the first of a series of recurrent episodes of amnesia. These episodes occurred most often on awakening. On some, but not all, occasions the episodes were preceded by a sensation of gastric upset, a strange odor and a sensation of familiarity (*déjà vu*). The episodes of total amnesia would last 30 to 60

minutes. There would then be an impairment of memory for approximately one to two days. The patient was said during the episode of total amnesia and during the subsequent episode, to behave in an otherwise normal and rational manner. For example, he would be able to converse with his wife and others. During the episodes, he was said to be unable to remember tasks, which his wife had asked him to do during that day. A significant impairment of retentive memory would be apparent to his wife and to others. His memory for more distant and remote events was also impaired to a variable but lesser degree. The patient would then regain memory progressively over the course of the next one to two days. Apparently, memory was not regained in any orderly pattern from recent to remote or vice versa. The patient at no time had any abnormal movements suggestive of a generalized convulsion.

No automatisms had been noted and to others the patient would appear fully conscious during the episodes.

Neurological examination:

1. *Mental Status*: The patient was oriented for time, place, and person. Delayed recall was intact. The patient could remember 4-out-of-5 objects in 5 minutes. Remote memory was intact. Digit span was slightly impaired at 6 numbers forward and 4 in reverse.

2. *Cranial Nerves*: All areas were intact with the exception of cranial nerve I where olfaction was decreased for the odor of coffee grounds, bilaterally.

3. *Motor system, reflexes and sensory system*: *Intact*.

Clinical diagnosis: 1) Complex partial seizures (most likely post traumatic) with episodes of amnesia as an ictal and or post ictal phenomena. 2) Post traumatic anosmia.

Laboratory data: 1. *Skull X-rays, routine EEG, radioactive brain scan, fasting blood sugar and glucose tolerance tests, pneumoencephalogram and spinal fluid examination were normal..*

2. The EEG obtained after a period of sleep deprivation revealed occasional multifocal spikes during sleep in the right anterior temporal area and to a lesser degree the left frontal-anterior temporal area.

Subsequent course: The patient was treated with anticonvulsant medication. The episodes continued to occur once per month but were now of shorter duration, lasting only 15 to 20 minutes. The impairment of memory was less marked and involved only the ability to learn new material without prolonged periods of retrograde amnesia. After 8 months no additional episodes occurred. When seen three years after initial evaluation his neurological examination was unremarkable except for the defect in olfaction suggesting that more serious progressive disorder was not present.

Comment: In this case the episodes experienced by the patient could have posed a diagnostic problem if the occasional warning symptoms of olfactory aura, déjà vu and epigastric sensation had not been present. Most of the episodes experienced by the patient were not preceded by these clear symptoms of temporal lobe seizure, but were instead simply episodes of amnesia. Though the actual temporal lobe seizures apparently lasted only a matter of 30 to 60 minutes, some degree of impairment of memory was present for one to two days following the episode.

The etiology of the seizures in this case must relate to the patient's preceding head trauma. The loss of olfactory sensation following the trauma suggested that this trauma was of sufficient nature to tear the nerve filaments passing through the cribriform plate to the olfactory bulb on the orbital surface of the frontal lobe. Such trauma does produce contusions of the orbital frontal cortex and epileptogenic foci may result. We may also assume that this trauma may have been sufficient to produce some minor contusion of the anterior poles, inferior and medial surfaces of the temporal lobes against the bony walls of the middle fossa with a resultant scar and epileptogenic focus. The fact that olfactory hallucinations and the experience of déjà vu preceded some of the amnesic episodes

would make the temporal origin more likely. The routine electroencephalogram is not reliable in the detection of seizure discharges in either the mesial temporal or the orbital frontal areas. The electroencephalogram showed significant areas of discharge in the temporal lobe only under conditions of sleep deprivation which acts to precipitate seizure discharges in individuals who have an underlying predisposition for seizure discharges. For additional discussion, see Gallassie, et al (1988), Hughlings-Jackson (1889), Tassinari, et al (1991).

The following case history presents an example of presenile dementia.

Case 30-4: This 64 year old right handed white male formerly an administrative assistant for the veteran's administration and newspaper distributor was initially evaluated for impairment of recent memory. Initially, the wife indicated this had been progressive over 4 years, but she was subsequently able to date this back to age 54 years, 10 years previously. A review of his record indicated that another neurologist of our department had seen him 4 years previously with similar memory complaints. The neurological examination at that time demonstrated no focal features, but his mental status examination indicated an inability to recall any of four objects. There were minor changes in time orientation: his date was off by one month and the day of the week was incorrectly stated. In the interim, the memory problems had progressed. In addition there were now personality changes. He no longer participated in those activities which had previously been of great interest. He was also having some problems in finding words. There were no problems in the activities of daily living and he was not getting lost in his familiar environments.

Family history: There was no history of neurological disease in his siblings or father. His mother had died at the relatively young age of 48 of cancer.

Neurological examination:

1. *Mental status:* The mini mental status exam indicated a total score of 19 out of 30. He had particular problems in time orientation. He was able to do the immediate recitation of three objects and of a test phrase but could remember none of these on a delayed recall test. He also had difficulty copying a test figure. The patient was often tangential in his answers and demonstrated inappropriate joking.

2. *Cranial nerves:* intact

3. *Motor system* was intact as regards strength, gait and cerebellar functions. However premotor /frontal lobe functions were abnormal. He had a release of the instinctive grasp reflex. He had difficulties performing the Luria three stage motor sequences demonstrated by the examiner (slap thigh with palmar surface, then with ulnar edge of hand and then with ulnar surface of closed fist.).

4. *Reflexes:* deep tendon stretch reflexes, and plantar responses were physiologic.

5. *Sensory system:* intact

Clinical diagnosis: Alzheimer's disease

Laboratory data:

1. All screening studies such as *complete blood count, sedimentation rate, B -12, folate, thyroid functions and serological test for syphilis* were normal.

2. *CT scan* demonstrated significant dilatation of the temporal horns. (This change in the size of the temporal horns suggested hippocampal atrophy.) In addition there was a general increase in lateral ventricular size. There was also blunting of the angles of the frontal horns.

3. *SPECT scan* was within normal limits except for a slight decrease in perfusion in the left parietal region.

Subsequent course: The patient was begun on treatment with 5mg per day of donepezil (Aricept) a centrally acting acetylcholinesterase inhibitor and high dosage of vitamin E (a possible antioxidant). . When re-evaluated at one month, his family reported improvement in memory; the mini mental status exam score was now 21 out of 30. At 10 weeks into treatment, the score had increased to 25 out of 30. There was particular improvement in the delayed recall section of the exam. There was however no change in personality. He still showed inappropriate jocularity when he could not answer a question and at times was tangential in his answers. Administration of the acetylcholinesterase inhibitor temporarily improved memory function for approximately 18 months. However by age 67, behavioral disturbance (agitation, aggression nocturnal wandering and sexual disinhibition) and urinary incontinence were becoming major problems. He could no longer be managed in his home and day care setting despite the

use of haloperidol. This resulted in his placement in a nursing home. At age 69, he was now described as relatively nonfluent, and very confused. He recognized his own name and occasionally recognized relatives but showed no other response to questions. He was usually restricted to a wheel chair, could walk with assistance. He was “stiff and afraid” when requested to walk.

Comment: This patient presents a typical example of the slowly progressive course of Alzheimer’s disease. Memory problems had begun insidiously at approximately age 54. Initially these problems in the older adult may be attributed to a benign age related process in which there is minor difficulty in accessing information such as names although the ability to incorporate new information is still intact (“wait a minute, the name or word will come to me eventually”). When evaluated by a neurologist at age 60, the major finding was a severe deficit in delayed recall suggesting a process at the level of the hippocampus. The patient failed to return for follow up at that time and when he did reappear at age 64, he was now beginning to show changes in personality and frontal release signs suggesting involvement of the prefrontal and premotor areas. The use of a cholinesterase inhibitor produced some improvement in memory for about 18 months but had little effect on the changes in personality and behavior. The use of this agent has been estimated to postpone nursing home placement by approximately 15 months. Eventually by age 69, fifteen years after disease onset, gait and other motor functions were seriously affected.

The rationale for the use of cholinesterase inhibitors is based on the demonstration by Drachman and Leavitt (1974) that administration of scopolamine, an anticholinergic drug that crosses the blood brain barrier, would produce a transient syndrome similar in many respects to memory and cognitive changes of Alzheimer’s disease. Subsequent studies demonstrated a marked loss of neurons in the basal forebrain nucleus of Meynert, a major source of cholinergic fibers to the cerebral cortex. (Whitehouse et al 1981 Rogers et al, 1985 editorial of Growden 1992). However, a simplistic cholinergic hypothesis is insufficient to explain all of the features of Alzheimer’s disease. Administration of acetylcholine esterase inhibitors in mild cases (mini mental status score of 10-25) has only a limited value as in the present case. Other neuronal systems are involved (noradrenergic synapses are also involved. hippocampal system is severely involved).

The following case 30-5 provides an example of general paresis producing severe changes in cognitive function and personality.

Case 30-5 : This 59-year-old right-handed white male, cleaning establishment owner, five years prior to evaluation, manifested a personality change - increased rigidity and irritability. He would become enraged over trivial matters many times per day. During the last 1.5 years, this process accelerated. He became more antisocial, unable to interact with employees and customers. His level of comprehension declined. He became more aggressive towards his wife and children. He often manifested frank paranoia and suspiciousness, accusing his wife of unreal, sexual infidelity. During the last 1.5 years, a significant gait disturbance had also developed, with impairment of balance. A slowing in speech and a tremor of hands had developed over the previous year.

The patient had been born in Poland. All significant infections were denied. He had received injections of “liver” and B12 after the war “for anemia” but had received no recent B12 injections.

Neurological examination:

1. *Mental status:* The patient was oriented for time, place and person.

Delayed recall was markedly impaired none of five in five minutes without assistance, one of five with assistance. Repetitions and naming of objects were intact. Distant (remote) memory was good. The patient could list all major world leaders during World War II and all assassination attempts.

The patient was often tangential in his responses and often initiated irrelevant conversations.

Serial 7 subtractions could not be done but the patient could reverse 12 months of the year.

Abstract reasoning for similarities was poor.

He often got up from the bed and looked outside the curtain, checking the activities of his roommate.

2. *Cranial nerves:* Pupils were small, 2 mm., and irregular but did respond to light.

Twitching and grimacing of face, eyelids and tongue occurred. He also had a lid lag.

3. *Motor system*: Strength was intact. Gait was wide-based, with a positive Romberg test. The patient was quite tremulous with occasional myoclonic jerks. He could not do rapid alternating movements.

4. *Reflexes*: Deep tendon reflexes were normal (2+) in the upper extremities, trace at patellar and absent at Achilles. Plantar responses were flexor, bilaterally. There was no release of the grasp reflex. Other frontal release signs were absent.

5. *Sensory system*: Pain, touch and position sense intact. Vibration was markedly decreased at toes, and ankle with minor preservation at knees.

Clinical diagnosis: Progressive dementia and personality change. Multiple entities to be considered including (1) the combination general paresis and tabes dorsalis, (2) B12 deficiency, (3) frontal lobe tumor, (4) frontal dementia and (5) Lewy body dementia

Laboratory data: The abnormal findings included:

1. *Vitamin B12 level* was borderline low at 209 picograms/ml., *Schilling test*, however, demonstrated normal absorption (25.4% excretion of radioactive B12 in urine).

2. Serum serological test for syphilis (RPR) was reactive with the more specific FTA markedly reactive.

3. *Cerebrospinal fluid*: 98 white cells were present - all lymphocytes. CSF protein was elevated to 116 mgs.% (normal <45 mgs.%). Sugar was low at 44 mgs.% with a simultaneous blood sugar of 90. Spinal fluid serological test for syphilis (VDRL) was positive.

4. *CT scan* showed mild frontal and temporal atrophy

Subsequent course: The patient was hospitalized for two weeks and received high dosage intravenous penicillin therapy, three million units every four hours for 10 days (18 million units per day).

When seen again 2 months later, the patient and his family reported that gait and coordination had significantly improved. Memory and personality had not improved. He still had episodes of agitation and irritability. Reflex and sensory findings were unchanged. The patient had been inconsistent in taking any medication such as haloperidol, aimed at altering his agitation.

He failed to return again for 18 months. Paranoid ideation had become more prominent. He could no longer manage his fiscal affairs. Orientation and delayed recall were intact. There was minor tremor of the hands and an unsteadiness of gait. Romberg was positive although position and vibratory sensation were intact. Serum serology was now negative. Lumbar puncture now indicated no significant cells, a normal protein.

Subsequently he did require hospitalization for renal failure secondary to enlarged prostate and a neurogenic bladder. Spinal fluid VDRL and serum RPR serological tests for syphilis, were both nonreactive. Serum FTA ABS - a much more specific and more sensitive test for previous syphilis was still 3+ reactive.

Telephone follow-up 11 years after the initial episode indicated that personality and cognitive changes had essentially leveled off, irritability and hostility were less. He had no urinary problems. He was unsteady in walking, but was still able to drive small distances and was living at home. Additional information approximately 20 years after the initial evaluation indicated that he spoke very little, he no longer demonstrated agitation. His mobility was more limited. Of interest, one pupil no longer responded to light but did respond to accommodation. CT scan demonstrated greater atrophy.

Comment: This patient had clinical manifestations predominantly related to general paresis. Both the history and the examination also provided evidence of tabes dorsalis. Penicillin therapy resulted in a non-active state, as regards serum serology and any cellular activity in the spinal fluid. However, the damage to cerebral cortex was not reversed and continued to provide a significant problem, as regards personality function. Thus, once cognitive function has been altered, due to damage to and loss of neurons, the changes in memory and personality may be persistent. Disturbances of frontal lobe and limbic system function once initiated may continue to evolve.

Moreover once the patient reaches the late 60's and the 70's, apparent progression of neurological changes in memory and other cognitive functions may occur related to the combined effects of the previous acquired lesions of general paresis and the effects of even mild Alzheimer's disease. A double hit has occurred.

The following case provides an example of a patient whose initial symptoms related primarily to a severe alteration in personality function and social interactions. Features of Parkinson's disease were apparent on her examination. Diagnosis was uncertain but diffuse Lewy body dementia should be considered.

Case 30-6: This 60-year old, right handed separated white housewife, residing in a nursing home, was referred for evaluation of problems in walking, progressive behavioral change and memory disturbance. Six years previously at age 54, a change in behavior was first noted by her family. She began to accumulate papers about the house. She would leave the shades down all day, and expressed fears that people would break into her house. As a result, she became isolated from her neighbors and friends. Shortly there after, she made repeated phone calls to the local police and it was apparent that she was confused. After investigation, the police had to break into the house and take her to an emergency room. In the emergency room she was described as confused and frightened. Paranoid ideation was prominent with considerable self-referral ideation. Thought process was described as tangential, with considerable perseveration. There was poor insight and judgment was impaired. She was confused as to time and place and she could recall two of three objects in 5 minutes. She had great difficulty with serial sevens, often losing track of the number to be subtracted. Judgment and insight were poor. She would read a book by rapidly turning the pages, but then had little recall of what she had read. With treatment with haloperidol, lability of mood and paranoia decreased. A CT Scan demonstrated "mild cortical atrophy". The patient was then transferred to a nursing home with a diagnosis of Alzheimer's Disease. In retrospect, a gait problem had also been present in January 1984, about the time that her symptoms had begun, and prior to the use of haloperidol. The patient was walking flexed with small steps. These gait problems progressed so that she was unable to stand up from a chair and was unable to walk. She had become fearful of walking.

Family History - Indicated parents died at ages 70-80 years, without neurological disease. A sibling was age 79 without neurological disease.

Neurological examination:

1. *General:* A thin female appearing older than her stated age. She sat in a wheelchair with little facial expression and with little body movement. She was passive in the interview situation -allowing her husband to provide many answers.

2. *Mental Status:* She was oriented to the year but when requested to provide the month and day, she answered "it is the beginning of school time". As regards the location, she gave the name of the town where she formerly lived but could not name the town where the nursing home was located. She did name the nursing home and then said "its a jazzy place with more facilities, most of the people there are nice, some just sit around".

Asked to describe herself, she said, "I am nothing, I can't even take care of my child". She was, however, able to provide the name of her only daughter, now grown, and was able to indicate that the daughter had been born in 1945 in Philadelphia (all of which the husband verified as correct).

Asked to indicate her own birthplace and birth date, she indicated she herself had been born at home in Fitchburg in 1925 and then added, "I imagine everything has been tossed out there". When I asked "what had been tossed out?", she provided a tangential answer, "I do not know you" and then rambled on to a conversation topic about her husband's trip to Turkey on a "Fulbright" - some time in 1960 or 1970.

Delayed recall even with multiple choice assistance was zero out of five in five minutes. For serial seven subtractions, 100 - 7 "might equal 86 or might equal 55". She could name 3 out of 5 objects, could do repetitions, could write her name but not her address and refused to draw a house (? unwilling, ? unable).

3. *Cranial Nerves:* Intact except for a tremor of the closed eyelids and a positive glabellar sign. There was a lack of facial expression.

4. *Motor System*: Strength was difficult to assess, but appeared intact when maximal effort was made. Significant akinesia and bradykinesia were present. There was cogwheel rigidity of minor degree at wrist and elbow. There was variable resistance at hip and knee, which had primarily the character of frontal lobe type "Gegenhalten".
The patient had to be assisted to the standing position from her wheelchair. In the standing position, initially, her feet appeared to be stuck to the floor, as in a magnetic foot syndrome. Eventually, she was able to take small shuffling steps, as assistance was provided by holding her outstretched hands lightly. If unsupported, she tended to fall backwards - whether standing or walking.
 5. *Reflexes*: Deep tendon reflexes were physiologic at 2+ except for Achilles - 1+. Plantar responses were equivocal. There was marked release of the grasp reflex.
 5. *Sensory system*: Pain and vibration were intact. Position sense could not be tested.
- Clinical diagnosis:** Lewy body dementia , or a variant of frontal dementia.

Laboratory data:

1. *Metabolic surveys* were not remarkable in terms of electrolytes, BUN, creatinine, glucose, hepatic functions, vitamin B12, folate levels and thyroid functions.
2. Routine serum serological test and FTA absorption for syphilis were negative.
3. *Sedimentation rate* was moderately increased to 53 mm/hr. *Alkaline phosphatase* was elevated to 272 and bone scan suggested possible Paget's Disease.
4. *EEG* demonstrated a slow dominant awake activity of 6-7 Hz (compared to normal alpha rhythm of 8-13 Hz). In addition, rhythmic bilateral delta slow wave were present, most prominent in the frontal recording areas.
5. *CT Scan*, demonstrated marked cortical atrophy with enlargement of sulci, ventricular system and cisternal spaces.

Subsequent course:

The patient continue a slowly progressive course to the present time. According to her primary physician, she is essentially restricted to bed. She remains, from a medical standpoint, relatively clear of other medical problems and complications - at age 67, 13 years after onset of the disease.

Comment: The diagnosis in this case is uncertain . The patient at age 54 had the onset of a significant change in behavior which resulted in major problems in interpersonal relationships. Initially, she had been able to live by herself in her small seaside community. Eventually, however, the frequent night calls to friend, neighbors, and the police, resulted in her coming to medical attention. Even at that point, the patient's separated husband, who visited her frequently and supported her, appeared unaware of the patient's confusion and memory deficit. The husband had considerable difficulty appreciating the degree of disability. Such a pattern is not unusual.

In contrast to the previous case histories of this chapter, the memory problems were far beyond the selective involvement of recent memory seen in Wernicke's or hippocampal lesions. Moreover, a more diffuse involvement of other cognitive functions was present. As the disease progresses, motor aspects become prominent, indicating the effects of involvement of frontal and premotor areas. Mild "Parkinsonian" features may appear, due to either the medications employed (neuroleptic agents such as pheno thiazides, haloperidol, etc.) or to alterations in the frontal premotor basal, nuclei circuits or to loss of neurons, at the level of S. nigra or basal nuclei. Note however that the gait problems occurred prior to the use of haloperidol. The CT scan did not demonstrate the focal atrophy seen in frontotemporal dementia .Therefore the most likely diagnosis might be diffuse Lewy body dementia since personality changes were most prominent at onset, and Parkinsonian features developed early in the disease course. Contrast this case to the Alzheimer disease patient of case 30-4 in which the initial problems were restricted to changes in memory.

When seen at age 60 this patient was clearly late in her disease course. As indicated, remedial causes of the syndrome of progressive dementia must be ruled out. The effects of medication must be considered. Moreover, however, any masking depression should be treated. At this point in time, no specific therapy to reverse the progressive course of the disease is known.

Case 30-7: This 74-year-old right-handed widow presented to the emergency room at St Vincent hospital on 2-19-02 with an 8-10 week history of worsening memory problems. In December 2001, accompanied by her boyfriend she made her annual trip to Florida. Although she had been in her usual state of independent living prior to her departure, she was found to have serious problems with

memory on arrival. She was unaware as to where she was. In a telephone conversation with her daughter, “she was talking nonsense”. During the next 2 months, memory and word finding continued to deteriorate. She was taken to the emergency room of the local hospital in Florida where a CT scan without contrast on 02/07/02 demonstrated mild cortical atrophy but no acute process. Her son drove to Florida and found that her memory was poor and her conversation did not make sense. “My husband is in the service: my mother died last year.” However she could play cards with her grand daughter. Her gait was slow and stooped. She had urinary incontinence on her way to the bathroom.

She had no history of alcoholism and took various vitamins and herbs.

Family history: her brother had died of a brain tumor of unknown type.

Neurologic examination: The positive findings were the following:

1. *Mental status:* The patient was awake and alert. Overall Mini-Mental Status Score was 19/30. The major problems were in orientation and in delayed recall. She was able to indicate that she was in a hospital in Massachusetts. And the date was February. She registered 3 objects but could recall any in 3 minutes. She was however able to read, name objects, follow instructions, spell “world” backwards and copy a figure. She was unable to draw a clock with the hands set at 11:10.

2. *Cranial nerves:* intact

3. *Motor system:* Although strength and tone were normal, her gait was broad-based and shuffling.

4. *Reflexes:* Patellar and Achilles reflexes were absent but plantar responses were flexor.

5. *Sensory system:* Intact.

Clinical diagnosis: 1) Subacute dementia: etiology uncertain possibly of Alzheimer’s or Lewy body type. Various entities such as chronic subdurals, tumor etc to be ruled out 2) Peripheral neuropathy, most likely etiology at this age diabetes mellitus.

Laboratory data:

1. *Basic CBC and chemistries:* Normal except for an elevated fasting glucose.

2. *CT scan (Fig 30-10):* An enhancing 2.75 cm tumor with a necrotic center was present in the thalamus at the level of the upper third ventricle. There was bilateral involvement of the anterior and medial thalamus but with no involvement of the posterior thalamus or hypothalamus. The study suggested a lymphoma or glioblastoma

Subsequent course *Stereotaxic biopsy of the right thalamus:* Frozen section raised the question of a lymphoma or glioblastoma but special immunological stains were consistent with a glioblastoma. Necrosis and endothelial hyperplasia were present. The patient was treated with dexamethasone and radiotherapy with improvement in gait.

Comment: This patient presents an unusual cause of a progressive alteration in memory. As indicated earlier in this chapter those patients with Wernicke’s encephalopathy who progress to the Korsakoff syndrome had persistent pathology in the medial and anterior thalamus with sparing of the posterior thalamus. In this case the pathology was a rapidly progressive glioblastoma multiforme. As discussed above, an occasional patients, glioblastomas may also produce dementia and a change in personality by infiltrating the prefrontal areas and corpus callosum. Occasionally a patient with a more diffuse neoplasm gliomatosis cerebri may also present with a similar syndrome of dementia which may mimic Alzheimer’s disease. These are however rare causes compared to the more frequent degenerative disorders.

COMPLETE CASE HISTORIES FROM TEXTBOOK: *INTEGRATED NEUROSCIENCES*
PART IV. CASES; CEREBRUM VISION, DISEASES, MEMORY

CHAPTER 23: VISUAL SYSTEM

The following case is an example of a lesion involving the optic nerve, anterior to the optic chiasm.

Case History 23-1 (Fig 23-8).

This 53-year-old white right-handed housewife was referred for evaluation of progressive right-sided supraorbital headache of 23 years duration and decreasing acuity in the right eye. The loss of acuity had progressed to the point of almost total unilateral blindness. During the 3 years before admission, intermittent tingling paresthesia had been noted in the left face, arm, or leg. About 1 year before admission the patient had a sudden loss of consciousness and was amnesic for the events of the next 48 hours. She was hospitalized, but no explanation for the episode was clearly established, although cerebrospinal fluid protein was reported to be elevated (230 mg/dl).

The patient and her family reported some personality changes over a period of several years, including a loss of spontaneity and increasing apathy.

General Physical Examination: Unremarkable except for a minor degree of proptosis (downward protrusion of the right eye).

Neurologic Examination:

1. *Mental Status*: The patient was, in general, alert but at times would become lethargic. Her affect was flat. At times, she would laugh or joke in an inappropriate manner.
2. *Cranial Nerves*: There was anosmia for odors, such as cloves, on the right and a reduced sensitivity on the left.

Marked papilledema (increased intracranial pressure with protrusion of the optic disk and venous engorgement due to obstruction of the normal flow of CSF) was present in the left eye.

Pallor of the right optic disc was present, indicating optic atrophy. Visual acuity in the right eye was markedly reduced. The patient had only a small crescent of vision in the temporal field of the right eye, where only vague outlines of objects could be seen. A slight left central facial weakness was present.

3. *Motor Systems*: Intact although movements on the left side were slow.

4. *Reflexes*: A release of grasp reflex was present on the left side.

5. *Sensory system*: Intact

Clinical diagnosis: Subfrontal meningioma arising from olfactory groove or inner third sphenoid wing.

Laboratory data:

1. *Skull x-rays* demonstrated erosion of the dorsum sellae. Special lamniograms demonstrated hyperostosis of the sphenoid bone (planum sphenoidale) suggesting a meningioma originating from the sphenoid bone.

2. *EEG* demonstrated focal 2-4 Hz slow waves in the right anterior temporal and anterior lateral frontal area.

3. *Brain scan (Hg 197)* revealed a heavy uptake of isotope in the right posterior subfrontal area.

4. *Arteriograms* indicated that the anterior cerebral arteries were shifted backwards, posteriorly and the left. A tumor blush was present on the venous phase in the right subfrontal area extending back to the optic nerve groove (Fig 23-8). These findings were felt to be most consistent with an olfactory groove meningioma.

Hospital course: Dr. Samuel Brendler performed a bifrontal craniotomy which exposed a well-encapsulated smooth tumor attached to the medial third of the sphenoid wing. After intracapsular removal of 90 to 95% of the tumor, the right optic nerve could be visualized. The small portion of the tumor attached to the bone could not be removed because of considerable bleeding from the bone. Examination 4 months after surgery, indicated right anosmia and right optic atrophy were present.

Comment

If one considered only the patient's primary complaint, decreasing vision in the right eye, and the findings of right optic atrophy and left-sided papilledema (Foster-Kennedy syndrome), then the most probable diagnosis was inner-third sphenoid meningioma. The preservation of a small crescent of vision in the temporal field is consistent with compression of the optic nerve on its lateral surface. By the time of hospitalization, the lesion was quite large and had extended into the subfrontal area, producing anosmia on the right and some changes in personality. At this point, the various diagnostic studies suggested only a subfrontal mass and did not clearly differentiate between an olfactory-groove meningioma and a sphenoid-wing meningioma. One might suggest, in retrospect, that the degree of involvement of the right optic nerve was much more pronounced than the changes in prefrontal functions, and therefore, the inner-third sphenoid-wing location was more likely.

The surgical approach in any case was the same. The eventual recovery of vision in such cases is uncertain because the effects of compression often are not reversible.

The following case 23-2 provides an example of a macroadenoma of the pituitary producing a bitemporal adenoma..

Case 23-2. Patient of Dr. Martha Fehr. This 45-year-old man had an 18-month history of a progressive alteration in vision. He was unable to see objects in the right or left periphery of vision. He was concerned that in the process of driving he might hit pedestrians stepping off the sidewalks in the periphery of vision. He had also experienced over 6-8 months, progressive headaches, loss of energy and libido.

Neurological examination: Normal except for a bitemporal hemianopia.

Clinical diagnosis: Pituitary adenoma compressing the optic chiasm.

Laboratory data:

1. *Endocrine studies:* all were normal including prolactin, am cortisol, and thyroid functions.

2. *MRI:* A large macroadenoma measuring 3 cm in diameter extended outside of the sella turcica to compress the optic chiasm (fig. 23-11).

Subsequent course: Dr. Gerald McGuillicuddy performed a gross total trans sphenoidal resection of the tumor, with a significant improvement in vision. Three years later, the patient again had visual symptoms and eye pain. MRI scans indicated regrowth of tumor with possible impression on the right optic nerve. He was treated with radiotherapy.

Comment: Note that males are more likely to present with large pituitary adenoma compressing the optic chiasm. Women are more likely to present with microadenomas or small macroadenomas since they are more likely to be seen at an earlier stage due to an initial complaint of amenorrhea. Thus complaints of decreased libido in men are likely to be mentioned only in retrospect and not as an early presenting complaint.

The following case illustrates the effects of a space-occupying lesion in the occipital lobe. One should compare these findings to those reported earlier in Case 23-1, in which there was a lesion in the visual system anterior to the optic chiasm.

Case 23-3: This 47-year-old white, right-handed, real estate salesman was referred for evaluation of headache and visual disturbance. One month before admission the patient had a cough with some blood present in the sputum (hemoptysis). Five days before admission the patient developed a generalized headache, which was

precipitated by coughing or straining and which awakened him or prevented him from sleeping.

Two days before admission, the patient noted blurring in the left inferior quadrant of his field of vision.

The day before admission, he noted complete loss of vision in this quadrant. On the day of admission, the headache increased, and the patient was unable to see anything in the left visual field.

He had experienced no weakness, no disturbance of memory, and no language disturbance.

Past history was significant. The patient had multiple pulmonary infections, treated with antibiotics.

Neurologic examination:

1. Mental status: Intact

2. *Cranial nerves* were intact, except that blurring of disc margins was present bilaterally, with venous engorgement, indicating early papilledema.

A left non congruous homonymous hemianopia was present (Fig. 23-14A).

3. Motor system: Intact

4. Reflexes: *Deep tendon reflexes were slightly more active on the left. The plantar response on the left was extensor that on the right was flexor*

Laboratory data:

1. *Electroencephalogram* was abnormal because of frequent focal 3 to 4 cps, slow waves in the right occipital area and to a lesser degree, in the right posterior parietal area, consistent with focal damage in the right occipital area.

2. *Cerebrospinal fluid* pressure was elevated to 210 mm H₂O. The number of white blood cells was increased to 97 lymphocytes (upper normal limit is 5 to 7 lymphocytes). Protein was increased to 75 mg/dl (upper normal limit is 45 mg/dl). Glucose was 75 mg/dl (normal when compared to blood sugar of 95 mg/dl).

3. *Imaging* (radioactive brain scan Hg 197) demonstrated an enhanced region in the posterior and medial aspect of the right hemisphere (occipital and adjacent parietal lobes).

Subsequent course: The patient was treated with antibiotics (cephalothin sodium, penicillin, and streptomycin). Visual fields, EEG, and spinal fluid findings improved. Within 3 weeks the field defect had resolved to a non congruous left inferior quadrantanopia (Fig. 23-14B).

Ten days later the patient was readmitted to the hospital with a three-day history of right eye pain, sweats, and chills. Neurologic examination now revealed a recurrence of blurred optic-disc margins, a left homonymous hemianopia and a slight increase in deep tendon reflexes on the left. Imaging studies now revealed a large space-occupying lesion in the right parietal/occipital region, displacing the right lateral ventricle forward and downward.

After 10 days treatment with antibiotics (penicillin and streptomycin), a craniotomy was performed by Dr. Bertram Selverstone. A mass could be palpated medially in the right occipital and adjacent posterior parietal area. The abscess and a large surrounding area of hard granulomatous cortex and white matter were removed. (The etiologic organism was subsequently found to be a *microaerophilic streptococcus*.)

Postoperatively, the patient continued on treatment with penicillin. Follow-up examination 6 months after surgery was normal, except for the left homonymous hemianopia (Fig. 23-14C).

Comment: The rapid evolution of neurologic signs and symptoms in this case; the early development of papilledema, and the progressive changes in the electroencephalogram and brain scan; is consistent with the diagnosis of brain abscess. The primary infection in this case was probably in the lung.

The initial visual symptoms of inferior field involvement (quadrantanopia) suggested that the abscess, in its early stages, involved predominantly the superior portion of the optic radiation in the posterior parietal/occipital area or the superior bank of the calcarine fissure. With progression of the lesion, the entire optic radiation or the entire calcarine cortex was involved. The lesion found at surgery had destroyed or damaged both these areas.

The treatment of a brain abscess requires appropriate pre- and postoperative use of antibiotics. Many of these patients develop focal seizures at some time after successful surgical treatment of the abscess. Although prophylactic anticonvulsant medication, such as diphenylhydantoin (Dilantin), has been routinely administered, the value of such treatment remains unclear.

Note an important negative finding in this case: at no time did the patient experience any language disturbance. Reading and writing remained intact, as did the capacity for to construct drawings. This case involving the right occipital lobe should be compared with Case History 21-2, in which a focal lesion of the left occipital lobe was present.

The following is another example of the effects of a lesion in the occipital lobe with very different consequences than those seen in the previous case. The lesion clearly involved the cerebral cortex producing focal seizure activity.

Case 23-4. (Fig 23-15): This 18-year-old left-handed single white female restaurant employee was referred for reevaluation of a seizure disorder. While living in the south western United States, the patient had the onset of her seizures at age 14 when she had a sequence of five seizures in less than 12 hours. Each began with flashing lights, “like Christmas tree lights,” all over her visual field, plus the sensation that peoples’ faces were moving. She then would have an apparent grand mal seizure. She was hospitalized. The neurological examination was reported as normal. An electroencephalogram report noted occasional focal sharp and slow waves in the left hemisphere. The CT scan was interpreted as essentially within normal limits. In retrospect, there was a question of some mottled hypodensity in the left occipital area, not clearly distinguished from artifact. The patient was treated with carbamazepine (Tegretol), 400 mg in the morning, and 230 mg at hour of sleep. In the interim, she apparently had done quite well with no additional grand mal seizures. She had rare episodes of “fear attacks,” which would last 23 to 25 minutes. The last attack had occurred 2 years ago, but as recently as two months ago, she had had one episode of flashing lights. A recent EEG was normal.

Past history was negative, except her birth weight was ten pounds, three ounces, and there was a problem of breathing at birth. She had always done poorly in school. Her family history did not suggest possible causes for a seizure disorder.

Neurologic examination: Normal.

Clinical diagnosis: Seizures of focal origin occipital cortex, (flashing lights and movement of the lights) probably left hemisphere based on the reports received of the EEG. There was subsequent spread of discharge into the temporal lobe based on the report of “fear attacks”

Subsequent course

The patient did well for 3 years then had a recurrence of a generalized convulsive seizure possibly related to omission of medication. Six weeks later, she reported two additional episodes characterized by flashing lights, then movement of the lights away from a center circle, then dizziness, then a

sensation of unreality. She also had other episodes of feeling unreal accompanied by fear. There were no olfactory hallucinations and no other visual or auditory hallucinations. The neurologic examination now demonstrated a minor right central facial weakness not present previously.

Laboratory data:

1. *EEG*: remained normal.
2. *MRI scan*: now revealed a small tumor at the left occipital pole with surrounding edema (Fig. 23-15). On CT scan, this tumor appeared partially calcified but did show enhancement. Angiograms suggested tumor vascularity of a type seen with meningiomas.

Subsequent course: Dr. Bernard Stone removed a discrete encapsulated tumor that appeared to be a meningioma. Subsequent microscopic examination, however, indicated a rare type of indolent follicular adenocarcinoma of the thyroid, which sometimes spreads as a single lesion to brain and remains quiescent for many years. In the postoperative period, a non-congruous right-inferior-field defect was present (partial quadrantanopia). The blood level of thyroid-stimulating hormone (TSH) was elevated. A thyroid nodule was found. A thyroidectomy was performed, and thyroid replacement medication was prescribed. No additional seizures were observed over the next 18 months. A metastatic lesion in the lumbar vertebral body subsequently appeared.

Comment: This patient presented many of the features of focal seizures arising in the occipital cortex: flashing lights, movement of objects and secondary generalization. Some of the seizure phenomenology such as “fear attacks,” dizziness, and “feeling unreal” suggested that spread into the temporal lobe was sometimes occurring. The student should now compare and contrast the cases presented in the previous chapter on the limbic system to this case to be able to note the differences seen after lesions in these adjoining cortical regions.

CHAPTER 24: SPEECH, LANGUAGE FUNCTION, APHASIAS, AGNOSIAS, APRAXIA

The following case, 24-1 presents an example of a selective non fluent aphasia of aphasia. An embolus to the superior division of the left middle cerebral artery produced marked weakness of the face tongue and distal right upper extremity and a severe selective nonfluent aphasia. The

hand weakness rapidly disappeared, the right central facial weakness, an apraxia of tongue movements and some expressive difficulties persisted.

Case 24-1: This 55-year-old, right-handed white housewife while working in her garden at 10:00 a.m. on 04-15-69, the day of admission suddenly developed a weakness of her right side and was unable to speak. Apparently, the right-sided weakness affected predominantly the face and arm since the patient was able to walk. The past history was significant. In 1960, nine years previously, the patient had been admitted to the hospital with a three-year history of progressive congestive heart failure secondary to rheumatic heart disease (mitral stenosis with atrial fibrillation). An open cardiectomy was performed with a mitral valvuloplasty (the valve opening was enlarged). A thrombus found in the left atrial appendage was also removed. Postoperatively, the patient was given an anticoagulant, bishydroxycoumarin (Dicumarol). Although atrial fibrillation continued, she did well until the day of admission. Prothrombin time at the time of admission was close to normal; that is, the patient was not in a therapeutic range for anticoagulation.

General physical examination: Blood pressure was moderately elevated to 170/80. Pulse was 110 and irregular (atrial fibrillation). Examination of the heart revealed the findings of mitral stenosis: a loud first sound, a diastolic rumble and an opening snap at the apex as well as the atrial fibrillation.

Neurological examination:

1. Mental status and language function:
 - a. The patient was alert.
 - b. She had no spontaneous speech and could not use speech to answer questions and could not even use yes or no to provide answers. She could not repeat words.
 - c. The patient was, however, able to indicate answers to questions by nodding (yes) or shaking her head (no), if questions were posed in a multiple choice situation. In this manner it was possible to determine that she was grossly oriented for time, place and person.
 - d. The patient was able to carry out spoken commands and simple written commands, such as, "hold up your hand, close your eyes." However, she had significant difficulty in performing voluntary tongue movements (such as "wiggle your tongue"; "stick out your tongue") on command.
2. Cranial nerves:
 - a. The patient tended to neglect stimuli in the right visual field.
 - b. She was unable to look to the right on command although the head and eyes were not grossly deviated to the left at rest.
 - c. A marked right supranuclear (central) type facial weakness was present.
 - d. The patient had difficulty in tongue protrusion. When the tongue was protruded it deviated to the right. The patient was unable to wiggle the tongue.
3. *Motor system:* Strength: there was a marked weakness without spasticity in the right upper extremity, most prominent distally. Some shoulder movements were possible; no hand or finger movements could be made. There was a minor degree of weakness involving the right lower extremity (75 percent of normal).
4. Reflexes:
 - a. Deep tendon stretch reflexes were increased on the right in the arm and leg.
 - b. Plantar responses were both extensors; more prominent on the right.
 - c. The abdominal reflex was absent on the right; present on the left.
5. Sensory:
 - a. Pain, touch and vibration were intact.
 - b. It was difficult to test other modalities but tactile localization appeared to be intact.

Clinical diagnosis: Embolus from heart to left middle cerebral artery

Laboratory data:

1. *Skull X-rays* were normal.
2. *EEG* was normal (48 hours after admission).
3. Cerebrospinal fluid was normal.
4. *Electrocardiogram* revealed atrial fibrillation

Hospital course: Within 24 hours a significant return of strength in the right hand had occurred; independent finger movements could be made. Within 48 hours after admission the patient was able to

repeat single words but still had almost no spontaneous speech. She appeared aware of her speech disability and would manifest some frustration. She was able to carry out two- or three-stage commands although tongue movements and perseveration remained a problem. Within 6 days of admission the patient used words, phrases and occasional short sentences spontaneously. She was better able to repeat short sentences. At this time strength in the right arm had returned to normal, but a right central facial weakness was still present. More detailed language evaluation two weeks after admission indicated the persistence of expressive disabilities consisting of word-finding and apraxic components. The apraxic components were evident on tongue placement and alternating tongue movements. Although complete sentences were used, sentence formulation in spontaneous speech was slow and labored with word finding difficulties. Repetition was better performed. In reading sentences aloud, substitutions or word omissions were made. The patient did well in naming common pictures and in matching printed words to spoken words or printed words to pictures. She could write from dictation and would often respond preferentially in writing when difficulty in speaking was encountered. No left-right confusion was present. Minor difficulties with simple arithmetic were reported. A right central facial weakness was still present.

Comment: There would appear little doubt that this patient had the sudden passage of an embolus (presumably from the left atrial appendage) into the left middle cerebral artery. In view of the selective face and arm weakness with a predominant expressive aphasia, the involved vessels must have been cortical branches such as the prerolandic and rolandic originating from the superior division of the middle cerebral artery. From the onset, it was clear that although some receptive components might be present, these were minor. The major problem was a severe nonfluent aphasia. As the hand weakness disappeared, the only other residual neurological findings were those of a right central facial weakness and an apraxia of tongue movements. Such findings would, of course, be consistent with a relatively selective involvement of Broca's area in the inferior frontal gyrus.

Why did such a rapid improvement occur in motor function and of the visual field? Most likely, the embolus fragmented and passed into the cortical branches supplying Broca's area.

With the passage of time, this type of patient would continue to show some degree of improvement (Mohr, 1973). Improvement could continue to occur over a two-year period. Although lesions of Broca's area may produce the acute onset of a nonfluent aphasia, rapid amelioration of the deficit occurs even when the acute lesion involves underlying white matter, as well as the superficial cortex.

In the following case 24-2, a more persistent anterior aphasia is demonstrated.

Case 24-2: On May 30, 1985, at midday, this 37-year-old right-handed woman with a past history of rheumatic fever, rheumatic heart disease and "an irregular pulse"(atrial fibrillation) had the sudden onset of loss of speech, central weakness of right face, an inability to protrude the tongue and a right hemiparesis. Although hemiparesis, face and tongue problems disappeared within a week, recovery of speech was slower and limited. At one week, she could produce some two syllable words.

Neurological examination at 17 months revealed the following residual findings:

1. *Language function:* Spontaneous speech was slow and relatively scanty. She could name objects slowly without difficulty, could do some simple repetitions and could write from dictation. She could carry out two and three stage commands. She could read slowly aloud but had little comprehension of what she read.
2. *Reflexes:* A residual right Babinski sign and right-sided hyperreflexia were present.

Clinical diagnosis: Anterior aphasia: embolic infarct of superior division of middle cerebral artery.

Laboratory data:

Although initial CT scans in May 1985 had been reported as negative; the MRIs in November 1986 and June 1990 demonstrated the infarct which included Broca's area, as well as adjacent frontal areas with predominant involvement of frontal operculum (inferior frontal gyrus) and adjacent middle frontal gyrus. In addition, a minor independent infarct was present in right occipital area (presumably embolic to the calcarine artery).

Subsequent course: Similar findings were present at 5 years, June 1990).

A brain section from a patient (Case 24-3) with a persistent nonfluent aphasia (is presented in Figure 24-4.

Case 24-3: This 69-year-old, right-handed male expired in 1965. In 1961 and 1963, The patient, had experienced transient episodes of right hemiparesis and aphasia, both followed by complete recovery. In 1964, a more persistent right hemiparesis and aphasia had developed.

General physical examination: No left carotid pulsation was present.

Neurologic examination(1965):

1. **Language functions:** Speech was nonfluent with only a small verbal output. A significant nominal aphasia with paraphasias was present. Reading was limited. Comprehension of spoken language was good. A marked apraxia was present for movements of tongue, lips and hands.
2. **Motor system:** Right hemiparesis with associated reflex findings.
Post mortem findings: Left carotid occlusion with old infarction, predominantly of left middle cerebral territory with lesser involvement of anterior cerebral territory. Note that minor cortical infarcts are also present involving cortex of right hemisphere.
(Courtesy of Dr. John Hills,; and Dr. Jose Segarra.)

Case 24-4 provides an example of a patient with a Wernicke's type aphasia

Case 24-4: This 40-year-old, right-handed white male had experienced a series of myocardial infarctions beginning 10 months prior to consultation. Angiographic studies indicated occlusion of the right coronary artery and the left anterior descending coronary artery with stenosis of the circumflex artery. The patient was subsequently admitted and a coronary artery bypass procedure was performed using extracorporeal circulation. Although the patient was stated to have tolerated the procedure well, the anesthetist noted that the patient was nonreactive 15minutes after the last administration of halothane anesthesia. When the patient did wake up, he was quite agitated requiring the use of agents to reduce agitation. Throughout the postoperative period, the patient continued in a disoriented and combative manner. Because of the patient's acutely psychotic state, transfer to the psychiatry service was actively planned. Because there were certain organic features to the patient's illness, a neurological consultation was obtained. The neurology resident in reviewing the progress notes discovered a notation that shortly after surgery the patient had transient difficulty in using his right arm.

Neurological examination:

1. **Mental status:**
 - a. The patient was an alert but agitated white male. Additional inquiries indicated that his agitation related to his inability to write a letter to his mother.
 - b. The patient's speech was fluent and usually grammatical. He made use of many paraphasias and neologisms (nonsense words). He often appeared unaware of his errors.
 - c. The patient was unable to name single objects such as pencil, cup, and spoon though he could recognize and demonstrate their use.
 - d. The patient could read occasional individual words; for example, cat, house. He could not comprehend or carry out, either spoken or written commands.
 - e. His attempts at spontaneous writing produced only a few letters. He was unable to write words or phrases from dictation. He did significantly better when asked to copy a printed sentence or phrase.
- f. Repetition of spoken phrases or sentences was poor.
- g. Calculations of even a simple nature were poorly performed.
2. **Cranial nerves:** II-XII was intact.
3. **Motor system:** No actual weakness was present. Gait was intact.
4. **Reflexes:**
 - a. A minor increase in deep tendon stretch reflexes was present on the right side.
 - b. The plantar response on the right was equivocal. The left was flexor.
5. **Sensation:** Pain, touch and vibration were intact.

Clinical diagnosis: Wernicke's type of fluent aphasia probably secondary to an embolus to the inferior division of the middle cerebral artery.

Comment: This patient who was seen before the era of modern neuroimaging provides an example of the clinical picture described by Wernicke. The use of the heart pump for open-heart surgery was associated with a high incidence of cerebral

emboli. The incidence of this complication has decreased as technical advances have been made and as “time on the pump” has decreased. As we have stressed, for solving neurological problems, the details of the history are important if the appropriate diagnosis is to be made. In the patient who is unable to provide a history, the careful review of progress notes and of nurses notes will often provide the clue that allows diagnosis.

The following case history 24-5 demonstrates such a sequence of involvement in a tumor infiltrating the posterior temporal inferior parietal area starting with a conduction aphasia.

Case 24-5: This 42-year-old right handed truck driver noted fatigue and irritability 6-8 weeks prior to admission. Three to four weeks prior to admission, he noted he was using words which he did not mean to use and certain words would not come to him. He had two generalized convulsive seizures; each proceeded by a ringing sensation in the ears, during the week prior to admission.

Neurological examination:

1. Mental status and language function

- a. The patient was alert and oriented to time, place and person.
 - b. He was cooperative and able to carry out the four-step command: “stick out your tongue, close your eyes, hold up your hand and touch the thumb to your ear”. There was however evidence of a significant left-right confusion when laterality was introduced e.g. “left hand to right ear”.
 - c. The ability to do even simple calculations was markedly impaired with or without paper e.g. $100-9=99$.
 - d. Memory was impaired; with immediate recall object recall limited to 2/5 objects and delayed recall in 5 minutes limited to 0/5. Digit span was limited to 2 forward and 0 in reverse. (normal would be 7 forward and 6 in reverse).
 - e. There was little evidence of an expressive aphasia. Flow of speech was slow with only minor mispronunciations. Reading was slow but with few errors. The patient’s did have minor difficulty in naming objects-a mild nominal aphasia. The patient’s greatest difficulty was in repetition of simple test phrases. There were moderate defects in drawings of a house and a clock but few errors in copying simple figures. There was a significant dysgraphia with marked difficulty in writing a simple sentence spontaneously or in writing from dictation. On the other hand, the patient was much better able to copy a simple sentence. Significant errors were made in spelling.
2. **Cranial nerves:** All were intact except for a mild right central facial weakness.
 3. **Motor system:** Strength, gait and cerebellar functions were all intact.
 4. **Sensory system:** Pain, touch, vibration, stereognosis, simultaneous stimulation, graphesthesia, and position sense were all intact, but point localization was impaired on the right side.

Clinical Diagnosis: Fluent posterior aphasia, disconnection syndrome plus elements of Gerstmann’s syndrome (left right confusion, dyscalculia, dysgraphia) plus seizures of focal origin (Heschl’s gyrus posterior temporal lobe) with secondary generalization. All suggested a lesion in the left posterior temporal-posterior parietal area.

Etiology was uncertain but tumor (glioma) or embolus to inferior division of left middle cerebral artery possible.

Laboratory data:

1. Skull and chest x-rays were normal.
2. **EEG:** Focal 4-5 Hz slow wave activity was present in the left parietal and posterior temporal areas.
3. **Brain scan (radioactive Hg 197):** Increased up take of isotope in the left posterior temporal –parietal area measuring 4x5 cm.
4. **Left carotid arteriogram:** Vascular mass in the region of the angular gyrus with tumor stain in the area.

Subsequent course: Papilledema soon developed and Dr. Robert Yuan performed a craniotomy. Although the cortex appeared externally normal, a firm mass could be palpated

slightly above and posterior to the angular gyrus. At 2 cm below the surface, firm yellow tumor tissue was encountered. All visible tumor and adjacent cortex of the angular and supramarginal gyri were removed and a partial left temporal lobectomy was performed. Histologic examination indicated a highly malignant glial tumor with active mitosis and necrosis (a glioblastoma multiforme). Post operatively, the patient had a marked expressive and receptive aphasia. By 30 days after surgery, the patient had a significant improvement in fluency, he continued to have a severe posterior type of aphasia. He was unable to carry out simple commands. His speech was incoherent, with nonsense words and neologisms. He appeared unaware of his errors and did not appear frustrated by his failure to follow commands. In addition to this Wernicke's type aphasia, the patient was unable to repeat words of two syllables. He could do no calculations, had severe difficulties in copying drawings and was unable to even write his name. The patient received radiotherapy but his condition continued to worsen with the development of a progressive expressive and receptive aphasia and hemiparesis all suggesting the spread of a rapidly growing glioblastoma. Coma, pupillary changes and respiratory changes then intervened suggesting the effects of herniation of the residual temporal lobe. Death occurred 7 months after onset of symptoms, and 5 months following surgery.

Comment: The early language and mental status disturbances in this patient were most severe in those tasks requiring repetition. Thus the patient could repeat no more than two digits, was unable to repeat any of the test phrases and was unable to write from dictation at a time when he could copy a sentence. Any expressive aphasia was minor, and he was fluent. He had no evidence of Wernicke type aphasia, since he could carry out a four-stage command without difficulty. Reading was relatively well preserved compared to writing, calculations and drawing construction. All of these findings suggest (1) the speech reception Wernicke's area was disconnected from the motor association areas for speech and writing Broca's areas 44,45 and the related areas of the premotor cortex and (2) the inferior parietal areas associated with writing, calculations, drawing, and the ability to distinguish left and right were damaged. The lesion found at surgery was deep to the angular and supramarginal gyri, the location of the arcuate sulcus. The seizures that finally brought the patient to neurological attention were originating in Heschl's gyrus of the temporal lobe, which would be adjacent to the area of the tumor.

The clinical state at 30 days following surgery reflected the additional effects of ablation of the Wernicke's area as well as the accentuation of the preoperative state. There had been the transient appearance of an expressive aphasia probably reflecting minor effects of the procedure on Broca's area.

The neurosurgical approach to the management of a glioblastoma particularly those involving the speech areas of the dominant hemisphere have changed in 35 years since this patient was seen. A limited stereotaxic biopsy under CT scan guidance would be undertaken and the patient would then be treated with dexamethasone and radiotherapy. The end results would have been similar and actually may even have occurred earlier. The postoperative quality of language function may have been transiently better. Unfortunately this patient had a very malignant and aggressive tumor. The median survival of glioblastomas with surgery alone is 26 weeks, with the addition of radiotherapy; 52-60 weeks. Median means that 50% of patients are going to survive less than these median figures.

The following case (24-6) provides a case of posterior aphasia with the lesion documented with CT scan.

Case 24-6: This 57-year-old female, with a long history of hypertension in the summer of 1985, had a brief episode of difficulty in word finding and a more prolonged episode in December 1985 with confusion, "visual problems", "inappropriate speech and difficulty finding the appropriate words". Following an additional episode in March 1986, she had persistent problems in reading and apraxia of the right hand.

Neurological examination (May 1986): The following abnormalities were present:

1. *Language function:* Spontaneous speech was usually quite fluent. She described the room, the environment and her friend. In contrast, capacity for repetition was very poor both as regards spoken and written speech. Spontaneous writing was very poor except for name and address

Reading to herself aloud was poor with little comprehension. She was able, however, to follow single one stage spoken or written commands but unable to do a sequence of commands. Naming of objects was well performed.

2. *Cranial nerves*: Extinction occurred in the right visual field for bilateral simultaneous stimuli.
3. *Motor system*: No hemiparesis was present.
4. *Reflexes*: Right-sided hyperreflexia and a right Babinski sign were present.

Clinical diagnosis: Posterior aphasia, infarction left posterior temporal and parietal areas, probably due to embolic occlusion of inferior division of the left middle cerebral artery.

Laboratory data:

1. *CT scan*: Infarct left posterior temporal and parietal areas (Fig. 24-6).
2. *Angiograms*: Occlusion of the left internal carotid artery. All anterior and middle cerebral artery branches filled from the right carotid. An artery to artery embolus was presumed.

The following case 24-7 would suggest this type of unilateral lesion producing a transient and partial but selective type of dyslexia.

Case 24-7: Seven days prior to admission, following a period of athletic activity, this 15-year-old, right-handed white male high school student had the onset of a 48-hour period of sharp pain in the left jaw and the supraorbital area. The next day the patient began to complain of blurring of vision and the following day had the onset of vomiting. Four days prior to admission, the patient noted that he was unable to read and to translate his Latin lessons. No definite aphasia was apparent. Two days prior to admission, the patient had the sudden onset of severe left facial pain, accompanied by tingling paresthesias of the right leg. The patient became stuporous and then unresponsive for approximately 90 minutes. An examination of spinal fluid at that time revealed pressure elevated to 290 mm of csf with 250 fresh blood cells.

Neurological examination:

1. *Mental status*: All aspects, including language function were intact.
2. *Cranial nerves*:
 - a. Examination of the fundus showed several small flame shaped hemorrhages. Visual fields were intact.
 - b. A slight, right, supranuclear-type (central) facial weakness was present.
3. *Motor system*: Intact
4. *Reflexes*: Deep tendon reflexes and superficial reflexes were symmetrical and physiologic.
5. *Sensory system*: Primary and cortical modalities were intact.
6. *Neck*: A slight degree of resistance was present on flexion of the neck (nuchal rigidity) consistent with the presence of blood in the subarachnoid space.

Clinical diagnosis: Subarachnoid hemorrhage of uncertain etiology. In view of age and the transient dyslexia, and the transient paresthesias of the right leg, an arteriovenous malformation in the left parasagittal parietal-occipital area might be suspected.

Laboratory data:

Arteriograms: An arteriovenous malformation was present in the left occipital region. The main arterial supply was the posterior temporal branch of the left posterior cerebral artery. The malformation drained into the lateral sinus. The posterior portion of the anterior cerebral artery was shifted across the midline, indicating a hematoma as well as the malformation.

Subsequent course: On that evening after his admission, the patient had the sudden onset of a bifrontal headache. For a 2- to 3-minute period, the patient was unconscious with deviation (repetitive driving) of both eyes to the right, and with sweating and slowing of the pulse rate. Over the next two days an increase in blurring of the optic disc margins was noted (early papilledema). Four days after admission, the patient suddenly complained of being unable to see from his right eye. He became restless and agitated. Additional headache and neck pain with numbness of right arm and leg were reported. Examination now disclosed a dense right visual field defect (homonymous hemianopsia). The deep tendon reflexes were now slightly more active on the right. Funduscopy suggested that

recent additional subarachnoid bleeding had occurred since new retinal hemorrhages were present. The next day (five days after admission), the patient was noted to have a significant reading disability (dyslexia), although other language functions were intact.

Because of the progressive evolution of neurological findings due to an expanding intracerebral hematoma, Doctor Robert Yuan performed a craniotomy. Blood was present in the subarachnoid space. The left lateral occipital cortical surface had numerous areas of bluish discoloration indicating an intracerebral clot. The main arterial vessel was a lateral and inferior branch of the posterior cerebral artery, bearing no relationship to the calcarine region. The draining vein was located in the occipital-temporal area, close to the tentorium. At a depth of 1 cm, a hematoma of 50 cc of clot was found. The clot extended down to the occipital horn of the lateral ventricle but did not enter the ventricle. The malformation, hematoma and related cerebral tissue of the lateral occipital area were removed. The calcarine area remained intact at the end of the procedure. Over a period of several days, the visual field deficits disappeared.

Detailed language and psychological testing approximately two weeks after surgery indicated that language function was intact except for reading. Oral reading was very slow (4 times slower than normal for a test paragraph), halting and stumbling. Comprehension of the material read was good. Minor errors were made in the visual recognition of letters. This was reflected in occasional errors in spelling. Visual recognition and naming of objects was intact. Auditory and tactile recognition of sounds, words, letters, sentences, questions, commands and so forth was intact. Calculations were intact. No right-left confusion or finger agnosia was present. Writing and drawing were intact but slow. Repetition of speech and spontaneous speech were intact.

Follow-up evaluation at 20 and 30 months indicated that, although the patient was doing well in school, receiving A's and B's with excellent grades in mathematics, he still was described as slow in reading compared to his level prior to illness. No actual errors were made in reading when this was tested.

Comment: The arteriovenous malformation in this case had involved and eventually required surgical removal of the lateral occipital area of the dominant hemisphere. The hematoma in the occipital lobe extending in from the lateral surface to the occipital horn was so located as to compress the optic radiation passing to the calcarine cortex or perhaps even to indirectly compress the calcarine cortex. Such a hematoma would also interfere with association fibers passing from left occipital areas to temporal parietal areas and with callosal radiation fibers passing from the occipital region (area 18) of the right hemisphere to the occipital and parietal areas of the dominant hemisphere. Following surgery, the patient had a relatively good recovery with the minor difficulties in reading; (a selective dyslexia) as perhaps the only indication of any damage to these fiber systems.

The complaint of the patient at the time that the right homonymous hemianopsia appeared was of blindness in the right eye. It is not uncommon for patients to localize field defects in this manner to the eye of the same side. The same may sometimes be true of patients with discharging lesions in the occipital area; the flashing lights and lines may be localized to the contralateral eye rather than to the contralateral visual field.

The episode on the night of admission is of interest because it suggests a focal adverse seizure, in this case presumably originating from areas 18 and 19 of the left hemisphere.

Geschwind (1965) has reviewed many of the previously reported cases of selective dyslexia. It is uncertain whether the information from area 18 of the non-dominant hemisphere passes to the non-dominant angular gyrus and then crosses to the dominant temporal parietal areas or whether these fibers pass instead directly to area 18 of the dominant hemisphere with information then conveyed to the dominant temporal parietal areas. He finally concludes that both pathways are probably operative. The relatively minor nature of the final residual deficit in the present case would be consistent with such multiple pathways. In addition, non-fatal hemorrhages always produce less damage than infarcts of comparable size. Finally, Coslett (2000) has reviewed various recovered pure cases of dyslexia where the right hemisphere may have played a role in reading. Such patients do better with concrete nouns than abstract nouns, verbs and functors (pronouns, prepositions, conjunctions and interrogatives). It should be noted that a relatively selective dyslexia in the absence of a severe general visual agnosia might occur. Geschwind has suggested that whether a general visual agnosia or dyslexia occurs may depend on the degree of disconnection of the dominant speech areas from the parietal and occipital areas of the non-dominant hemisphere. In the patient who already has left occipital cortex damage, dyslexia may require only damage to the splenium of the corpus callosum, whereas visual agnosia may require more extensive damage to the posterior body of the corpus callosum as well. As noted bilateral

visual association lesions (areas 18 and 19) would also produce a visual agnosia. (See also Coslett and Saffran 1989 and Friedman and Albert 1985).

In addition there are patients who have acquired dyslexia which is unrelated to the processing of the visual information input. These patients have a central (rather than the peripheral dyslexia of the pure alexia syndrome discussed above). The central dyslexic patient has an impairment of the “deeper” or “higher” reading functions by which visual word forms mediate access to meaning or speech production mechanisms. This problem is reviewed in detail by Coslett (2000).

Feinberg and Farah (2000) review the general topic of agnosias.

CHAPTER 26: VASCULAR SYNDROMES OF THE CEREBRAL HEMISPHERES

The following case history presents a young adult with severe carotid stenosis and infarction of the territories of both the anterior and middle cerebral arteries.

Case 26-1: This 23 year old right handed female on birth control pills, smoking one pack of cigarettes per day, on June 15, 1985 shortly after intranasal “snorting” of cocaine complained of gradually increasing right sided headache and then fell to the floor with a flaccid left hemiplegia with the head and eyes deviated to the right **Neurological examination:**

1. *Mental status:* The patient denied any illness and could not explain why she was in the hospital.
2. *Cranial nerves:* There was a left homonymous hemianopsia, deviation of head and eyes to the left and a left central facial weakness.
3. *Motor system:* A flaccid left hemiparesis was present.
4. *Reflexes:* deep tendon reflexes were initially depressed on the left side. Plantar responses were extensor bilaterally.
5. *Sensory system* a severe left hemisensory deficit, with a neglect of the left side of space and body was present.

Clinical diagnosis: Total right middle cerebral artery territory infarct.

Laboratory data:

1. *Initial CT Scan* demonstrated hypodensity (infarction in right frontal and parietal areas).
2. *Right carotid angiogram* demonstrated severe stenosis of the supraclinoid segment of the right internal carotid artery with severe stenosis of the M-1 segment of the right middle cerebral artery and multiple areas of narrowing of the remainder of the right MCA. *Left carotid angiogram* indicated only limited cross filling of the distal right middle and anterior cerebral arteries.

Subsequent course: On 6-21-85, 6 days after admission the previously alert patient suddenly developed a decreased level of consciousness and a fixed, dilated right pupil suggesting that tentorial herniation had been produced by severe edema or hemorrhagic transformation of the infarct. CT Scan now demonstrated massive infarction and edema-right anterior and middle cerebral artery territories plus-transtentorial and sub falx herniation (Fig.26-6). With emergency management of the increased intracranial pressure-(monitor and osmotic agents) the patient became more alert and was transferred to a rehabilitation facility.

Comment: This young woman had as a major risk factor, the intranasal snorting of cocaine. The vasospasm induced by this agent was sufficient to produce severe stenosis of the internal carotid and the initial segment of the middle cerebral artery. The multiple areas of narrowing seen in the branches of the MCA may well have represented emboli from these more proximal sources. Whether the severe stenosis of the M1 portion also involved an embolic event from the siphon remains unclear. It is clear that the severe stenosis of the carotid artery produced infarction of both the MCA and ACA territories. In this case there was insufficient cross flow from the left carotid supply to prevent infarction. As we will see in case 26-3 massive infarcts of the MCA territory plus or minus adjacent territories constitute a serious threat to life due to massive edema and or hemorrhagic infarction with the risk of herniation. The use of cocaine and of crack cocaine may be associated coronary or cerebral artery vasospasm. In addition to cerebral infarcts, cerebral hemorrhage may also occur, particularly with crack cocaine.

The following case history concerns a patient with severe stenosis at the carotid bifurcation producing both retinal and hemispheric TIA's.

Case 26-2: This 54-year-old, right-handed, white male had experienced intermittent episodes of blurring and blacking out of vision in the left eye for at least 7 years. Each episode would last 30 to 60 seconds and would occur twice per month. Ten days prior to admission, the patient had the onset of numbness of the right side of the face accompanied by minor weakness of the right face, arm, and leg. There was also a transient difficulty

in speech (possibly dysarthria, possibly difficulty in word finding). Symptoms cleared completely in 45 to 60 minutes with the exception of residual numbness of the right side of the face.

Family history: The patient's mother died of a "stroke" at age 66 years, and his father, of heart disease at age 57.

General physical examination:

- (1) Blood pressure was slightly increased to 160/100 in both arms. Pulse rate and rhythm were normal
- (2) Bruits (murmurs) were present over each carotid artery, but the heart was normal with no murmurs.
- (3) The retinal artery pulsation was easily obliterated by pressure on the globe of the left eye. No significant changes occurred on compression of the right globe.
- (4) Peripheral pulses were poor in the lower extremities.

Neurological examination: Mental status, language function, cranial nerves, motor system, reflexes, and sensory system were all normal except for a minor right central facial weakness.

Clinical diagnosis: Carotid stenosis with retinal and hemispheric TIA's.

Laboratory data:

1. Hemoglobin, serological tests for syphilis, skull and chest x-rays, electroencephalogram, and brain scan were all normal. Cholesterol was elevated to 284 mg%.

2. *Arteriography (aortic arch study)* demonstrated a complete occlusion at the origin of the left internal carotid artery. A right brachial arteriogram demonstrated filling of the left anterior and middle cerebral arteries by cross flow through the anterior communicating artery from the right side. Additional studies also demonstrated filling of the intracranial portion of the left internal carotid artery from the left posterior communicating artery.

Subsequent course: Ten days after that hospital admission, a left carotid endarterectomy was performed by Dr. Allan Callow with a restoration of blood flow following removal of the occlusive lesion (atherosclerosis with recent thrombosis) at the carotid bifurcation.

Comment: The location of disease in the left carotid artery was clearly indicated by the episodes of left eye visual disturbances followed by symptoms on the contralateral side of the body. The development of symptoms in the face, with disturbance of speech is consistent with total occlusion of the carotid artery, with greater involvement of the middle cerebral territory than of the anterior cerebral territory. The fact that this patient, with progressive stenosis of the carotid artery, had symptoms for many years only in the ophthalmic-retinal artery distribution, is explained by the excellent collateral flow into the anterior and middle cerebral arteries from the anterior communicating bypass. In addition collateral flow would enter the common carotid artery from the posterior communicating artery above the take off of the ophthalmic artery.

It should be apparent that the final complex of neurological symptoms and signs, occurring with occlusion of the carotid artery, will depend on the total pattern of cerebral blood flow in the individual patient. In many patients total occlusion of the carotid artery will produce an infarction of that portion of the cerebral hemisphere supplied by the carotid artery (primarily the middle cerebral territory). In others, a benign outcome is the result (Bornstein and Norris, 1989). With the development of imaging techniques such as CT and MRI scan - has come the recognition that small silent infarcts may occur in patients with non symptomatic stenosis of the carotid artery (Norris and Zhu, 1992).

In this case, the occurrence of symptoms in the right side of the face plus the difficulty in speech might raise the question of a possible embolus to a branch of the MCA from the thrombus at the bifurcation. A perfusion deficit would have produced problems primarily in the border zone (the area of the arm).

In this particular case, earlier evaluation of the patient might well have resulted in a demonstration of occlusive disease of the extracranial portion of the carotid artery

prior to total occlusion. For such patients surgical therapy is feasible. To restore blood flow 20 days after occlusion as in this case is unusual.

A question which remains unanswered in this case is whether this patient would have proceeded eventually to a completed lasting hemiparesis. Kase et al (1991) have summarized the various studies. The rate of completion of the stroke over a 40 month period varied from 2% (Marshall, 1964) to 51%.

The following case demonstrates a case in which the patient began with carotid TIA's progressed to a carotid border zone syndrome of infarction and then involved additionally all of the middle cerebral artery territory.

Case 26-3 (Pt. of Dr. Thomas Mullins): This 72-year old right-handed white male was admitted for evaluation of two episodes of right upper extremity weakness, each of two hours duration, beginning 2 days prior to admission. Following the first episode, the patient had persistent left-right disorientation, a deterioration in writing (dysgraphia), could not understand what he had read and had transient slurring of speech.

Neurological examination:

1. *Mental status and language function:* Intact for alertness and orientation. Language was fluent with intact repetition, and object naming; however, reading comprehension, writing, and left-right orientation were all impaired.
2. Cranial nerves: Intact.
3. Motor system, reflexes and sensory system were all entirely intact.
4. *Carotids:* A bruit was present on the left.

Clinical diagnosis: Carotid artery stenosis with TIA's reflecting decreased perfusion in the border zone followed by thrombosis and passage of emboli to the inferior division of the middle cerebral artery.

Laboratory Data:

1. CT scan and EKG were normal
2. An *arteriogram* performed on the day following admission demonstrated the following:
 - (a) The left internal carotid artery was completely occluded just above the bifurcation (Fig. 26-7A).
 - (b) The left external carotid artery did fill the left internal carotid artery at the siphon through anastomosis about the orbit (Fig. 26-7B). However, there was a cutoff just below the siphon suggesting that the thrombus (clot) at the bifurcation had extended to this level. Moreover, the left middle and anterior cerebral arteries failed to fill in this manner.
 - (c) The left posterior cerebral artery did originate from this segment of the otherwise occluded carotid siphon segment but with no retrograde filling into the basilar artery (Fig. 26-7B).
- 4) The right carotid artery filled not only the right middle cerebral and anterior cerebral artery but also was the source of the right posterior cerebral artery (Fig. 26-7C).
- 5) The right carotid system also supplied the left anterior cerebral artery and to a limited extent the left middle cerebral artery (Fig. 26-7D).

Subsequent course: On the day following admission, weakness in the right hand at wrist and finger extensors recurred. During the arteriogram, the patient was noted to have additional problems with speech. Weakness in the right upper extremity increased. Despite subsequent anticoagulation, additional progression occurred with total paralysis of the right upper extremity, aphasia and a right homonymous hemianopsia. A *repeat CT scan*, 72 hours after these events, demonstrated acute infarction with severe edema involving the entire cortical and deep territory of the middle cerebral artery and the cortical territory of the posterior cerebral artery but with relative sparing of the anterior cerebral artery territory and of the thalamic territory of the posterior cerebral artery (Fig. 26-8). Coma developed secondary to the herniation effects on the brainstem and the patient expired 8 days after admission.

Comment: This patient clearly had hemispheric carotid border zone TIA's followed by persistent symptoms that suggested involvement of the inferior division of the middle cerebral artery to the inferior parietal lobule. These latter persistent symptoms may well have been embolic from the thrombus at the level of the carotid bifurcation. There then was progression of the border zone findings

followed by involvement of the entire middle cerebral artery territory and of the cortical territory of the posterior cerebral artery. The end result was a massive cerebral infarct with considerable swelling. Such massive swelling with herniation of temporal lobe through tentorium and secondary brainstem compression is the major cause of acute death in patients dying after acute carotid artery or massive middle cerebral artery infarctions (31%). Other causes of death are pneumonia (29%), cardiac arrest (17%), pulmonary embolus (13%) (Bounds et al 1981).

Not all patients with acute carotid infarcts continue to progress. In the series of Jones and Milliken (1976), 39% of patients remained stable. Thirty-five percent had gradual improvement and 19% had a progressing deficit over 48 hours.

The following case history illustrates such an occlusion with massive infarction of the entire territory of the middle cerebral artery.

Case 26-4: This 61-year-old, right-handed black housewife one week prior to admission, suddenly fell to the floor while taking a bath and lost consciousness. She was picked up off the floor by her son who found that she was unable to move her left arm and leg. She was unable to walk and had regained no function in these extremities. Her speech had been thick, but no aphasia had been present. No headache had been noted.

Past history: Hypertension had been present for three years. Five days prior to admission, she had been switched to a new antihypertensive medication. There was no history of heart disease. Both parents had died of heart disease and hypertension.

General physical examination: Blood pressure was 150/100, pulse was regular at 84. Blood pressure was 150/100, the pulse was 84 and regular.

Neurological examination:

1. *Mental status:* The patient was obtunded and slow to respond. However, she was grossly oriented to time, place, and person.

2. *Cranial nerves:*

- a. The head and eyes were deviated to the right. The patient could not move the eyes to the left on command. However, on vestibular stimulation, the eyes could be moved to the left.
- b. The patient neglected stimuli in the left visual field. The pupils did respond to light.
- c. Papilledema was present bilaterally particularly in the right fundus where a recent hemorrhage was present.
- d. There was a decrease in pain sensation or a neglect of painful stimuli on the left side of the face.
- e. A marked left central facial weakness was present.

3. *Motor system:* A complete flaccid paralysis of the left arm and leg was present. The patient was unable to sit up without support.

4. *Reflexes:* Deep tendon reflexes were increased on the left compared to the right. The left plantar response was extensor.

5. *Sensory system:* All modalities of sensation were decreased on the left side of the body.

Clinical diagnosis: Acute occlusion of the stem of the middle cerebral artery, possibly embolic, although primary occlusions of intracranial arteries may occur in the non-Caucasian population. Hypertensive intracerebral hemorrhage was a less likely possibility.

Laboratory data:

1. *Chest and skull x-rays* were negative but the *electrocardiogram* showed left ventricular hypertrophy.
2. *Electroencephalogram* indicated focal damage throughout the right hemisphere—most prominent in the right frontal area, (focal 3 to 5 Hz slow waves). In addition there was a relative absence of electrical activity in the right temporal area (Fig. 2-23) consistent with a severe degree of destruction of this area.
3. Brain scan 3 days after admission showed a significant but diffuse uptake of isotope (Hg^{197}) in the right hemisphere. A repeat brain scan on 9 days after admission showed a more marked uptake measuring 11x6x6 cm., extending from the right frontal area to the posterior parietal area. Uptake extended from the surface to the deep midline (Fig. 26-14).
4. Cerebrospinal fluid contained no significant cells. Protein was moderately increased to 57 mg./100 ml. Pressure at the lumbar area was 150 mm. of csf.
6. Right brachial arteriogram revealed a complete occlusion of the right middle cerebral artery at its origin (Fig. 26-15).

Hospital course: The patient showed no significant improvement during a four week hospital course.

Comment: The patient had a sudden occlusion of the right middle cerebral artery with massive infarction of the entire area of the right hemisphere supplied by the middle cerebral artery. Such massive infarctions are often, as in this case, associated with a significant degree of cerebral edema with the development of papilledema. At times the degree of swelling of the cerebral hemisphere may be sufficient to displace the pineal or the anterior cerebral artery. It is also possible in this case that the infarct was secondarily hemorrhagic. In many cases of hemorrhagic infarction the spinal fluid does not contain red blood cells.

The equal involvement of face, arm, and leg was consistent with the involvement of the penetrating branches of the middle cerebral artery with resultant infarction in the posterior limb of the internal capsule. The deviation of head and eyes to the right indicates destruction of area 8 of the right hemisphere or of the fibers descending from this area, through the corona radiata. Involvement of the cortex in addition to this the internal capsule is also indicated by the findings on the brain scan and electroencephalogram and by the neglect of visual and tactile stimuli on the left side. As regards the etiology, an embolus to the middle cerebral artery is the most likely etiology although in a non-Caucasian patient, primary occlusion could not be ruled out. Today this patient would probably have been treated with t-PA presuming that she had arrived at an emergency room capable of administration of this agent within 3 hours of onset of symptoms and did not have contraindications in terms of preexisting conditions or of CT scan findings (hemorrhage or massive infarction -refer to Brott & Boguslavsky, 2000) .

Prognosis for survival during the acute state of the first week depends on the degree of edema patients with massive middle cerebral artery territory infarcts due to MCA occlusion who already had early CT scan evidence of brain swelling within 24 hours of the ictus. Fifty five percent of these patients expired ,overwhelmingly of herniation effects. Patients older than 45 years had a poorer prognosis than younger patients. Infection of the lungs is a serious complication of large infarcts and a major cause of death during the second week. If the patient survives ,prognosis for recovery is related to the size of infarct. Less than 3 cm. infarcts may be associated with a good recovery ; greater than 3 cm. with severe disability (Olson ,1991). This patient had already survived for one week prior to reaching the neurologic center. Although she continued to survive, her prognosis for recovery remained poor.

The following case history illustrates many aspects of ischemia within the cortical distribution of the posterior cerebral artery. This patient demonstrates the general rule that posterior cerebral cortical infarcts are usually embolic.

Case 26-5: This 55 year old ambidextrous married white female research coordinator at approximately 11:30 AM on the day of admission suddenly developed blurring of vision possibly all over her field of vision, possibly in her left visual field, possibly in her left eye. A coworker checked her vision, and found that she had a left visual field defect. Shortly thereafter, she developed tingling paresthesias of the left face arm and leg.

Past history: Hypertension treated with hydrochlorothiazide and Lasix.

Physical examination: Blood pressure was elevated to 160/70. Weight was elevated to 264 pounds .A small ecchymosis was present under the toenail of the left second digit.

Neurological examination,(3hours after onset):

1.Mental status: Intact .

2.*Cranial nerves:* A non-congruous left homonymous hemianopsia was presented greater in the left temporal field than the right nasal field.

3.Motor system: Intact.

4.*Reflexes:* Deep tendon stretch reflexes were decreased in the lower extremities (patella,1+ and Achilles,0). Plantar responses were equivocal ,with the left probably extensor.

5.*Sensory system:* There was decreased pain and errors were made in graphesthesia over the left foot.

6.*Vascular:* There were no bruits over the carotids and subclavian areas and the blood pressures in the two arms were equal.

Clinical diagnosis: Posterior cerebral artery ischemia and possible infarct, probably embolic, involving the right calcarine cortex and thalamus or a lacunar event involving the right thalamus.

Laboratory data:

1. Duplex scans of the carotid and vertebral arteries and CT scan of the head on the day of the event were normal. RPR, ESR, TSH, proteins C, S, antithrombin 3 and all anticardiolipin antibodies were normal.
2. *MRI*, 4 days after onset (Fig.26-18) :small area of increased signal in the right occipital lobe in region of the visual cortex consistent with an infarct in distribution of the calcarine artery.
3. *MRA* (Fig.26-19): decreased flow in the distal right posterior cerebral artery probable embolic occlusion with filling of distal branches by anastomotic flow.
4. *Holter monitoring* demonstrated multiple brief episodes of paroxysmal atrial fibrillation.
5. The routine *transthoracic echocardiogram* demonstrated no clear cut abnormalities. However the *transesophageal echocardiogram* demonstrated a definite patent foramen ovale with right to left shunting.

Subsequent course: Reevaluation of the patient 22 hours after the onset of symptoms demonstrated clearing of all neurologic findings. When seen 2 weeks after the event her only complaint related to some problems in reading. This patient already been receiving aspirin at the time of the event and this was discontinued. She was begun on lifelong systemic anticoagulation with coumadin by the consultant cardiologist Dr. Filiberti since she had two conditions associated with embolization: paroxysmal atrial fibrillation and patent foramen ovale with right to left shunting. The patient did well over the subsequent 5 years.

Comment: When initially evaluated, the posterior cerebral artery location was clear but the pathophysiology was not. The subsequent imaging studies clearly indicated a small infarct involving the calcarine artery territory. Whether the previous sensory findings indicated some involvement of the posterior cerebral penetrating supply to the ventral posterior lateral nucleus of the thalamus remains unclear. The decreased flow in the right posterior cerebral artery was clearly demonstrated. In general as with the middle cerebral artery, cortical infarcts of the posterior cerebral artery territory, in the Caucasian population are almost always embolic. In this case the patient had two possible sources for emboli and was placed on long term anticoagulation.

The following case 26-6 presented at the onset with a transient bilateral posterior cerebral ischemia but with more severe residual symptoms reflecting unilateral posterior cerebral disease.

Case 26-6. This 75-year-old, white, right-handed widow developed sudden headache on the day prior to admission, with nausea, vomiting, and a poorly described bilateral disturbance of vision. She was found by a relative the morning of admission complaining of total blindness and of severe headache. She was noted to be confused and incoherent (believed she was in New Jersey rather than Massachusetts). She was able to walk only with assistance.

Past history: A minor degree of hypertension had been noted several days prior to admission.

Physical examination: The patient was an obese female with blood pressure elevated to 170/100. She was holding her head complaining of headache.

Neurological examination:

1. Mental status:
 - a. The patient was restless and disoriented for time and place.
 - b. There were difficulties in cooperation so that detailed testing of mental status could not be performed.
 - c. Simple calculations were poorly performed.
 - d. Digit span was markedly limited.
 - e. There was no left-right confusion and no evidence of aphasia.
2. Cranial nerves:
 - a. Initially the patient was unable to detect objects (e.g., a face or lights) in either visual field. Within six hours, a change had occurred. Although conjugate extraocular movements were full, the patient tended to keep her eye deviated to the right and failed to follow objects introduced from the periphery of the left visual field. The eyes could be deviated to the left on command.
 - b. The pupils responded to light.
3. Motor system:
 - a. Strength was grossly intact.

- b. A slight unsteadiness (ataxia) of gait was present.
- 4. Reflexes:
 - a. Deep tendon reflexes were grossly symmetrical.
 - b. A Babinski response was present on the left; a probable Babinski sign was also present on the right.
- 5. *Sensory system*: All modalities were intact.

Clinical diagnosis: Ischemia bilateral posterior cerebral arteries, cortical branches, probably embolic.

Laboratory data:

1. *Hematocrit* was normal. *Total cholesterol* was elevated to 312 mg./100 ml. The *glucose tolerance test* was consistent with diabetes mellitus.
2. Chest and skull x-rays and the electrocardiogram were normal.
3. The *electroencephalogram* demonstrated focal 3 to 4 cps slow waves in the right posterior parietal occipital area with rare slow waves in the right posterior temporal area consistent with focal damage in this area.
4. *Lumbar puncture* indicated clear spinal fluid with no cells and a normal protein of 18 mg./ml.

Hospital course: The patient had a significant improvement in headache and a clearing of confusion with a return of mental status to her normal level. Her hospital stay was prolonged by the development of thrombophlebitis of the left femoral vein. At the time of hospital discharge, one month after admission, there was still a residual left field defect (homonymous hemianopsia) with preservation of vision in the macular area (macular sparing). Follow-up evaluation approximately 14 months after discharge indicated no significant neurological findings except for the residual left field defect (homonymous hemianopsia with macular sparing) (Fig. 23-16).

Comment: The initial symptom of total blindness suggested bilateral posterior cerebral ischemia. The development of confusion and disorientation is also consistent with bilateral posterior cerebral ischemia. The nausea, vomiting, and minor ataxia of gait may well have indicated ischemia of the brain stem, suggesting that the basic occlusive process may have originated at a lower point in the basilar artery. The residual and most severe degree of involvement was certainly within the territory of the right calcarine artery.

The occurrence of severe headache is not usually considered in connection with ischemic-occlusive disease. A review of our cases of posterior cerebral occlusion indicates that the occurrence of severe headache is often a prominent symptom. Often in these cases prior to lumbar puncture, the diagnosis of subarachnoid hemorrhage was considered.

At the present time evaluation would include a CT or MRI scan. Other examples of posterior cerebral artery cortical infarcts are presented in the visual system chapter with appropriate CT scans.

The following case 26-7 provides an example of an intracerebral hematoma of unknown etiology in a young patient.

Case History 26-7. This 33-year-old white, right-handed, male linotype operator, at approximately 8:30 p.m. had the sudden onset of numbness of the left side of his mouth. At 10:30 p.m. he developed a severe right frontal headache and noted sudden onset of numbness of the left upper extremity which rapidly spread to involve the entire left side. Marked weakness of the left arm and leg developed. Evaluation that evening at his local community hospital indicated a dense left homonymous hemianopia, a marked left central facial weakness, an absence of any voluntary movement of the left arm and leg and no awareness of painful stimulation of the entire left side. A left Babinski sign was present. Lumbar puncture revealed opening pressure elevated to 235 mm. of water; and 50 fresh red blood cells per cubic mm. The patient was subsequently transferred to the neurosurgical service at New England Center Hospital.

Past history: There were no remarkable features as regards hypertension, renal disease, or diabetes mellitus. No history of drug use was obtained.

Physical examination: The patient was moderately obese with a normal blood pressure of 110/85. Examination of the heart revealed no abnormalities. No rigidity of the neck was present. There were no murmurs over the cranium.

Neurological examination:

1. **Mental status:** Orientation, speech and the ability to provide a coherent history were all intact.
 2. **Cranial nerves:**
 - a. Examination of the fundi showed no hemorrhage or papilledema.
 - b. A dense left homonymous hemianopsia was present.
 - c. Sensation was defective on the left side of the face, as well as the left side of the body.
 - d. A left central facial weakness was present.
 - e. The tongue deviated to the left.
 3. **Motor system:**
 - a. A dense flaccid paralysis of the left arm and leg was present.
 - b. There was no resistance to passive motion in the left arm and leg and little in the left lower extremity (that is, a flaccid paralysis was present).
 - c. Cerebellar tests were negative.
 4. **Reflexes:**
 - a. Deep tendon reflexes were absent in the left upper extremity but increased in the left lower extremity
 - b. A Babinski sign was present on the left. The plantar on the right was flexor.
 - c. No grasp reflexes were present.
 5. **Sensation:**
 - a. There was no perception of pinprick or of tactile stimulus on the entire left side of the body.
 - b. Position and vibratory sensation were absent on the on the left.
- Clinical diagnosis:** Intracerebral hematoma right putamen-thalamus or embolus stem of MCA with hemorrhagic transformation.

Laboratory data:

1. Hematocrit, white blood count, and differential were all within normal limits. Sedimentation rate was normal.
2. *Tests of bleeding time, clotting time, and prothrombin time* were all within normal limits.
4. *Skull x-rays* revealed a shift of the pineal, 7 mm. from right to left.
5. *Electroencephalogram* revealed frequent focal 4 to 5 cps slow waves in the right hemisphere most prominent in the frontal and parietal areas consistent with focal damage in these areas.
6. *Arteriograms* (right common carotid) revealed a 12 mm. shift of the pericallosal branch of the anterior cerebral artery. The internal cerebral vein was also shifted 8 mm. from right to left. The middle cerebral branches emerging through the sylvian fissure were depressed. There was no evidence of an abnormal arteriovenous shunt or of an aneurysm. Cortical vessels and veins in the suprasylvian area were stretched over relatively avascular areas. The conclusion was a space-occupying mass in the right posterior frontal parietal area consistent with an intracerebral hematoma.

Subsequent course:

On the day of admission, the patient was taken to the operating room. A right parietal burr hole was made. The underlying cortex was noted by the neurosurgeon, Dr. Robert Yuan, to bulge prominently. A needle was inserted to a depth of 1 cm. into the cortex where 25 cc. of old, dark red blood under pressure was expelled. Free drainage of blood continued through a catheter which remained in place for 2 days.

Return of voluntary movement in the left lower extremity at the hip and knee was noted on the day following surgery. Reevaluation of neurological status 2 weeks after surgery, revealed continued improvement. The left homonymous hemianopsia was no longer present but the patient did have some difficulty in reading (losing the left half of the line of print). A left central facial weakness was present; voluntary hand-foot movements on the left were still not possible. Proximal muscle groups (shoulder, hip, knee) had returned to 60 per cent of normal strength. Deep tendon reflexes were now hyperactive in the upper and lower left extremities with a left Babinski sign. A dense

sensory deficit remained on the left side with no perception of pain, touch, vibration, and position in the upper and lower extremities. Reevaluation 4 weeks after surgery, revealed a return of pain and temperature sensation but continued deficits in proprioception. Reevaluation by Dr. Yuan 4 months after surgery, indicated a return of strength in the left hand with a strong grip. The gait was typical of a spastic hemiplegia. Reflexes were unchanged. Sensory examination revealed a return of primary modalities such as vibration and pain, but marked errors in cortical modalities, such as position sense, were made. Follow-up 7 months after surgery indicated an excellent return of strength on the left side but continued incoordination in the left hand due to deficits in proprioception.

Comment:

This patient from several standpoints presents a number of unusual features not seen in the typical case of intracerebral hemorrhage. The patient was relatively young (33 years old) and had no history of hypertension. He had none of those conditions such as leukemia, bleeding disorders, and the like which predispose to intracerebral hemorrhage. The arteriogram provided no evidence of an intrinsic or a secondary metastatic brain tumor. Moreover, histological examination of the tissue and drainage material obtained at the time of surgery failed to reveal tumor cells. No aneurysm was demonstrated on angiography. Although no arteriovenous malformation was demonstrated at the time of arteriography, such a malformation may have been present previously but destroyed in the process of hemorrhage. The significance of the minor prodromal sensation of numbness of the face remains uncertain. This may have reflected an initial small area of ischemia with secondary hemorrhage.

Where was the initial site of hemorrhage? In this case, the hemorrhage apparently originated in the subcortical white matter of the parietal lobe presenting as a lobar hemorrhage. The pattern of initial evolution of symptoms and the final pattern of sensory deficit is perhaps more consistent with such a parietal lobe location. From the prognostic standpoint, he did not lapse into coma and did not have compromise of brain stem functions as so often occurs when there is tentorial herniation or an extension of the hemorrhage into the ventricular system. That these various events did not occur, may in part relate to the drainage of the hematoma by the neurosurgeon with removal of this supratentorial mass lesion. The management of intracerebral hemorrhages is discussed in greater detail by Ojemann and Heros, (1983).

The following three cases provide examples of subarachnoid hemorrhage from aneurysms at the three major sites: posterior communicating-internal carotid (Case 26-8), middle cerebral bifurcation (Case 26-9) and anterior communicating –anterior cerebral junction (Case 26-10)

Posterior communicating- internal carotid junction.(Figs. 26-24)

Case 26-8: This 66-year-old white housewife, five days prior to admission, had the sudden onset of a severe bicipital bifrontal headache associated with vomiting. The headache was constantly present for 3 days but was increased by coughing. At the same time, she noted an alteration of vision in the right eye. She noted also a drooping of the right eyelid. The headache subsided, only to recur one night prior to admission as a severe occipital headache associated with vomiting. There was no past history of hypertension. The patient was admitted to her community hospital. A lumbar puncture revealed the presence of subarachnoid blood and the patient was transferred to the neurology/neurosurgical services of the New England Medical Center on 10/2/66.

General physical examination: The patient was an obese female with blood pressure of 140/80 and complaints of severe headache. Her temperature was normal.

Neurological examination:

1. *Mental status:* The patient was alert with mental status intact.
2. Cranial nerves:
 - a. Fundus: Blurred discs were present bilaterally, being greater on the right. No venous pulsations were present on the right.
 - b. Nerve III: The right pupil measured 4 mm. and was not reactive to light on direct or consensual stimulation.. The left pupil measured 2mm and was reactive to light. Ptosis of the right eyelid was present. At rest on forward gaze, there was outward deviation of the right eye. The patient was unable to adduct the right eye on left lateral gaze and failed to move this eye on upward or downward gaze. Other extraocular movements were intact.

c. Nerve VII: Minimal flattening of the right nasal labial fold was present.

3. *Motor system*: Strength, coordination, and gait were intact.
4. *Reflexes*: Deep tendon: A minimal relative increase was present on the right. Plantar responses: The left was flexor, the right was equivocal.
5. *Sensation*: All modalities were intact.
6. *Neck*: Mild nuchal rigidity was present (resistant to passive flexion of head onto chest).
Clinical diagnosis: Subarachnoid hemorrhage due to an aneurysm at the posterior communicating–internal carotid junction.

Laboratory data:

1. Skull and chest x-rays were normal.
2. Studies of bleeding time, clotting time, and prothrombin time were all within normal limits.
3. *Arteriograms* revealed an aneurysm of the right internal carotid artery just below its junction with the posterior communicating artery. There was no left-to-right flow through the anterior communicating artery. There was narrowing of the anterior cerebral arteries near their origin bilaterally. This suggested to the radiologist the possibility of vasospasm, secondary to the presence of subarachnoid blood.

Hospital course:

Because the history suggested several episodes of bleeding, surgical therapy was selected. A right temporal craniotomy was performed by Dr. Robert Yuan with clipping of the neck of the aneurysm. The temporal lobe was retracted revealing a 13 mm.-long saccular aneurysm, arising from the internal carotid artery close to the junction with the posterior communicating artery. Distally the aneurysm enlarged into a large sac which was hidden behind the oculomotor nerve. This nerve was bulging at the point where the aneurysm, which was clipped, was well formed. The more distal sac of the aneurysm was thin and showed signs of previous rupture with yellow staining of the adjacent meninges. The sac of the aneurysm was covered with Gelfoam. Postoperatively, significant deficits as compared to the preoperative neurological status were evident. The level of consciousness waxed and waned with periods of alertness alternating with periods of apathy and drowsiness. Twenty days after surgery, she was described as sitting with both eyes closed, continuously grasping and palpating the arm of the chair with the right hand, less frequently with the left. There was a marked bilateral release of an instinctive grasp reflex. There was increased resistance in both upper extremities, at times described as plastic rigidity, at times as the “Gegenhalten,” associated with bilateral frontal lobe disease. No spontaneous voluntary movements of the left leg occurred. Bilateral Babinski signs were present. A bilateral resting tremor of the hands and of the head was also present. At times inappropriate jocularity was present. All of these findings suggested a bilateral front lobe syndrome with infarction in the territory of the anterior cerebral arteries and additional involvement of the basal ganglia. The complete paralysis of the right third nerve remained at preoperative level. At the time of hospital discharge, one month after surgery, the frontal lobe findings and the weakness in the left leg remained prominent.

Comment:

The presence of severe headache in association with a mild degree of nuchal rigidity suggests meningeal irritation. Such irritation could indicate a subarachnoid hemorrhage or a meningitis (inflammation of the meninges due to bacterial or viral infection). The sudden onset of the headache is more consistent with a subarachnoid hemorrhage. The lack of fever and of accompanying or prodromal systemic findings is also against the diagnosis of meningitis. Finally, the clearly focal third nerve findings are more in favor of the diagnosis of subarachnoid hemorrhage (although focal or multifocal neurological findings may develop as complications of a bacterial meningitis).

In this case, the significant findings on neurological examination related to the right third cranial nerve. The third cranial nerve is particularly subject to compression by aneurysms of the posterior communicating artery because having emerged from the midbrain it pursues an anterior course towards the cavernous sinus in a close parallel relationship to the posterior communicating artery. In general, compressive lesions of the third nerve produce initially an alteration in pupillary constrictor functions, then involvement of the levator palpebrae and finally involvement of the superior, medial and inferior

rectus, and inferior oblique muscles. The initial alteration in vision in the right eye and ptosis of the right eyelid at the onset of headache are then consistent with a compressive lesion. The patient at the onset of symptoms did not report a diplopia.

The third nerve as it emerges from the midbrain also passes in close relationship to the posterior cerebral and superior cerebellar arteries, but aneurysms of these vessels are much less common than those which occur in relation to the posterior communicating artery and internal carotid artery.

These findings with extrinsic compressive disease of the third nerve are to be contrasted with the pattern of intrinsic brain stem involvement of the third nerve nucleus where medial rectus or superior rectus function is more likely to be initially compromised.

The patient had minimal findings suggesting involvement of the left corticospinal and corticobulbar tracts: minimal right central facial weakness, minimal increase in deep tendon reflexes on the right side, and an equivocal right plantar response. The findings may have been produced by a slight shift of the brain stem to the left due to the small mass of aneurysm on the right side of brain stem. With such a shift, compression of the left cerebral peduncle against the tentorium might occur. In any case, these findings were minimal. The significant findings in this case clearly related to the third cranial nerve and it is these findings which allowed localization of the lesion prior to arteriography.

As regards the postoperative course, it is evident that this patient had severe involvement of the frontal lobes presumably as a result of bilateral infarction within the territory of the anterior cerebral arteries. In retrospect, the narrowing of the anterior cerebral arteries at their origin, presumed secondary to "spasm" noted at the time of arteriography, may have provided a clue as to the development of the complication. The neurosurgeon, faced with the decision as to the best time to intervene, would prefer as the ideal situation, the moment when arterial spasm has not yet developed or is no longer present but bleeding has not yet recurred. In reality the risk of recurrent hemorrhage is so great that the aneurysm should be clipped as soon as possible for example the day of presentation. Vasospasm can now be treated with calcium channel blockers and after clipping by increasing the blood pressure to increase perfusion. The typical angiographic appearance of aneurysms in this location is demonstrated in Figure 26-24. Occasionally large aneurysms can be demonstrated on the CT scan.

Middle cerebral bifurcation (Fig 26-25).

Case 26-9: This 46-year-old, right-handed, white, married male, was admitted to the neurology/neurosurgical services of the New England Medical Center on 6/10/66. He presented a history that 10 days prior to admission, he had the sudden onset of a severe, throbbing, supraorbital and vertex headache. The headache began while the patient was in bed in the early stages of sexual intercourse. The patient noted no weakness except that his tongue "felt funny" in articulation for approximately one minute. There was a transient difficulty in speech during this period.

Past history: Mild hypertension had been present.

General physical examination: Blood pressure was 160/100.

Neurological examination:

1. *Mental status* was intact.
2. *Cranial nerves* were intact.
3. *Motor system* was intact.
4. *Reflexes* were physiologic
5. *Sensory system* was intact.
6. Headache could be precipitated by *head movement*.
7. With *cervical flexion*, pain occurred in the neck and lumbar area occurred.

Laboratory data:

1. Skull and chest x-rays were normal.
2. *Electroencephalogram* revealed focal damage in the lateral aspect of the left hemisphere (focal 3 to 5 cps slow waves).
3. *Lumbar puncture* on the day following admission revealed opening pressure elevated to 270 mm. of water and closing pressure to 210 mm. of csf. The fluid was xanthochromic (yellow discoloration). In addition 38 fresh red blood cells per cubic mm. were present. Protein was elevated to 80 mg./100 ml. Hinton was negative.

4. *Arteriography* revealed a bilobed aneurysm at the trifurcation of the left middle cerebral artery measuring 8 x 4 mm. Spasm and narrowing of the proximal anterior and middle cerebral arteries were noted.

Hospital course:

On the day following admission, the patient complained of a few-minute episodes of numbness in the right face, tongue, and right upper extremity with thickness of speech. Examination now revealed right central facial weakness and slight slurring of speech. The patient also now complained of additional neck pain on extreme forward flexion. On June 12, 1966, the patient had another short episode beginning with numbness over the right thumb, spreading to the right hand and then to the angle of the mouth.

Because of the several episodes which occurred, following hospital admission, involving the right face, tongue, and hand in association with the finding of fresh red blood cells in the spinal fluid, it was considered likely that bleeding from the aneurysm was continuing to occur. Surgical therapy was therefore considered necessary to prevent additional (and possibly fatal) subarachnoid hemorrhage. On May 20, 1966 a left frontotemporal craniotomy was performed by Dr. Robert Yuan with subsequent plastic coating of the entire aneurysm to reinforce its wall. There was evidence of recent hemorrhage in the subarachnoid space with yellow discoloration of the meninges. In order to expose the aneurysm, it was necessary to remove the anterior tip of the temporal lobe back to a distance of 2.5 cm. There was a small amount (5 to 10 cc.) of intracerebral blood clot in the superior temporal region close to the aneurysm. The aneurysm itself had no actual neck that could be clipped. Several middle cerebral branches appeared to arise from the dome or lateral wall of the aneurysm.

In the postoperative period, the patient initially did well. A minor expressive aphasia was present, but the patient was alert and well oriented. However, fever and jaundice developed. With the development of significant alterations of liver functions approximately 7 days after surgery, the patient became confused and agitated. The prothrombin time fell to 3 per cent of normal and there was evidence of bleeding into the gastrointestinal tract at this time. The prothrombin deficit was corrected by administration of vitamin K. It was unclear, however, as to whether any minor intracranial bleeding occurred during this time. Some improvement in liver functions occurred, and the patient became more alert but continued to manifest inappropriate behavior, emotional lability, and disturbance of memory. He left the hospital against medical advice one month after surgery, on July 20, 1966.

The patient was readmitted to the hospital approximately one month later on August 13, 1966. For two days, the patient had been less active, appeared confused, glassy eyed, and failed to communicate. The degree of obtundation cleared when adequate dosage of the anticonvulsant medication, Dilantin, was administered. This fact taken on conjunction with the electroencephalogram, which demonstrated frequent focal spikes (excessive neuronal discharge) in the left temporal area (Fig. 29-1C) led to the conclusion that the episode which precipitated his readmission might well have represented a prolonged seizure discharge. The electroencephalogram also demonstrated an increase in slow wave activity in the left hemisphere, particularly the left temporal area indicating a possible increase in damage in the left temporal area. This appeared to be correlated with apparent progression of the patient's aphasia which was now receptive as well as expressive in nature. At the time of discharge, a severe expressive aphasia was still present.

Comment:

The sudden onset of severe headache during exercise or exertion (sexual intercourse in this case) is characteristic of subarachnoid hemorrhage. The location of the aneurysm was suggested by the symptoms relevant to the tongue and speech during the initial episode. The episode on June 11, 1966, involving numbness of the right face, tongue, and right upper extremity, could only indicate disease within the territory of the left middle cerebral artery. The lumbar puncture at this time indicated not only evidence of the initial leakage of blood 10 days prior to admission (an elevation of cerebrospinal fluid protein and a xanthochromia), but also fresh red blood cells suggesting that additional leakage of blood had occurred.

The nature of the episodes which occurred on June 11 and 12 is not certain. Most likely these were ischemic in nature related to decrease in blood flow as a result of clot formation within the aneurysm or from spasm of the adjacent portion of the middle cerebral artery. At times, however, symptoms such as rapidly spreading numbness occurring in episodes may suggest focal epileptic discharge. The development of an area of excessive discharge would not be unusual since this aneurysm involves those

middle cerebral artery branches which are supplying the cerebral cortex. In addition hemorrhage within the Sylvian fissure is likely to damage the surrounding cerebral cortex. Blood and iron are epileptogenic.

The patient's course following surgery was complicated by the development of severe liver dysfunction. The etiology of this problem was never clear, the various studies suggesting either a toxic hepatitis related to various drugs and anesthetic agents or a variety of obstructive jaundice. What the patient's eventual recovery would have been had this problem not developed is uncertain. It is clear, however, that during this post-

operative period the patient did develop significant impairment of language functions, possibly related to infarction or oozing of blood in areas supplied by the middle cerebral artery. It is also evident that a seizure focus had developed in this area. Such seizure foci may have developed in relation to the preoperative hematoma noted in the temporal lobe, in relation to the surgical manipulation of the area, or in relation to the postoperative complications.

Today (2002), the history presented by this patient would have prompted an immediate CT scan and a lumbar puncture if the CT scan were negative. An arteriogram would have been performed immediately after these studies. Surgery would have been performed immediately after the evaluation of the angiographic studies to prevent the recurrent episodes of bleeding.

Anterior communicating -anterior cerebral junction(Figs. 24-26, 24-27, 24-28)

Case History 26-10. . (Patient of Dr. John Sullivan). This 49-year-old, right-handed truck driver was transferred from his local community hospital for evaluation of subarachnoid hemorrhage.

The patient had experienced occasional frontal headaches for the previous 5 years. In June, 1965, while changing a tire, he had a severe throbbing frontal headache which cleared after thirty minutes. Since that time he had experienced daily throbbing frontal headaches, usually present on arising in the morning. On September 4, 1965, the patient had the onset of a particularly severe headache which began while he was engaged in heavy work on a boat. There was associated stiffness of the neck, nausea, vomiting, and a general sensation of weakness.

Evaluation at his local community hospital revealed papilledema (blurred optic disk margins on funduscopic examination). Nuchal rigidity was present. The lumbar puncture demonstrated grossly bloody cerebrospinal fluid. He was subsequently transferred to the neurology/neurosurgical services of the New England Medical Center on 9/7/65.

Past history:

1. Hypertension had been noted in June, 1965.
2. The patient's father had died at age 59 of a cerebrovascular accident.

General physical examination:

1. Blood pressure was moderately elevated to 180/100. Pulse was 60.
2. No bruits (murmurs) were present over the skull.
3. A significant degree of nuchal rigidity was present. The neck could not be actively or passively flexed.

Neurological examination:

1. Mental status:
 - a. The patient was somnolent but could be aroused, although attention span was noted to be shortened.
 - b. He was oriented for place and situation but confused as to time.
 - c. Digit span was shortened to 5 forward and 4 in reverse.
 - d. The patient was unable to do calculations.
2. Cranial nerves:
 - a. Sense of smell was decreased on the right side.
 - b. Disk margins were indistinct on examination of the fundus. Arterioles were tortuous and irregular.
3. Motor system:
 - a. Strength and tone were intact.
 - b. Cerebellar tests were normal.
4. Reflexes:
 - a. Deep tendon reflexes were symmetrical.

- b. Plantar responses were flexor.
- 5. Sensory system: All modalities were intact.

Laboratory data:

1. Bleeding, clotting, and prothrombin times were all normal. Platelets were normal on smear.
2. Chest and skull x-rays were normal.
3. *Arteriograms* demonstrated an aneurysm of the anterior communicating artery which extended posteriorly and to the right. The aneurysm filled from the left carotid circulation.

Hospital course: During the evening of September 11, 1965, the patient became lethargic and would not speak or obey commands. Blood pressure rose to 240 mm. systolic. The patient became totally unresponsive with pupils fixed and dilated and with incontinence of urine. Deep tendon reflexes were exaggerated with plantar responses extensor. Within minutes, the patient became responsive again; pupils were reactive, although the right remained sluggish. The patient made purposive movements and obeyed commands. Lumbar puncture subsequently indicated grossly bloody spinal fluid. The patient remained confused and less alert with a tendency to fall asleep.

On September 17, 1965, the patient again suddenly complained of violent headache and lost consciousness for approximately 30 minutes. The right pupil became dilated, and the right eye deviated to the right suggesting a right medial rectus weakness. The blood pressure again rose to 240/140. As previously, the patient regained consciousness. Although confused, he had no clearly lateralizing signs. Subsequent lumbar puncture again revealed the presence of fresh red blood cells.

Because repeated episodes of bleeding had occurred, surgical therapy was undertaken. On September 21, 1965 a left frontal craniotomy was performed by Dr. Robert Yuan. The left frontal pole was resected exposing the left anterior cerebral artery and the aneurysm which arose from the anterior communicating artery. The medial surface of the right frontal lobe was cystic and contained 20 cc. of hematoma. The hematoma was evacuated. The aneurysm was reinforced by spraying with a plastic coating.

Neurological examination approximately 1 week after surgery indicated that the patient was confused and disoriented, with a "rather negative response" refusing to follow directions and to speak to examiners. Blood pressure was noted to be extremely labile with a drop of 50 mm. of mercury systolic when the patient moved from prone to sitting position. Equivocal Babinski signs were present, and the patient was incontinent of urine and feces.

Reevaluation on November 17, 1965, approximately two months after surgery, indicated that although the patient was ambulatory and able to take care of his daily needs, he remained confused for time and place. When the patient was examined 6 months after surgery, confusion was no longer present; intellectual functions were consistent with his education.

Approximately 2 years after surgery, the patient, who had recently been married, reported that he was impotent, unable to obtain an erection.

Comment:

In this case, the history of sudden onset of severe headache and stiffness of the neck, precipitated by exertion, clearly suggested a subarachnoid hemorrhage originating from the rupture of an intracranial aneurysm. It is likely that several episodes of subarachnoid bleeding occurred in June and September of 1965. While the clinical findings of somnolence and confusion with a decrease in olfaction on the right may have suggested the possibility of an anterior communicating-artery location, these were certainly not firm diagnostic clues. The episodes characterized by sudden alteration in blood pressure, while nonspecific, might have raised the question of orbital-frontal, anterior cingulate, or hypothalamic effects (areas within the distribution of the anterior-cerebral arteries).

The negativity of the patient following surgery undoubtedly indicated preoperative and operative damage to the orbital and prefrontal areas. The bilateral Babinski signs and the incontinence of urine and feces in the postoperative period probably reflected damage to the parasagittal motor and premotor areas within the distribution of the anterior cerebral arteries. The impotence may have reflected damage at the frontal or hypothalamic level.

Today, an initial episode such as occurred in June 1965 would have prompted a CT scan and a lumbar puncture if that study had been negative. Of course many exertional headaches are not a result of

subarachnoid hemorrhage. Nevertheless the more serious entity must be ruled out at the emergency room level, since the mortality and morbidity of the frequent recurrent hemorrhage are so high. Again the use of early arteriography and early surgery are to be emphasized.

Case 26-11 illustrates many of the neurologic aspects of bacterial endocarditis.

Case 26-11: This 34-year old right hand married white male hair dresser was admitted with a one month history of night sweats, fever to 102-103° F., generalized aches and pains. Within the previous 3-4 months, the patient had undergone repeated dental procedures for dental infection. He had been reported to have a mild heart murmur 2-3 years prior to admission. His urine had recently become dark. The day prior to admission he had noted a small hemorrhagic lesion on the dorsum of his left hand.

Physical exam:

1) Skin: A small indurated red lesion dorsum left hand and a small red lesion under the nail bed 3rd left toe.

2) Heart: A grade IV/VI high-pitched holosystolic murmur was present at the apex; and a high-pitched II/VI murmur at the base; both not previously noted to this degree.

3) Temperature was elevated to 101° F

Neurological examination: Entirely within normal limits.

Clinical diagnosis: Bacterial endocarditis with systemic emboli but without neurological symptoms at this point.

Laboratory data:

1) **CBC:** Anemia with hematocrit 31 and hemoglobin of 10.1.
White blood count was 9900 with differential of 78% poly-morphonuclears and 9 atypical lymphocytes.

2) Sedimentation rate was elevated to 38 mm.

3) **Urinalysis** indicated 8-10 red blood cells per high power field.

4) All three **blood cultures** drawn on the day of admission produced growth of streptococcus viridans (alpha hemolytic).

5) **Echocardiogram** indicated a prolapsed mitral valve with probable mitral insufficiency. In addition, irregular densities on the mitral leaflets suggested vegetations.

Hospital course: All of these findings were consistent with a diagnosis of subacute bacterial endocarditis with evidence of microemboli to extremities (skin lesions) and to kidneys (hematuria). The patient was begun on high dosage intravenous penicillin (24 million units per day) with an excellent response as regards fever and general symptoms. Thirteen days after admission he again developed a temperature elevation. The following day, at 2 p.m., he abruptly developed difficulty with speech and a right hemiplegia. Over the next 2 hours this rapidly evolved to the following neurological state.

Neurological examination:

1) Mental Status and Language Function

a) The patient was drowsy - holding the left side of his head as though in pain.

b) He was mute.

c) He was unable to carry out any spoken or written commands.

2) Cranial Nerves

a) The patient neglected the right visual field and had no response to threat in the field.

b) The fundoscopic exam indicated blurring of the disc margins on the left.

c) Right central facial weakness was present.

d) Pain sensation was decreased on the right side of the face.

3) **Motor System:** A flaccid right hemiparesis was present although some purposive withdrawal of the right arm and leg occurred on painful stimulation.

4) Reflexes

a) Deep tendon reflexes were increased bilaterally but right were greater than left with clonus of the right ankle.

- b) The right plantar response was extensor, the left flexor.
 - 5) *Sensation*: A right-sided hypalgesia was present. Other modalities could not be tested.
 - 6) Neck and Skin
 - a) No nuchal rigidity was present.
 - b) New splinter hemorrhages were present under the nails of the upper extremities.
- Neurological diagnosis:** Cerebral embolus left middle cerebral artery, with possible mycotic aneurysm and possible hematoma left middle cerebral artery secondary to bacterial endocarditis.

Laboratory data:

An immediate CT Scan (Fig. 26-30) demonstrated a large intracerebral hematoma involving the left basal ganglia and insula with massive shift of the left hemisphere to the right.

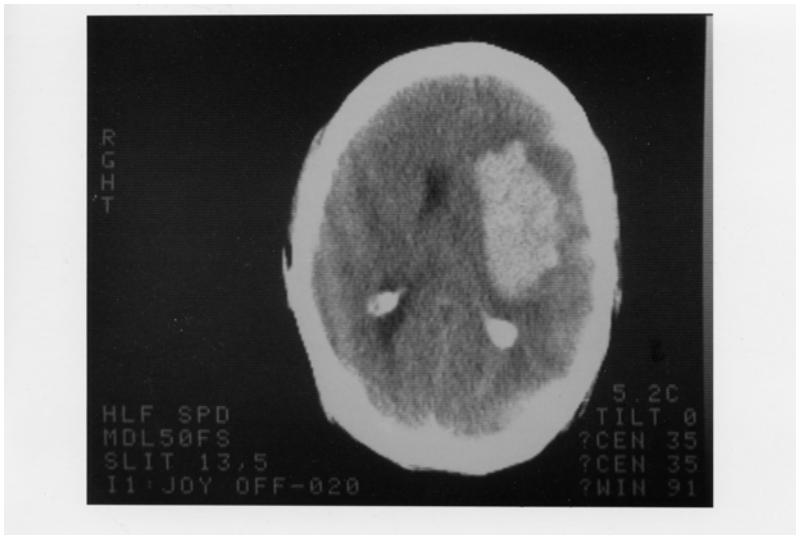
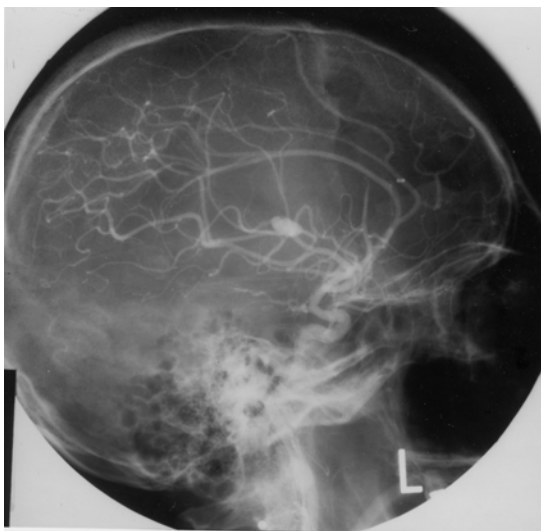


Figure 26-30.

2. An immediate arteriogram: (Fig. 26-31A) demonstrated a small aneurysm (arrow) arising from a small branch of the left middle cerebral artery (MCA) within the Sylvian fissure. A large avascular area surrounded this aneurysm with upward and lateral displacement of anterior cerebral arteries, medial displacement of lenticular striate, branches of the MCA and lateral and downward placement of the cortical MCA branches.



Subsequent course: That evening Dr. Robert Johnson removed a large intracerebral clot. Over the next 2 weeks the patient began to have some improvement in his right hemiparesis and aphasia. However two weeks after surgery, he developed right-sided focal status epilepticus. The patient had been receiving Phenytoin (Dilantin) but the level was low. Intravenous Phenytoin, intravenous Dexamethasone and Mannitol were administered. The CT scan now demonstrated a larger hemorrhage surrounded by edema. The patient was taken to surgery and additional old clot and a small amount of recent clots were removed. The patient failed to respond. He developed fixed dilated pupils and bilateral Babinski signs. The arteriogram (Fig.26-31 B,C) was repeated and now demonstrated a much larger aneurysm (measuring 11 mm vs 4-5 mm in previous films). There was also evidence of additional shifts of the anterior cerebral artery and internal cerebral vein. Anterior-frontal branches of the middle cerebral artery were occluded. Regression occurred and 8 days later patient met brain death criteria with absence of all brainstem reflexes, no spontaneous respirations and an absence of all cerebral electrical activity (silent EEG).

Comment: This patient presents a panorama of almost all of the cerebral complications of bacterial endocarditis including:

- a) Multiple septic emboli to brain, kidney, and small peripheral arteries;
- b) Mycotic aneurysm;
- c) Intracerebral hematoma
- d) Eventual mortality.

The mycotic aneurysm with eventual rupture was not a feature noted on presentation but instead was a late complication. (A silent unruptured aneurysm may well have been present on admission.) This subacute delayed presentation is more common in streptococcal endocarditis as opposed to the more virulent staphylococcal infections where acute intracranial presentations are the rule.

In this case, the aneurysm when initially discovered was small and associated with an intracerebral hemorrhage.

The aneurysm continued to enlarge after evacuation of the initial hematoma and eventually additional hemorrhage occurred. Not all patients with mycotic aneurysm will have intracranial hemorrhage. In the series of Brust et al (1990), 41% were associated with rupture. Of 20 aneurysms followed with angiography or CT scan, ten became smaller or disappeared, 10 remained unchanged or enlarged despite an adequate treatment course with antibiotics. In the present case, initial rupture occurred almost 2 weeks after admission and beginning of antibiotic treatment.

The recommended approach in patients with endocarditis to avoid the fatal complications of mycotic aneurysm rupture is to perform 4 vessel angiography in those patients with endocarditis who develop neurological symptoms. If a mycotic aneurysm is found, prompt surgical treatment (clipping) should be performed. Unfortunately many patients with mycotic aneurysms have no neurological symptoms prior to rupture. To perform angiography in all patients with bacterial endocarditis, would not be practical and would fail to detect aneurysms that developed after the studies. However, when long-term anticoagulation is planned in patients on the completion of antibiotic treatment to prevent additional emboli, angiography should be performed or repeated. The entire role of anticoagulation in bacterial endocarditis remains unclear. (See Salgade et.al 1987 and Hart et.al 1987, 1990). MRI may have an increasing role in non-invasive diagnosis, since MRI angiography should be able to detect aneurysms greater than 2-3 mm in diameter

Figure 26-32. Arteriovenous malformation in the right parietal area demonstrating the abnormal tangle of vessels and infarction of the surrounding cerebral cortex and white matter.

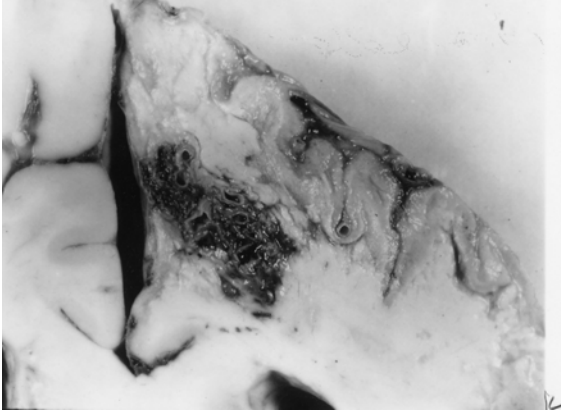


Figure 26-32. In this case, the malformation was fed mainly by the right anterior cerebral artery and drained into the superior sagittal sinus. This 46-year-old woman had, as a primary problem, subarachnoid hemorrhage from an anterior-communicating saccular aneurysm, with other unruptured aneurysms at left posterior communicating, and right superior cerebellar. (Courtesy of Dr. John Hills).

Case history 26-12 provides an example of a long-term unruptured arteriovenous malformation presenting as a seizure disorder.

Case 26-12: This 51-year old right-handed female experienced two nocturnal generalized convulsive seizures 6 years prior to evaluation . Evaluation by Dr. Robert Bazemore at that time revealed a significant 30-year history of minor episodes: “little sensations”. The patient described sudden strange feelings as though moving in slow motion. With other episodes she would feel at a distance from her surroundings with a sense of detachment at times with a strange odd smell. After 2-3 minutes the “spell” would alter, she would feel depressed with a sense of terrible fear. The patient also had a long history of migraine headaches (bilateral throbbing) which were often preceded by visual auras more prominent in the right visual field. The neurological examination was normal. She was treated with anticonvulsant (Phenytoin). When seen by the author for other unrelated neurological problems 6 years later , the interval history indicated no additional generalized seizures but complex partial seizures had continued.

Neurological examination: entirely within normal limits.

Clinical diagnosis : Simple and complex partial seizures of temporal lobe origin .

Laboratory data:

1. The *CT scan without enhancement* now demonstrated a calcified lesion in the anterior-medial right temporal lobe which enhanced with contrast (Fig. 26-32A). Large early draining veins were also noted (Fig. 26-32B).

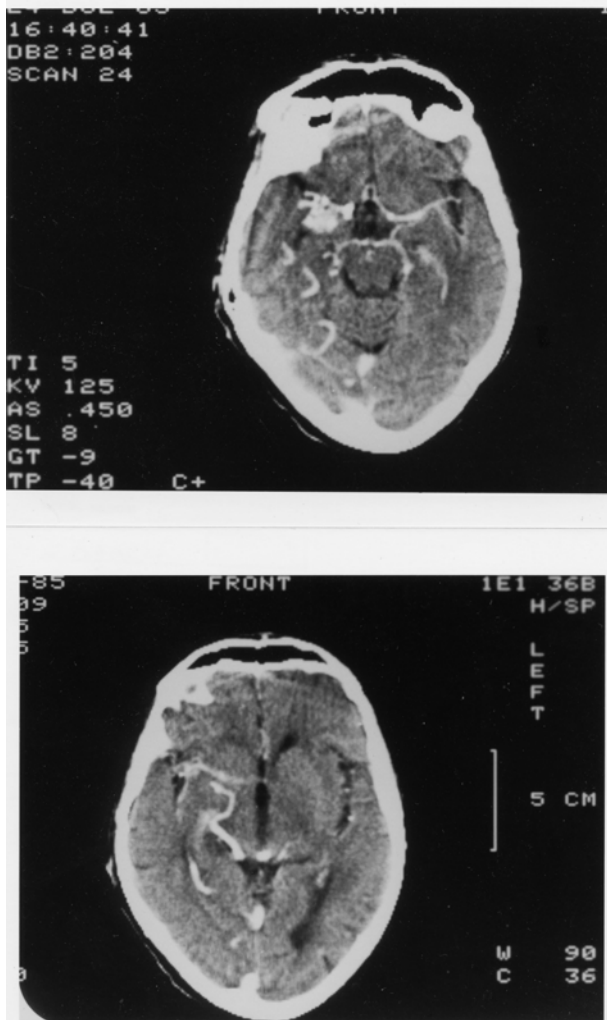


Figure 26-33. Arteriovenous malformation. Right anterior temporal:
 Case History 24-12 CT Scan. This 51-year-old right-handed female
 was evaluated in 1983. She had generalized seizures in 1977 and 36-
 year history of complex partial seizures. She would feel "weird
 sensations" and detached with a "strange odd smell", then a sense of
 terrible fear. She also had a history of migraine headaches preceded
 by visual auras, and a normal neurological examination. was not
 remarkable. The CT Scan without contrast demonstrated a calcified
 lesion in the right anterior temporal lobe (not shown).
 A). With contrast a large enhancing lesion was present in the deep
 Sylvian fissure area - involving anterior medial temporal areas, uncus
 and adjacent insula.
 B) At a higher level of section a large draining vein was visualized (see
 also fig 26-35 and text for details).

Subsequent angiographic studies confirmed the anterior venous malformation with supply from right internal carotid, middle cerebral and anterior choroidal arteries (26-33A) and the presence of shunting into a large early draining vein (26-33B).

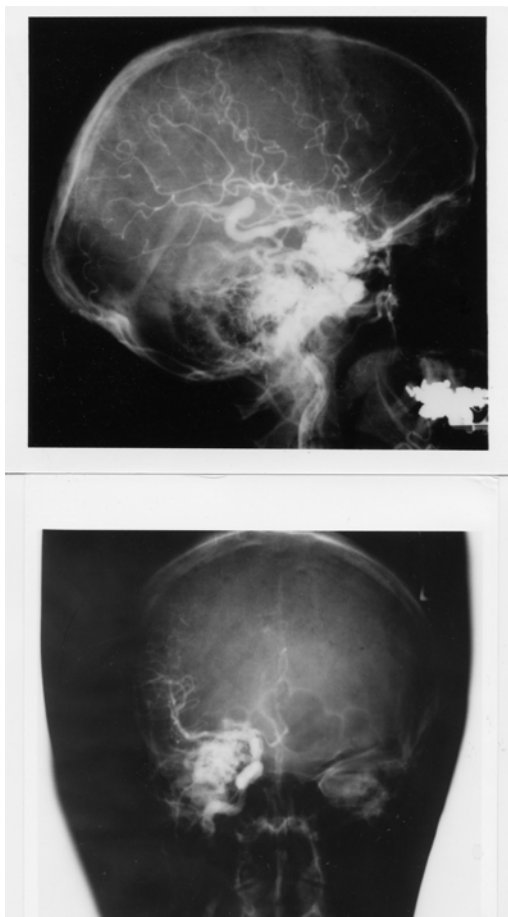


Figure 26-34. Arteriovenous malformation: Right anterior temporal lobe. Right carotid arteriograms. Case History 24-12

- A) Malformation - supplied by right internal carotid, middle cerebral, and anterior choroidal branches.
- B) There is early shunting of arterial blood into a large draining vein. See Text and Fig. 26-34 for details.

Comment: This patient presented with classical complex partial seizures originating in the right temporal lobe. No definite evidence of either subarachnoid or intracerebral hemorrhage was present over 35 years. With the use of CT and MRI scan, more of these lesions are being identified in an unruptured state in patients investigated for seizures and headaches.

Considerable controversy remains as to the appropriate therapy for the unruptured cerebral arteriovenous malformation (compare Aminoff, 1987 and Heros and Yong-Kwang, 1987). Long-term follow-ups - 12-20 years - does suggest a 25-39% risk of hemorrhage with a mortality from that hemorrhage of 10-14%. The risk of recurrent hemorrhage the first year is 6% with the subsequent annual risk for hemorrhage for both ruptured and unruptured 3% per year (see also Crawford et al, 1986, Brown et al 1988, Rigamont, et al 1988).

Surgical therapy involved excision after ligation or embolization of feeding vessels (Stein and Wolpert, 1986, Stein and Mohr, 1988, and Mohr, et al 1986).

CHAPTER 27: NON VASCULAR SYNDROMES : TRAUMA, TUMORS, INFECTIONS, TOXIC METABOLIC AND SYSTEMIC DISORDERS

I TRAUMA

Case 27-1 presents an example of an epidural hematoma seen in 1963 prior to modern neuroimaging.

Case 27-1: This twenty-two-year-old, white airman, during a winter storm, was involved in an auto accident at 11:30 p.m., in which he struck his head against the windshield. He also sustained minor abrasions of the shoulder, hands and chest. The patient apparently was dazed, perhaps unconscious, for a matter of seconds to minutes. He was taken by ambulance to the emergency room of the nearby army hospital where a brief evaluation indicated that the patient was alert, without definite neurological findings, and apparently without significant injuries. Skull X-rays did indicate a linear fracture over the right temporal area which did not, however, definitely cross the major groove of the middle meningeal artery. The patient was, therefore, admitted to the intensive care ward for head injury observation.

The patient was apparently alert upon his arrival on the ward. It should be noted, that the major attention of the physicians in the emergency room and of the nurses on the intensive care ward was given to four other patients from the same accident who sustained very severe and obvious injuries. However, by 5 a.m., the patient was reported by the nurses to be agitated and confused.

Neurological examination: (8 a.m.)

1. *Mental Status:* The patient was agitated and unable to cooperate. He was sitting up in bed, holding his head, moaning and hyperventilating to a marked degree. He answered only occasional questions and then with a yes or no.

2. *Cranial Nerves:* intact except

Fundi: The examination was negative but incomplete.

Pupils: There was a bilateral but sluggish response to light. A minimal asymmetry was present. The right pupil was perhaps slightly larger and slightly more sluggish than the left.

3. *Motor System:* All limbs were moved spontaneously. There was a variable increased resistance to passive motion, but this was apparently due to the patient's inability to cooperate.

4. *Reflexes:* Deep tendon reflexes were increased bilaterally. Plantar responses were bilaterally equivocal.

5. *Sensation:* Pain sensation appeared to be intact.

6. *Neck:* There was variable resistance to attempted flexion.

7. *Head:* The patient moaned when palpated over left or right temporal areas.

Neurological diagnosis : Possible evolving acute bilateral epidural or subdural hematoma

Subsequent course: The patient was to be evaluated by the civilian neurosurgical consultant, whose arrival was delayed by several other emergencies and a snowstorm. In the meantime, progression occurred.

Neurological examination (4 p.m.): The patient was now deeply comatose with little response to stimulation. The pupils were now bilaterally fixed and dilated. The four limbs were extended in a decerebrate posture with significant spasticity on passive motion. The degree of spasticity in the upper limbs could be modified by tonic neck maneuvers. The plantar responses were bilaterally extensor. Spontaneous respirations were now irregular and infrequent, and the patient required the assistance of a mechanical respirator.

Neurological diagnosis: Acute tentorial herniation with brain stem compression secondary to epidural hematoma.

Subsequent course: A general surgeon immediately performed definitive therapy. Bilateral burr holes were placed. An epidural hematoma over the right temporal-parietal area was evacuated and the

bleeding middle meningeal artery branch was coagulated and ligated with a significant rapid improvement in the patient's status. Follow-up examination approximately two months later indicated that the patient had returned to active duty but was experiencing some problems related to changes in recent memory and to changes in motivation and personality. No significant motor or sensory findings were present. Minor and inconsistent asymmetry of deep tendon reflexes was present.

Comment: This patient followed the usual pattern of a short lucid period followed by the rapid progression of confusion, agitation, coma and brain stem deterioration of function. As indicated by Plum and Posner (1980), the development of hyperventilation is often indicative of a midbrain-upper pontine stage of damage from an expanding supratentorial lesion. The early appearance of hyperventilation followed by bilaterally fixed dilated pupils and a decerebrate state may well indicate that the supratentorial lesion was producing a more central downward compression of the midbrain and less of a lateral uncal-type compression. In any case, it is evident that brain stem compromise was progressing rapidly. So rapidly, in fact, that therapy had to be undertaken immediately. In such a case, there was no longer time for the transfer of the patient to a specialized treatment center and no longer any time for specialized laboratory studies. Today, such a patient would have undergone CT scan studies at the time of emergency room evaluation or at the first sign of change in mental status. Similar cases of recovery of function from brain stem compression in patients with acute subdural or epidural hematomas have been reported by Brendler and Selverstone (1970).

The following case provides an example of chronic bilateral subdural hematomas

Case 27-2. (Patient of Dr. Alex Danylevich). This 83-year-old white female was transferred from her local hospital because of increasing confusion. Two months prior to admission, she had been involved in a motor vehicle accident sustaining fractures of her ribs and left clavicle. She also struck her head and had a scalp hematoma in the right frontal area. She was admitted to her local hospital at that time for several days. She was described as having post-traumatic anterograde and retrograde amnesia and obtundation which cleared over her hospital stay. She returned to her usual activities. Two months after the trauma she re-entered her local hospital with a three day history of increasing confusion and lethargy. When she became mute she was transferred to St. Vincent Hospital. Serum sodium at her local hospital had been low at 124 mEq/liter and CSF protein was reported at 62 mg%. EEG was reported as diffusely slow.

Neurological examination:

1. *Mental status:* She was relatively lethargic but could be aroused to an alert state. The patient was mute and did not follow commands even when relatively alert.
2. *Cranial nerves:* Pupils were 2 mm. and reactive. Sudden paroxysmal nystagmoid deviations of the eyes to the right occurred during the exam.
3. *Motor system:* Strength was intact. Tone was increased in the right leg.
4. *Reflexes:* Deep tendon stretch reflexes were symmetrical. Plantar responses were extensor bilaterally.
5. *Sensory system:* Pain responses were intact.

Clinical diagnosis: Chronic subdural hematomas, probably bilateral .

Laboratory data:

1. The CT scan (Fig. 27-3) demonstrated significant bilateral chronic subdural collections much denser on the left where the lateral ventricle was obscured and shifted to the right. The right lateral ventricle and sylvian fissure were enlarged. There was a question of additional recent rebleeding into the subdural collection on the left.
2. Serum sodium was low at 117 mEq/liter. Serum osmolality was 236. Urine sodium was 53 mEq/liter.

Hospital course: Serum sodium was corrected. Then, bilateral subdural hematomas were removed via burr holes on the right and a bone flap on the left where substantial chronic membrane and fluid were found. Neurological examination eight hours after conclusion of the procedure, indicated an alert patient who had no apparent language disorder and no weakness. Follow-up CT scan ,6 days after surgery revealed re-expansion of the cerebral hemispheres. Considerable cortical atrophy was

now evident. This was presumably long-standing predating the subdural hematomas. She was transferred back to her local hospital, 10 days after surgery. At that point she was alert; ambulating with assistance and was able to feed herself. She did develop transient right face and hand focal motor seizures which were treated with anti-convulsants.

Comment: If the history of trauma two months previously had not been present with a prior hospital admission related to the trauma, the confused obtunded mute state in this patient might easily have been attributed to a metabolic encephalopathy (low serum sodium) or to the cortical atrophy of a senile dementia of Alzheimer's type. Many patients with primary cerebral disease will develop a low serum sodium due to inappropriate secretion of anti-diuretic hormone with retention of water and dilution of serum sodium. The mute state in this patient in retrospect probably reflected the severe involvement of the dominant left cerebral hemisphere. The sudden eye movements to the right probably represented focal seizure activity originating in the left frontal eye fields, not far from the cortical area providing the focus for the post operative seizures.

In some patients without a definite history of trauma, the predominant findings may be those of a progressive bilateral frontal lobe involvement with confusion, bilateral grasp reflexes, and a frontal lobe apraxia of gait. In such patients, the nature of the pathological process involving the frontal lobes may be uncertain. The differential diagnostic list may include metastatic disease, frontal parasagittal meningioma or frontal glioma.

There are patients who are at increased risk for subdural hematomas: patients receiving anticoagulant medications, or patients with bleeding disorders, e.g., as in leukemia. The problem is more common in the elderly, in chronic alcoholics, and in patients with Parkinson's disease perhaps because such population groups are more prone to unsteadiness and falls. In the patient with cortical atrophy as in Alzheimer's disease, the bridging veins may be stretched and thus more prone to tear. In addition, the patient is unable to recall minor trauma and is already confused. In addition, because of the atrophy, a large amount of blood may accumulate in the subdural space without producing early symptoms of headache and other symptoms.

The problem also exists in the infant during the first year of life. The picture presented, however, differs significantly from that seen in the adult because in the infant, separation of the sutures may occur, allowing the intracranial cavity to expand. The onset is then often nonspecific and nonfocal: an enlargement of the head, a failure to thrive, a failure to gain weight, a failure to reach developmental landmarks. At times, generalized seizures, vomiting, and papilledema may be noted. The etiology often relates to presumed birth trauma.

A related problem may also be seen in infants following meningitis. This is the problem of subdural effusions usually occurring in relation to Haemophilus influenzae meningitis. The diagnosis of both subdural hematoma and subdural effusions may be made in the infant by CT or MRI scan replacing the earlier technique of subdural taps. The cerebrospinal fluid in these cases is often found to be abnormal with the presence of blood or xanthochromia and an elevated protein content.

II TUMORS

The following case history provides an example of the course of a low grade glial tumor.

Case 27-3: This 41 year old right handed white widow was admitted to the hospital because of increasing frequency of seizures. At age 30, eleven years prior to admission, the patient experienced her first generalized convulsive seizures. The neurological examination and the electroencephalogram were normal. Four years prior to admission, the patient had a change in the character of her seizures, she began to experience focal seizures involving the right arm and leg. These would begin with the sensation of a "chill" or stiffening of the right leg and a "numbness" (a tingling) which would then spread to the lower back. At the same time, weakness would occur in the right leg followed by repetitive clonic movements of the right arm. During this time, the patient would be unable to talk distinctly but would be aware of her surroundings. Although the episode continued for several minutes, there was no apparent loss of consciousness. Examination by Dr. John Hills at that time revealed a slowness of response but no definite neurological deficits. The EEG was again normal. Neurological evaluation three years later (one year prior to admission) was again unremarkable although focal seizures were still occurring every 2-4 weeks. Evaluation 2 months prior to admission, now indicated a more increase in deep tendon stretch reflexes in the

right lower extremity and an equivocal plantar response on the right side .Hospital admission finally occurred because the weakness experienced in the right leg during the seizure was becoming more severe.

Neurological examination

1. *Mental status*: The patient was anxious and tremulous with moderate psychomotor retardation and poor attention span. Digit span was limited to 5 digits forward and 4 in reverse .However orientation, memory ,delayed recall , calculations and language function were all intact.
2. *Cranial nerves*: All were intact with no papilledema.
3. *Motor system*: Strength, gait and cerebellar signs were all normal.
4. *Reflexes*: Deep tendon reflexes were slightly increased on the right side. The plantar response on the right was equivocally extensor.
5. *Sensory system*: Intact except for a minimal bilateral decrease in sensation at the toes.

Clinical diagnosis: Left parasagittal tumor most likely a meningioma, low grade glial tumor such as oligodendroglioma or low grade astrocytoma considered possible but very unlikely.

Laboratory data:

1. Chest and skull x rays ,radioactive brain scan(Hg 197) and left carotid arteriogram were all normal.
2. *EEG* was now mildly abnormal because of occasional focal sharp waves ,left parietal parasagittal area.
- 3.*Pneumoencephalogram* demonstrated a slight downward depression left lateral ventricle suggesting a possible left parasagittal mass. The CSF obtained was normal.

Subsequent course: Since the brain scan and arteriogram were normal, a meningioma was considered unlikely and a low grade glioma was considered the most likely diagnosis. The lack of calcification on the skull x rays was considered a point against the diagnosis of an oligodendroglioma and more in favor of a low grade astrocytoma. Since the patient was relatively free of neurological deficit and the dominant hemisphere was involved, neurosurgical intervention was deferred .Her anticonvulsant medications were readjusted. Frequent office evaluations indicated that significant progression was occurring with increasing weakness of the right leg, and an inability to form letters in handwriting. .Four months after hospital discharge ,the patient now had a right central facial weakness ,a mild right hemiparesis, and increased deep tendon stretch reflexes on the right and a right Babinski sign. Speech was dysarthric with a minor degree of misnaming or inability to name objects. A left carotid arteriogram now indicated a deep left posterior frontal mass lesion. There was also a suggestion of abnormal vascularity in the region of the pericallosal and callosal marginal branches of the anterior cerebral artery. Surgical exploration of the left frontal area indicated slight discoloration of and widening of gyri. Probe counting located an area of increased uptake of isotope (P32) at 16X normal in the mid and posterior frontal area. A partial frontal lobectomy was performed from the level of the sphenoid wing laterally and forward but sparing the speech areas. However tumor was still present at the posterior margin of the resection . Histologic examination of the tumor removed indicated a grade I- II astrocytoma. Following surgery ,the right sided weakness progressively improved, speech was unchanged. Following hospital discharge the patient ,received a 3 month course of supervoltage radiation (7,500 roentgens)directed to the left frontal parietal area. When last evaluated 18 months after surgery, there was a moderate disorientation for time , a nominal aphasia a slowness in following commands ,a perseveration of speech and performance, a right central facial weakness and a clumsiness in following commands.

Comment: The onset of seizures at age 30 ,always raises the question of a possible brain tumor. The initial seizures however were generalized convulsive seizures and the neurological examination and the EEG were normal, thus decreasing the risk of a tumor. When focal seizures appeared at age 36,the risk of a tumor was significantly increased but still ,the exam and the EEG remained normal .In retrospect ,the slowness of response might have suggested some frontal lobe involvement. By age 41, it was evident that a focal process was slowly evolving with some involvement of parasagittal motor cortex. Again the psychomotor retardation and the deficit in digit span at a time that delayed recall was normal (possibly consistent with an impairment of working memory) might have suggested some degree of. prefrontal involvement. Certainly, by the time of surgical intervention, 11 years after onset of symptoms, the pace of progression had accelerated. This might have indicated some alteration in the basic biological activity of the tumor.

Finally a note about diagnostic techniques . This patient was initially seen in 1956 and hospitalized in late 1967. At the time CT scan and MRI were not yet available. Today, an adult with onset of seizures at age 30 would have undergone an MRI or at least a CT scan with contrast. The diagnosis would have been made much earlier in time but the eventual treatment and results of treatment would probably not differ significantly from those obtained in 1967. The role of radiotherapy in low grade gliomas remains controversial. There is a role once transformation to a higher grade of malignancy has occurred.

MALIGNANT GLIOMAS

The following case demonstrates the apparent acute (possibly stroke like) onset and rapid progression of a very malignant glioblastoma multiforme.

Case 27-4 (patient of Dr. Tom Mullins): This 68 year old right handed white male was admitted to St Vincent Hospital with an apparent 4 to 5 day history of difficulty in doing calculations and in speaking, “he could think of the word ,but had difficulty getting it out”.

Neurological examination :

1. *Mental status and language function*: Speech was limited to short phrases with loss of connectors and sentence structure. Writing was impaired but, repetition, comprehension, naming and reading were intact.
2. *Cranial nerves*: Intact.
3. *Motor system*: Strength and gait were intact .However fine motor movements of the right hand were impaired .
4. *Reflexes*: Tone was increased on the right. The right patellar reflex was increased. Bilateral Babinski signs were present.
5. *Sensory system*: Intact.

Clinical diagnosis: Diagnosis was uncertain .The abrupt onset suggested a possible vascular event such as an embolus in the middle cerebral artery territory but the overall pattern including bilateral Babinski signs without significant hemiparesis was unusual. Thus other possibilities had to be considered including focal herpes simplex encephalitis, tumor or a small lobar hemorrhage.

Laboratory data :

1. EEG : Focal left hemisphere delta and theta slow wave activity was present.
2. CT scan(Fig.27-7):A. The non enhanced study demonstrated a low density mass in the mass in the left frontal-parietal parasagittal region with areas of hemorrhage. B. The contrast enhanced study demonstrated an irregular rim of enhancement.
3. Angiogram indicated an avascular mass in the left frontal-parietal area.

Subsequent course: Dr. Alex Danylevich performed a subtotal resection of this tumor which was found to contain blood clot and cystic fluid. The histology of the tumor was glioblastoma multiforme (Fig.27-5). The patient subsequently received 4000cGy whole brain radiation and an additional 2000cGy to the tumor site. Three months following surgery ,the patient developed increasing obtundation. CT scan revealed a large left frontal necrotic mass. Fever, hypocalcemia and hypernatremia developed and he expired one month later.

Comment: This patient presented with what appeared to be an abrupt onset of language problems raising the question of a cerebrovascular accident. In retrospect , it was evident on the CT scan and at surgery that the acute onset reflected the hemorrhage and necrosis which had occurred within the tumor. This was a rapidly growing ,extremely malignant tumor which apparently had outstripped its blood supply despite the neovascularity.

III INFECTIONS

FOCAL

Subdural empyema

The following case provides an example of subdural empyema complicating frontal sinusitis.

Case 27-5. This forty-eight year old, right-handed, white male was referred for evaluation because of headaches and papilledema. For 3 weeks prior to admission, the patient had severe bifrontal headaches which were constantly present and interfered with sleep. One week prior to admission, the patient developed a fever of 105° with a white blood count (WBC) of 25,000. X-rays indicated "sinusitis". The patient was hospitalized at his local community hospital. Confusion soon developed. Three days prior to transfer to a neurologic unit, the patient had a series of seizures characterized by turning of the head and eyes to the left. Lumbar puncture had indicated clear cerebrospinal fluid with pressure of 300 mm. and protein increased to 65 mg./100 ml. The patient had chronic right nasal discharge for ten years. Eight weeks prior to admission, the patient, while stooping down, struck his right frontal areas but was not - unconscious. A right periorbital ecchymoses developed, and the patient also had the onset of bilateral frontal headaches.

General physical examination: Temperature was elevated to 101°. There was right periorbital edema. Excoriation of right nasal mucosa was present.

Neurological examination:

1. **Mental status:** The patient was alert but irritable and slightly confused. He was poorly attentive and failed to persist in carrying out motor activities. He was oriented grossly for time, place and person. Calculations were poorly performed. Delayed recall was defective.
2. **Cranial Nerves:** All were intact with the exception of the fundi. Low-grade papilledema was present and venous pulsations were absent.
3. **Motor System:** Strength was intact, but there was a slight drift downward of the outstretched left arm.
4. **Reflexes:** Deep tendon reflexes were somewhat brisker at left arm and leg (3+) as compared to the right (2+). Plantar responses were flexor. A bilateral grasp reflex was present.
5. **Sensory system:** Intact
6. **Skull & Neck:** There were slight tenderness over the right periorbital area. Minimal nuchal rigidity (resistance to passive flexion of the neck) was present.

Clinical diagnosis: Right frontal subdural empyema or brain abscess.

Laboratory data:

1. The *WBC* was increased to 14,350 cells per cubic mm., and the sedimentation rate was increased to 110 mm. in one hour.
2. **Sinus X-rays:** Bilateral maxillary and frontal sinusitis was present with resorption of bone.
3. **Electroencephalogram:** Focal 4 to 7 cps slows wave activity was present in the right parietal area suggesting focal damage. Moreover, focal voltage suppression (reduction of voltage) was present in the right anterior frontal area suggesting a possible subdural collection.
4. **Right carotid arteriogram** showed an apparent slight shift of the anterior cerebral vessels to the left suggesting a right hemisphere space-occupying lesion.

Hospital Course: Following these studies a right frontal trephine (burr) hole was placed by Dr. Robert Yuan. When the dura was incised, 5 cc. of yellow purulent material escaped from the subdural space and additional purulent drainage was aspirated. Additional burr holes were placed in the right occipital area where a few drops of subdural pus were encountered. No pus was obtained from the left subdural area. Subsequent cultures demonstrated *Staphylococcus aureus* as the responsible organism. The dura and cortex otherwise appeared unremarkable although cerebral edema was present. The patient was subsequently treated with appropriate antibiotics. His temperature gradually subsided to normal and his mental

status cleared. Three weeks later, a bilateral frontal sinusotomy was performed by Dr. Thomas Klein with drainage of the sinus. Histological examination of a section of sinus mucosa removed demonstrated intense chronic inflammation. The patient continued to improve. When seen in followup examination four months after admission, papilledema had subsided, no neurological findings were present except for a slight reflex asymmetry (slightly increased on the left).

Comment: This patient presented a definite history of chronic nasal sinus infection with a recent exacerbation. The role of trauma in the exacerbation is uncertain. It is clear, however, that the sinusitis had produced involvement of the adjacent bone with subsequent spread to the adjacent frontal subdural space. The severe headache experienced by the patient reflected not only the process of infection involving the sinus and meninges but presumably also the increase in intracranial pressure. The early involvement of the right frontal area was suggested by the initial symptoms of confusion and by the occurrence of focal seizures characterized by turning of the head and eyes to the left. The findings of the electroencephalogram suggested a subdural collection of fluid or pus in the right frontal area.

These clinical and laboratory impressions were confirmed by the subsequent surgical observations. In the present case the arteriogram suggested only a non-specific space-occupying lesion in the right frontal area. The more specific finding in these cases would involve the displacement of distal branches of the anterior and middle cerebral artery from the inner table of the skull as in a subdural hematoma. Today the CT scan or the MRI/MRA is the study of choice for confirming the diagnosis of a subdural collection. Additional review of subdural empyemas will be found in Miller et al 1987. In the pre-antibiotic era, infections involving the nasal sinuses could produce thrombophlebitis of the cortical veins and superior sagittal sinus. With that complication, infarction of that area of motor cortex representing the leg could occur resulting in unilateral or bilateral leg weakness as well as focal motor seizures. Infection of the nose or face or of the ethmoid or sphenoid sinuses could produce thrombophlebitis of the cavernous sinus resulting in the syndrome discussed in the cranial nerve chapter: unilateral or bilateral involvement of the cranial nerves found in the lateral wall of the cavernous sinus (III, IV, VI and the ophthalmic division of V). The ophthalmic vein may be obstructed producing edema of the eyelid and face. Obstruction of the retinal vein produces papilledema. Infection of the middle ear or mastoid may produce involvement of the transverse or lateral sinus. If this extends to the jugular vein, increased intracranial pressure may also occur. However increased intracranial pressure may follow any involvement of the other venous sinuses. At the present time, dural venous sinus thrombosis is usually more indicative of dehydration and other systemic conditions in the infant and in the adult of immunological disorders or of conditions that produce a state of hypercoagulation such as polycythemia, carcinoma, pregnancy or birth control drugs. (refer to Daif et al, 1995 and DeVeber et al, 2001)

CHAPTER 30 MEMORY

A case of Wernicke-Korsakoff syndrome is presented in case 30-1.

Case 30-1. Patient of Doctor John Sullivan and Doctor John Hills): This 62-year-old, white, right-handed stonecutter had been a known heavy alcoholic spree drinker for many years. The patient would drink large quantities of wine for 6 to 8 weeks at a time. Two years previously, the patient had been admitted to the Boston City Hospital because of delirium tremens (tremor and visual hallucinations). Two months prior to admission shortly following the death of a brother-in-law, the patient began his most recent drinking spree. He unaccountably found himself in Florida, not knowing where he was and

why he was there. Apparently, he had drifted aimlessly for 5 weeks with no definite food intake for a month. The patient was brought back by his family and hospitalized at his local community hospital with diplopia, ataxia and marked impairment of memory. The patient had complaints of numbness of his fingertips and unsteadiness of gait. The patient after beginning treatment was shortly thereafter referred to the Neurology Service at the New England Medical Center.

General physical examination: No abnormalities were present except for an enlarged liver with the edge palpated approximately 2-1/2 finger breadths below the costal margin.

Neurological examination:

1. Mental status:

- a. The patient was markedly disoriented for time and place. At times, the patient thought that he was in New Jersey; at other times, he stated correctly that he was in Boston.
- b. The patient, with suggestion, would recall his apparent travels that day to various other locations within and outside Boston (he was actually in the hospital). Confabulation was also evident when it was suggested that he had recently seen various fictitious persons.
- c. Remote memory; The patient was unable to state his age. The patient was able to provide his birth date correctly. He could not give his address or telephone number. When quizzed as to the President of the United States, he selected on multiple choices the previous president. At times, the patient often indicated to visitors that his mother and father were still alive, though both parents had been dead for over 20 years.
- d. Insight; He appeared to have little insight for his disorientation in time. He had no insight as to his condition or for the reason for his hospitalization.
- e. The patient's digit span was normal at 7 forward and 6 in reverse.
- f. The patient could name various objects correctly when these were presented to him and yet he was unable to retain any memory of which objects had been presented to him five minutes previously. He was unable to retain any information concerning a story that he had been requested to learn.
- g. The patient was able to do 2 and 3 figure additions and multiplications without difficulty. He was able to do the initial subtractions in the serial 7 test but then lost track of the number to be subtracted.
- h. The patient was able to read and to write without difficulty. He showed no constructional apraxia and no left-right confusion.

2. *Cranial nerves:* There was horizontal diplopia on right lateral gaze. The minor degree of separation of images, however, did not allow precise identification of the muscle involved. A minor weakness of the right lateral rectus was suspected.⁶ Horizontal nystagmus was present on lateral gaze, bilaterally and vertical nystagmus on vertical gaze.

3. *Motor system:* Strength was intact except for a minor degree of weakness in the distal portions of the lower extremities evident on ankle dorsiflexion and toe dorsiflexion.

The patient walked on a narrow base with eyes open and showed no evidence of an ataxia of gait. On a narrow base with eyes closed, the patient had a positive Romberg test.

No cerebellar findings were present.

4. *Reflexes:* Deep tendon reflexes were normal at triceps and biceps, decreased at radial periosteal. And absent at patellar and Achilles even with reinforcement.

⁶ The minor nature of the diplopia undoubtedly reflected the improved nutritional status that had occurred during the previous 5 days of hospitalization at his community hospital. We presume that if the patient had been examined prior to hospitalization, more marked lateral rectus palsy probably would have been delineated.

Plantar responses were flexor bilaterally.

No grasp reflex was present.

5. Sensory System: Pain and touch were decreased in the lower extremities below the mid calf. Vibratory sensation was absent at the toes and decreased over the tibia to a marked degree and to a lesser degree over the knees. There was to a lesser extent, a decrease in the upper extremities at the fingertips and wrists.

Position sense was decreased at fingers and toes.

Clinical diagnosis: Wernicke' encephalopathy plus nutritional poly neuropathy

Laboratory data: Complete blood count, liver functions and renal functions, CSF, EEG, and X-rays of the skull and chest were all normal.

Subsequent course: The patient was treated with thiamine, 50 MGS daily. There was a significant improvement in extraocular functions. The patient had no diplopia after the day of admission. There was no significant change in his mental condition or peripheral neuropathy. Evaluation 3 months later, indicated persistent disorientation for time and place and severe selective deficits in memory (delayed recall was still grossly defective).

Comment: This patient presents a relatively typical history of the Wernicke-Korsakoff syndrome. He had been a heavy alcoholic spree drinker. The major symptomatology that was apparent to the patient's family and to his physician, related to his marked confusion, severe impairment of memory and confabulation. The patient himself had no significant complaints and little insight into his disease. In some cases, the severe memory disturbances may be present without any definite evidence of confabulation. Not only the retentive memory for new material was impaired but also the patient's distant memory was also significantly impaired. In such cases with severe impairment of memory the prognosis for a complete recovery of mental status is very poor. The diplopia and nystagmus, as expected, resolved significantly with treatment with thiamine. The ataxia of gait, which had been present early in the case, had apparently resolved by the time of transfer from his local hospital. A significant peripheral neuropathy, mainly distal sensory, was present related to multiple B vitamin nutritional deficiency.

In many cases, the state of confusion in Wernicke's encephalopathy is preceded by or accompanied by a period of delirium tremens indicating alcohol withdrawal. The use of intravenous glucose feedings without supplemental intravenous thiamine during such a withdrawal state may actually increase the requirements for thiamine, thus exacerbating the thiamine deficiency state. For this reason, all patients under treatment for alcohol withdrawal (or admitted to the hospital with a recent past history of alcoholism) should be treated with high dosage vitamin therapy as well, on the presumption that they are candidates for nutritional deficiency.

A case of transient global amnesia is presented in case 30-2 below.

Case 30-2: This 55-year-old, right-handed, white male, college professor, awoke at 3:00 a.m. on the morning of admission in an uneasy and restless state. He asked his wife what day it was but then did not recall what she had told him. He did not know the month, kept repeating himself and asking the same questions. His wife arranged for him to be seen early in the morning by his family physician who lived a short distance away. The patient, who was familiar with the route, was unable to find his way there. When he arrived at the doctor's office, he was unable to explain why he had come. The patient apparently had forgotten about the incidents, which had occurred earlier that morning. He had no recollection that he had a grandchild born three weeks before. He could remember no significant events from this 3-week period prior to the onset of his illness. The patient's more remote recall and other intellectual capacities remained intact. The patient drove into Boston later that day but became lost despite the usually familiar route.

The patient had a past history of gout with an elevated serum uric acid level.

Neurological examination: Findings were essentially limited to the mental status examination.

When examined in the early afternoon, the patient was beginning to regain some of his ability to retain new information. The patient was generally oriented to person and place. However, he was disoriented for the day and month but was oriented for the year. The patient's store of information was quite intact suggesting a highly intelligent person.

The patient had marked difficulty with delayed recall. He could recall none of the 4 objects after 5 minutes. He could not remember any of the three test phrases given to him when asked about these 5

minutes later. He did recall in a vague manner that a memory test had been given him. As regards recent memory, the patient was unable to remember his visit to his family physician earlier in the day. Digit retention, however, was relatively well preserved; 6 forward and 5 backward. The patient had no defects in calculation. There was no evidence of a constructional apraxia. Language function was entirely intact.

Clinical diagnosis: Probable transient global amnesia

Laboratory data:

1. Complete blood count, serology, blood urea nitrogen, total cholesterol, uric acid skull and chest X-rays, EEG and complete CSF were all within normal limits.
2. The *brain scan* demonstrated a small area of increased uptake of radioisotope (Hg197) in the left temporal region.

Subsequent course: Over the several hours following admission, the patient gradually regained his ability to retain new information and to recall the events of the preceding 3 weeks, the more remote events being recalled first. The memory for the events of the day prior to admission was regained last. This pattern is referred to as a shrinking retrograde amnesia. The specific events that occurred on the morning of admission were never recalled. The following morning delayed recall was four-out-of-four objects after 8 minutes. The patient's mental status and neurological examination were otherwise within normal limits. A repeat brain scan, 3 months after the episode demonstrated considerable improvement, and all brain scan findings had resolved at 5 months. No additional episodes occurred during the one-year after the acute episode.

Comment: The patient's main deficit was in learning new information (anterograde amnesia) with the old stored long-term memory information still intact. During the episode there was a retrograde amnesia that initially extended back for three weeks. As recovery occurred, this retrograde amnesia disappeared. These relatively recent past memories were intact but transiently not accessible. The labile stage of long-term memory has been estimated to be a matter of 20-180 minutes. This case suggests that there is not a sharp border between the labile more recent stage and the remote stage of long-term memory or perhaps of the ability to access those memories. The patient could not remember what happened during the episode. That is suggestive of mesial temporal lobe involvement, in this case left hippocampal region in dominant hemisphere. The ability to perform calculations and language functions was otherwise intact. This would suggest that lateral temporal areas were not involved. The electroencephalogram was normal and consistent with such a lack of involvement of the lateral aspects of the cerebral hemispheres. Occasionally, the EEG will demonstrate a minor focal involvement of the temporal lobe. More often, as in this case, the study is normal. CT scan and MRI when performed are usually unremarkable. SPECT scan might well indicate transient focal involvement as indicated above. The brain scan in this case did suggest a transient abnormality, which would be consistent with an area of ischemia/ infarction, which resolved over the succeeding months. Such an episode must be distinguished from episodes of amnesia, which may occur in relation to, and following a temporal lobe seizure.

The effects produced by electrical stimulation of the hippocampus may also occur as relatively selective ictal and postictal phenomena in a complex partial seizure originating in mesial temporal lobe structures as illustrated in case history 30-3 which follows. Focal temporal lobe seizure phenomena were followed by a period of impaired recent memory with an inability to record new memories.

Case 30-3: This 68-year-old, white male one year prior to valuation fell, striking his occiput and transiently losing consciousness. Except for a persistent defect in his sense of smell, the patient had no apparent neurological defects following this injury. Approximately six months later, the patient had the first of a series of recurrent episodes of amnesia. These episodes occurred most often on awakening. On some, but not all, occasions the episodes were preceded by a sensation of gastric upset, a strange odor and a sensation of familiarity (*déjà vu*). The episodes of total amnesia would last 30 to 60

minutes. There would then be an impairment of memory for approximately one to two days. The patient was said during the episode of total amnesia and during the subsequent episode, to behave in an otherwise normal and rational manner. For example, he would be able to converse with his wife and others. During the episodes, he was said to be unable to remember tasks, which his wife had asked him to do during that day. A significant impairment of retentive memory would be apparent to his wife and to others. His memory for more distant and remote events was also impaired to a variable but lesser degree. The patient would then regain memory progressively over the course of the next one to two days. Apparently, memory was not regained in any orderly pattern from recent to remote or vice versa. The patient at no time had any abnormal movements suggestive of a generalized convulsion.

No automatisms had been noted and to others the patient would appear fully conscious during the episodes.

Neurological examination:

1. *Mental Status*: The patient was oriented for time, place, and person. Delayed recall was intact. The patient could remember 4-out-of-5 objects in 5 minutes. Remote memory was intact. Digit span was slightly impaired at 6 numbers forward and 4 in reverse.

2. *Cranial Nerves*: All areas were intact with the exception of cranial nerve I where olfaction was decreased for the odor of coffee grounds, bilaterally.

3. *Motor system, reflexes and sensory system*: *Intact*.

Clinical diagnosis: 1) Complex partial seizures (most likely post traumatic) with episodes of amnesia as an ictal and or post ictal phenomena. 2) Post traumatic anosmia.

Laboratory data: 1. *Skull X-rays, routine EEG, radioactive brain scan, fasting blood sugar and glucose tolerance tests, pneumoencephalogram and spinal fluid examination were normal..*

2. *The EEG obtained after a period of sleep deprivation revealed occasional multifocal spikes during sleep in the right anterior temporal area and to a lesser degree the left frontal-anterior temporal area.*

Subsequent course: The patient was treated with anticonvulsant medication. The episodes continued to occur once per month but were now of shorter duration, lasting only 15 to 20 minutes. The impairment of memory was less marked and involved only the ability to learn new material without prolonged periods of retrograde amnesia. After 8 months no additional episodes occurred. When seen three years after initial evaluation his neurological examination was unremarkable except for the defect in olfaction suggesting that more serious progressive disorder was not present.

Comment: In this case the episodes experienced by the patient could have posed a diagnostic problem if the occasional warning symptoms of olfactory aura, déjà vu and epigastric sensation had not been present. Most of the episodes experienced by the patient were not preceded by these clear symptoms of temporal lobe seizure, but were instead simply episodes of amnesia. Though the actual temporal lobe seizures apparently lasted only a matter of 30 to 60 minutes, some degree of impairment of memory was present for one to two days following the episode.

The etiology of the seizures in this case must relate to the patient's preceding head trauma. The loss of olfactory sensation following the trauma suggested that this trauma was of sufficient nature to tear the nerve filaments passing through the cribriform plate to the olfactory bulb on the orbital surface of the frontal lobe. Such trauma does produce contusions of the orbital frontal cortex and epileptogenic foci may result. We may also assume that this trauma may have been sufficient to produce some minor contusion of the anterior poles, inferior and medial surfaces of the temporal lobes against the bony walls of the middle fossa with a resultant scar and epileptogenic focus. The fact that olfactory hallucinations and the experience of déjà vu preceded some of the amnesic episodes

would make the temporal origin more likely. The routine electroencephalogram is not reliable in the detection of seizure discharges in either the mesial temporal or the orbital frontal areas. The electroencephalogram showed significant areas of discharge in the temporal lobe only under conditions of sleep deprivation which acts to precipitate seizure discharges in individuals who have an underlying predisposition for seizure discharges. For additional discussion, see Gallassie, et al (1988), Hughlings-Jackson (1889), Tassinari, et al (1991).

The following case history presents an example of presenile dementia.

Case 30-4: This 64 year old right handed white male formerly an administrative assistant for the veteran's administration and newspaper distributor was initially evaluated for impairment of recent memory. Initially, the wife indicated this had been progressive over 4 years, but she was subsequently able to date this back to age 54 years, 10 years previously. A review of his record indicated that another neurologist of our department had seen him 4 years previously with similar memory complaints. The neurological examination at that time demonstrated no focal features, but his mental status examination indicated an inability to recall any of four objects. There were minor changes in time orientation: his date was off by one month and the day of the week was incorrectly stated. In the interim, the memory problems had progressed. In addition there were now personality changes. He no longer participated in those activities which had previously been of great interest. He was also having some problems in finding words. There were no problems in the activities of daily living and he was not getting lost in his familiar environments.

Family history: There was no history of neurological disease in his siblings or father. His mother had died at the relatively young age of 48 of cancer.

Neurological examination:

1. *Mental status:* The mini mental status exam indicated a total score of 19 out of 30. He had particular problems in time orientation. He was able to do the immediate recitation of three objects and of a test phrase but could remember none of these on a delayed recall test. He also had difficulty copying a test figure. The patient was often tangential in his answers and demonstrated inappropriate joking.

2. *Cranial nerves:* intact

3. *Motor system* was intact as regards strength, gait and cerebellar functions. However premotor /frontal lobe functions were abnormal. He had a release of the instinctive grasp reflex. He had difficulties performing the Luria three stage motor sequences demonstrated by the examiner (slap thigh with palmar surface, then with ulnar edge of hand and then with ulnar surface of closed fist.).

4. *Reflexes:* deep tendon stretch reflexes, and plantar responses were physiologic.

5. *Sensory system:* intact

Clinical diagnosis: Alzheimer's disease

Laboratory data:

1. All screening studies such as *complete blood count, sedimentation rate, B -12, folate, thyroid functions and serological test for syphilis* were normal.

2. *CT scan* demonstrated significant dilatation of the temporal horns. (This change in the size of the temporal horns suggested hippocampal atrophy.) In addition there was a general increase in lateral ventricular size. There was also blunting of the angles of the frontal horns.

3. *SPECT scan* was within normal limits except for a slight decrease in perfusion in the left parietal region.

Subsequent course: The patient was begun on treatment with 5mg per day of donepezil (Aricept) a centrally acting acetylcholinesterase inhibitor and high dosage of vitamin E (a possible antioxidant). When re-evaluated at one month, his family reported improvement in memory; the mini mental status exam score was now 21 out of 30. At 10 weeks into treatment, the score had increased to 25 out of 30. There was particular improvement in the delayed recall section of the exam. There was however no change in personality. He still showed inappropriate jocularity when he could not answer a question and at times was tangential in his answers. Administration of the acetylcholinesterase inhibitor temporarily improved memory function for approximately 18 months. However by age 67, behavioral disturbance (agitation, aggression nocturnal wandering and sexual disinhibition) and urinary incontinence were becoming major problems. He could no longer be managed in his home and day care setting despite the

use of haloperidol. This resulted in his placement in a nursing home. At age 69, he was now described as relatively nonfluent, and very confused. He recognized his own name and occasionally recognized relatives but showed no other response to questions. He was usually restricted to a wheel chair, could walk with assistance. He was “stiff and afraid” when requested to walk.

Comment: This patient presents a typical example of the slowly progressive course of Alzheimer’s disease. Memory problems had begun insidiously at approximately age 54. Initially these problems in the older adult may be attributed to a benign age related process in which there is minor difficulty in accessing information such as names although the ability to incorporate new information is still intact (“wait a minute, the name or word will come to me eventually”). When evaluated by a neurologist at age 60, the major finding was a severe deficit in delayed recall suggesting a process at the level of the hippocampus. The patient failed to return for follow up at that time and when he did reappear at age 64, he was now beginning to show changes in personality and frontal release signs suggesting involvement of the prefrontal and premotor areas. The use of a cholinesterase inhibitor produced some improvement in memory for about 18 months but had little effect on the changes in personality and behavior. The use of this agent has been estimated to postpone nursing home placement by approximately 15 months. Eventually by age 69, fifteen years after disease onset, gait and other motor functions were seriously affected.

The rationale for the use of cholinesterase inhibitors is based on the demonstration by Drachman and Leavitt (1974) that administration of scopolamine, an anticholinergic drug that crosses the blood brain barrier, would produce a transient syndrome similar in many respects to memory and cognitive changes of Alzheimer’s disease. Subsequent studies demonstrated a marked loss of neurons in the basal forebrain nucleus of Meynert, a major source of cholinergic fibers to the cerebral cortex. (Whitehouse et al 1981 Rogers et al, 1985 editorial of Growden 1992). However, a simplistic cholinergic hypothesis is insufficient to explain all of the features of Alzheimer’s disease. Administration of acetylcholine esterase inhibitors in mild cases (mini mental status score of 10-25) has only a limited value as in the present case. Other neuronal systems are involved (noradrenergic synapses are also involved. hippocampal system is severely involved).

The following case 30-5 provides an example of general paresis producing severe changes in cognitive function and personality.

Case 30-5 : This 59-year-old right-handed white male, cleaning establishment owner, five years prior to evaluation, manifested a personality change - increased rigidity and irritability. He would become enraged over trivial matters many times per day. During the last 1.5 years, this process accelerated. He became more antisocial, unable to interact with employees and customers. His level of comprehension declined. He became more aggressive towards his wife and children. He often manifested frank paranoia and suspiciousness, accusing his wife of unreal, sexual infidelity. During the last 1.5 years, a significant gait disturbance had also developed, with impairment of balance. A slowing in speech and a tremor of hands had developed over the previous year.

The patient had been born in Poland. All significant infections were denied. He had received injections of “liver” and B12 after the war “for anemia” but had received no recent B12 injections.

Neurological examination:

1. *Mental status:* The patient was oriented for time, place and person.

Delayed recall was markedly impaired none of five in five minutes without assistance, one of five with assistance. Repetitions and naming of objects were intact. Distant (remote) memory was good. The patient could list all major world leaders during World War II and all assassination attempts.

The patient was often tangential in his responses and often initiated irrelevant conversations.

Serial 7 subtractions could not be done but the patient could reverse 12 months of the year.

Abstract reasoning for similarities was poor.

He often got up from the bed and looked outside the curtain, checking the activities of his roommate.

2. *Cranial nerves:* Pupils were small, 2 mm., and irregular but did respond to light.

Twitching and grimacing of face, eyelids and tongue occurred. He also had a lid lag.

3. *Motor system*: Strength was intact. Gait was wide-based, with a positive Romberg test. The patient was quite tremulous with occasional myoclonic jerks. He could not do rapid alternating movements.

4. *Reflexes*: Deep tendon reflexes were normal (2+) in the upper extremities, trace at patellar and absent at Achilles. Plantar responses were flexor, bilaterally. There was no release of the grasp reflex. Other frontal release signs were absent.

5. *Sensory system*: Pain, touch and position sense intact. Vibration was markedly decreased at toes, and ankle with minor preservation at knees.

Clinical diagnosis: Progressive dementia and personality change. Multiple entities to be considered including (1) the combination general paresis and tabes dorsalis, (2) B12 deficiency, (3) frontal lobe tumor, (4) frontal dementia and (5) Lewy body dementia

Laboratory data: The abnormal findings included:

1. *Vitamin B12 level* was borderline low at 209 picograms/ml., *Schilling test*, however, demonstrated normal absorption (25.4% excretion of radioactive B12 in urine).

2. Serum serological test for syphilis (RPR) was reactive with the more specific FTA markedly reactive.

3. *Cerebrospinal fluid*: 98 white cells were present - all lymphocytes. CSF protein was elevated to 116 mgs.% (normal <45 mgs.%). Sugar was low at 44 mgs.% with a simultaneous blood sugar of 90. Spinal fluid serological test for syphilis (VDRL) was positive.

4. *CT scan* showed mild frontal and temporal atrophy

Subsequent course: The patient was hospitalized for two weeks and received high dosage intravenous penicillin therapy, three million units every four hours for 10 days (18 million units per day).

When seen again 2 months later, the patient and his family reported that gait and coordination had significantly improved. Memory and personality had not improved. He still had episodes of agitation and irritability. Reflex and sensory findings were unchanged. The patient had been inconsistent in taking any medication such as haloperidol, aimed at altering his agitation.

He failed to return again for 18 months. Paranoid ideation had become more prominent. He could no longer manage his fiscal affairs. Orientation and delayed recall were intact. There was minor tremor of the hands and an unsteadiness of gait. Romberg was positive although position and vibratory sensation were intact. Serum serology was now negative. Lumbar puncture now indicated no significant cells, a normal protein.

Subsequently he did require hospitalization for renal failure secondary to enlarged prostate and a neurogenic bladder. Spinal fluid VDRL and serum RPR serological tests for syphilis, were both nonreactive. Serum FTA ABS - a much more specific and more sensitive test for previous syphilis was still 3+ reactive.

Telephone follow-up 11 years after the initial episode indicated that personality and cognitive changes had essentially leveled off, irritability and hostility were less. He had no urinary problems. He was unsteady in walking, but was still able to drive small distances and was living at home. Additional information approximately 20 years after the initial evaluation indicated that he spoke very little, he no longer demonstrated agitation. His mobility was more limited. Of interest, one pupil no longer responded to light but did respond to accommodation. CT scan demonstrated greater atrophy.

Comment: This patient had clinical manifestations predominantly related to general paresis. Both the history and the examination also provided evidence of tabes dorsalis. Penicillin therapy resulted in a non-active state, as regards serum serology and any cellular activity in the spinal fluid. However, the damage to cerebral cortex was not reversed and continued to provide a significant problem, as regards personality function. Thus, once cognitive function has been altered, due to damage to and loss of neurons, the changes in memory and personality may be persistent. Disturbances of frontal lobe and limbic system function once initiated may continue to evolve.

Moreover once the patient reaches the late 60's and the 70's, apparent progression of neurological changes in memory and other cognitive functions may occur related to the combined effects of the previous acquired lesions of general paresis and the effects of even mild Alzheimer's disease. A double hit has occurred.

The following case provides an example of a patient whose initial symptoms related primarily to a severe alteration in personality function and social interactions. Features of Parkinson's disease were apparent on her examination. Diagnosis was uncertain but diffuse Lewy body dementia should be considered.

Case 30-6: This 60-year old, right handed separated white housewife, residing in a nursing home, was referred for evaluation of problems in walking, progressive behavioral change and memory disturbance. Six years previously at age 54, a change in behavior was first noted by her family. She began to accumulate papers about the house. She would leave the shades down all day, and expressed fears that people would break into her house. As a result, she became isolated from her neighbors and friends. Shortly thereafter, she made repeated phone calls to the local police and it was apparent that she was confused. After investigation, the police had to break into the house and take her to an emergency room. In the emergency room she was described as confused and frightened. Paranoid ideation was prominent with considerable self-referral ideation. Thought process was described as tangential, with considerable perseveration. There was poor insight and judgment was impaired. She was confused as to time and place and she could recall two of three objects in 5 minutes. She had great difficulty with serial sevens, often losing track of the number to be subtracted. Judgment and insight were poor. She would read a book by rapidly turning the pages, but then had little recall of what she had read. With treatment with haloperidol, lability of mood and paranoia decreased. A CT Scan demonstrated "mild cortical atrophy". The patient was then transferred to a nursing home with a diagnosis of Alzheimer's Disease. In retrospect, a gait problem had also been present in January 1984, about the time that her symptoms had begun, and prior to the use of haloperidol. The patient was walking flexed with small steps. These gait problems progressed so that she was unable to stand up from a chair and was unable to walk. She had become fearful of walking.

Family History - Indicated parents died at ages 70-80 years, without neurological disease. A sibling was age 79 without neurological disease.

Neurological examination:

1. *General:* A thin female appearing older than her stated age. She sat in a wheelchair with little facial expression and with little body movement. She was passive in the interview situation -allowing her husband to provide many answers.

2. *Mental Status:* She was oriented to the year but when requested to provide the month and day, she answered "it is the beginning of school time". As regards the location, she gave the name of the town where she formerly lived but could not name the town where the nursing home was located. She did name the nursing home and then said "its a jazzy place with more facilities, most of the people there are nice, some just sit around".

Asked to describe herself, she said, "I am nothing, I can't even take care of my child". She was, however, able to provide the name of her only daughter, now grown, and was able to indicate that the daughter had been born in 1945 in Philadelphia (all of which the husband verified as correct).

Asked to indicate her own birthplace and birth date, she indicated she herself had been born at home in Fitchburg in 1925 and then added, "I imagine everything has been tossed out there". When I asked "what had been tossed out?", she provided a tangential answer, "I do not know you" and then rambled on to a conversation topic about her husband's trip to Turkey on a "Fulbright" - some time in 1960 or 1970.

Delayed recall even with multiple choice assistance was zero out of five in five minutes. For serial seven subtractions, 100 - 7 "might equal 86 or might equal 55". She could name 3 out of 5 objects, could do repetitions, could write her name but not her address and refused to draw a house (? unwilling, ? unable).

3. *Cranial Nerves:* Intact except for a tremor of the closed eyelids and a positive glabellar sign. There was a lack of facial expression.

4. *Motor System*: Strength was difficult to assess, but appeared intact when maximal effort was made. Significant akinesia and bradykinesia were present. There was cogwheel rigidity of minor degree at wrist and elbow. There was variable resistance at hip and knee, which had primarily the character of frontal lobe type "Gegenhalten".
The patient had to be assisted to the standing position from her wheelchair. In the standing position, initially, her feet appeared to be stuck to the floor, as in a magnetic foot syndrome. Eventually, she was able to take small shuffling steps, as assistance was provided by holding her outstretched hands lightly. If unsupported, she tended to fall backwards - whether standing or walking.
 5. *Reflexes*: Deep tendon reflexes were physiologic at 2+ except for Achilles - 1+. Plantar responses were equivocal. There was marked release of the grasp reflex.
 5. *Sensory system*: Pain and vibration were intact. Position sense could not be tested.
- Clinical diagnosis:** Lewy body dementia , or a variant of frontal dementia.

Laboratory data:

1. *Metabolic surveys* were not remarkable in terms of electrolytes, BUN, creatinine, glucose, hepatic functions, vitamin B12, folate levels and thyroid functions.
2. Routine serum serological test and FTA absorption for syphilis were negative.
3. *Sedimentation rate* was moderately increased to 53 mm/hr. *Alkaline phosphatase* was elevated to 272 and bone scan suggested possible Paget's Disease.
4. *EEG* demonstrated a slow dominant awake activity of 6-7 Hz (compared to normal alpha rhythm of 8-13 Hz). In addition, rhythmic bilateral delta slow wave were present, most prominent in the frontal recording areas.
5. *CT Scan*, demonstrated marked cortical atrophy with enlargement of sulci, ventricular system and cisternal spaces.

Subsequent course:

The patient continue a slowly progressive course to the present time. According to her primary physician, she is essentially restricted to bed. She remains, from a medical standpoint, relatively clear of other medical problems and complications - at age 67, 13 years after onset of the disease.

Comment: The diagnosis in this case is uncertain . The patient at age 54 had the onset of a significant change in behavior which resulted in major problems in interpersonal relationships. Initially, she had been able to live by herself in her small seaside community. Eventually, however, the frequent night calls to friend, neighbors, and the police, resulted in her coming to medical attention. Even at that point, the patient's separated husband, who visited her frequently and supported her, appeared unaware of the patient's confusion and memory deficit. The husband had considerable difficulty appreciating the degree of disability. Such a pattern is not unusual.

In contrast to the previous case histories of this chapter, the memory problems were far beyond the selective involvement of recent memory seen in Wernicke's or hippocampal lesions. Moreover, a more diffuse involvement of other cognitive functions was present. As the disease progresses, motor aspects become prominent, indicating the effects of involvement of frontal and premotor areas. Mild "Parkinsonian" features may appear, due to either the medications employed (neuroleptic agents such as pheno thiazides, haloperidol, etc.) or to alterations in the frontal premotor basal, nuclei circuits or to loss of neurons, at the level of S. nigra or basal nuclei. Note however that the gait problems occurred prior to the use of haloperidol. The CT scan did not demonstrate the focal atrophy seen in frontotemporal dementia .Therefore the most likely diagnosis might be diffuse Lewy body dementia since personality changes were most prominent at onset, and Parkinsonian features developed early in the disease course. Contrast this case to the Alzheimer disease patient of case 30-4 in which the initial problems were restricted to changes in memory.

When seen at age 60 this patient was clearly late in her disease course. As indicated, remedial causes of the syndrome of progressive dementia must be ruled out. The effects of medication must be considered. Moreover, however, any masking depression should be treated. At this point in time, no specific therapy to reverse the progressive course of the disease is known.

Case 30-7: This 74-year-old right-handed widow presented to the emergency room at St Vincent hospital on 2-19-02 with an 8-10 week history of worsening memory problems. In December 2001, accompanied by her boyfriend she made her annual trip to Florida. Although she had been in her usual state of independent living prior to her departure, she was found to have serious problems with

memory on arrival. She was unaware as to where she was. In a telephone conversation with her daughter, “she was talking nonsense”. During the next 2 months, memory and word finding continued to deteriorate. She was taken to the emergency room of the local hospital in Florida where a CT scan without contrast on 02/07/02 demonstrated mild cortical atrophy but no acute process. Her son drove to Florida and found that her memory was poor and her conversation did not make sense. “My husband is in the service: my mother died last year.” However she could play cards with her grand daughter. Her gait was slow and stooped. She had urinary incontinence on her way to the bathroom.

She had no history of alcoholism and took various vitamins and herbs.

Family history: her brother had died of a brain tumor of unknown type.

Neurologic examination: The positive findings were the following:

1. *Mental status:* The patient was awake and alert. Overall Mini-Mental Status Score was 19/30. The major problems were in orientation and in delayed recall. She was able to indicate that she was in a hospital in Massachusetts. And the date was February. She registered 3 objects but could recall any in 3 minutes. She was however able to read, name objects, follow instructions, spell “world” backwards and copy a figure. She was unable to draw a clock with the hands set at 11:10.

2. *Cranial nerves:* intact

3. *Motor system:* Although strength and tone were normal, her gait was broad-based and shuffling.

4. *Reflexes:* Patellar and Achilles reflexes were absent but plantar responses were flexor.

5. *Sensory system:* Intact.

Clinical diagnosis: 1) Subacute dementia: etiology uncertain possibly of Alzheimer’s or Lewy body type. Various entities such as chronic subdurals, tumor etc to be ruled out 2) Peripheral neuropathy, most likely etiology at this age diabetes mellitus.

Laboratory data:

1. *Basic CBC and chemistries:* Normal except for an elevated fasting glucose.

2. *CT scan (Fig 30-10):* An enhancing 2.75 cm tumor with a necrotic center was present in the thalamus at the level of the upper third ventricle. There was bilateral involvement of the anterior and medial thalamus but with no involvement of the posterior thalamus or hypothalamus. The study suggested a lymphoma or glioblastoma

Subsequent course *Stereotaxic biopsy of the right thalamus:* Frozen section raised the question of a lymphoma or glioblastoma but special immunological stains were consistent with a glioblastoma. Necrosis and endothelial hyperplasia were present. The patient was treated with dexamethasone and radiotherapy with improvement in gait.

Comment: This patient presents an unusual cause of a progressive alteration in memory. As indicated earlier in this chapter those patients with Wernicke’s encephalopathy who progress to the Korsakoff syndrome had persistent pathology in the medial and anterior thalamus with sparing of the posterior thalamus. In this case the pathology was a rapidly progressive glioblastoma multiforme. As discussed above, an occasional patients, glioblastomas may also produce dementia and a change in personality by infiltrating the prefrontal areas and corpus callosum. Occasionally a patient with a more diffuse neoplasm gliomatosis cerebri may also present with a similar syndrome of dementia which may mimic Alzheimer’s disease. These are however rare causes compared to the more frequent degenerative disorders.

COMPLETE CASE HISTORIES FROM TEXTBOOK: *INTEGRATED NEUROSCIENCES*
PART IV. CASES; CEREBRUM VISION, DISEASES, MEMORY

CHAPTER 23: VISUAL SYSTEM

The following case is an example of a lesion involving the optic nerve, anterior to the optic chiasm.

Case History 23-1 (Fig 23-8).

This 53-year-old white right-handed housewife was referred for evaluation of progressive right-sided supraorbital headache of 23 years duration and decreasing acuity in the right eye. The loss of acuity had progressed to the point of almost total unilateral blindness. During the 3 years before admission, intermittent tingling paresthesia had been noted in the left face, arm, or leg. About 1 year before admission the patient had a sudden loss of consciousness and was amnesic for the events of the next 48 hours. She was hospitalized, but no explanation for the episode was clearly established, although cerebrospinal fluid protein was reported to be elevated (230 mg/dl).

The patient and her family reported some personality changes over a period of several years, including a loss of spontaneity and increasing apathy.

General Physical Examination: Unremarkable except for a minor degree of proptosis (downward protrusion of the right eye).

Neurologic Examination:

1. *Mental Status*: The patient was, in general, alert but at times would become lethargic. Her affect was flat. At times, she would laugh or joke in an inappropriate manner.
2. *Cranial Nerves*: There was anosmia for odors, such as cloves, on the right and a reduced sensitivity on the left.

Marked papilledema (increased intracranial pressure with protrusion of the optic disk and venous engorgement due to obstruction of the normal flow of CSF) was present in the left eye.

Pallor of the right optic disc was present, indicating optic atrophy. Visual acuity in the right eye was markedly reduced. The patient had only a small crescent of vision in the temporal field of the right eye, where only vague outlines of objects could be seen. A slight left central facial weakness was present.

3. *Motor Systems*: Intact although movements on the left side were slow.

4. *Reflexes*: A release of grasp reflex was present on the left side.

5. *Sensory system*: Intact

Clinical diagnosis: Subfrontal meningioma arising from olfactory groove or inner third sphenoid wing.

Laboratory data:

1. *Skull x-rays* demonstrated erosion of the dorsum sellae. Special lamniograms demonstrated hyperostosis of the sphenoid bone (planum sphenoidale) suggesting a meningioma originating from the sphenoid bone.

2. *EEG* demonstrated focal 2-4 Hz slow waves in the right anterior temporal and anterior lateral frontal area.

3. *Brain scan (Hg 197)* revealed a heavy uptake of isotope in the right posterior subfrontal area.

4. *Arteriograms* indicated that the anterior cerebral arteries were shifted backwards, posteriorly and the left. A tumor blush was present on the venous phase in the right subfrontal area extending back to the optic nerve groove (Fig 23-8). These findings were felt to be most consistent with an olfactory groove meningioma.

Hospital course: Dr. Samuel Brendler performed a bifrontal craniotomy which exposed a well-encapsulated smooth tumor attached to the medial third of the sphenoid wing. After intracapsular removal of 90 to 95% of the tumor, the right optic nerve could be visualized. The small portion of the tumor attached to the bone could not be removed because of considerable bleeding from the bone. Examination 4 months after surgery, indicated right anosmia and right optic atrophy were present.

Comment

If one considered only the patient's primary complaint, decreasing vision in the right eye, and the findings of right optic atrophy and left-sided papilledema (Foster-Kennedy syndrome), then the most probable diagnosis was inner-third sphenoid meningioma. The preservation of a small crescent of vision in the temporal field is consistent with compression of the optic nerve on its lateral surface. By the time of hospitalization, the lesion was quite large and had extended into the subfrontal area, producing anosmia on the right and some changes in personality. At this point, the various diagnostic studies suggested only a subfrontal mass and did not clearly differentiate between an olfactory-groove meningioma and a sphenoid-wing meningioma. One might suggest, in retrospect, that the degree of involvement of the right optic nerve was much more pronounced than the changes in prefrontal functions, and therefore, the inner-third sphenoid-wing location was more likely.

The surgical approach in any case was the same. The eventual recovery of vision in such cases is uncertain because the effects of compression often are not reversible.

The following case 23-2 provides an example of a macroadenoma of the pituitary producing a bitemporal adenoma..

Case 23-2. Patient of Dr. Martha Fehr. This 45-year-old man had an 18-month history of a progressive alteration in vision. He was unable to see objects in the right or left periphery of vision. He was concerned that in the process of driving he might hit pedestrians stepping off the sidewalks in the periphery of vision. He had also experienced over 6-8 months, progressive headaches, loss of energy and libido.

Neurological examination: Normal except for a bitemporal hemianopia.

Clinical diagnosis: Pituitary adenoma compressing the optic chiasm.

Laboratory data:

1. *Endocrine studies:* all were normal including prolactin, am cortisol, and thyroid functions.

2. *MRI:* A large macroadenoma measuring 3 cm in diameter extended outside of the sella turcica to compress the optic chiasm (fig. 23-11).

Subsequent course: Dr. Gerald McGuillicuddy performed a gross total trans sphenoidal resection of the tumor, with a significant improvement in vision. Three years later, the patient again had visual symptoms and eye pain. MRI scans indicated regrowth of tumor with possible impression on the right optic nerve. He was treated with radiotherapy.

Comment: Note that males are more likely to present with large pituitary adenoma compressing the optic chiasm. Women are more likely to present with microadenomas or small macroadenomas since they are more likely to be seen at an earlier stage due to an initial complaint of amenorrhea. Thus complaints of decreased libido in men are likely to be mentioned only in retrospect and not as an early presenting complaint.

The following case illustrates the effects of a space-occupying lesion in the occipital lobe. One should compare these findings to those reported earlier in Case 23-1, in which there was a lesion in the visual system anterior to the optic chiasm.

Case 23-3: This 47-year-old white, right-handed, real estate salesman was referred for evaluation of headache and visual disturbance. One month before admission the patient had a cough with some blood present in the sputum (hemoptysis). Five days before admission the patient developed a generalized headache, which was

precipitated by coughing or straining and which awakened him or prevented him from sleeping.

Two days before admission, the patient noted blurring in the left inferior quadrant of his field of vision.

The day before admission, he noted complete loss of vision in this quadrant. On the day of admission, the headache increased, and the patient was unable to see anything in the left visual field.

He had experienced no weakness, no disturbance of memory, and no language disturbance.

Past history was significant. The patient had multiple pulmonary infections, treated with antibiotics.

Neurologic examination:

1. Mental status: Intact

2. *Cranial nerves* were intact, except that blurring of disc margins was present bilaterally, with venous engorgement, indicating early papilledema.

A left non congruous homonymous hemianopia was present (Fig. 23-14A).

3. Motor system: Intact

4. **Reflexes:** *Deep tendon reflexes were slightly more active on the left. The plantar response on the left was extensor that on the right was flexor*

Laboratory data:

1. *Electroencephalogram* was abnormal because of frequent focal 3 to 4 cps, slow waves in the right occipital area and to a lesser degree, in the right posterior parietal area, consistent with focal damage in the right occipital area.

2. *Cerebrospinal fluid* pressure was elevated to 210 mm H₂O. The number of white blood cells was increased to 97 lymphocytes (upper normal limit is 5 to 7 lymphocytes). Protein was increased to 75 mg/dl (upper normal limit is 45 mg/dl). Glucose was 75 mg/dl (normal when compared to blood sugar of 95 mg/dl).

3. *Imaging* (radioactive brain scan Hg 197) demonstrated an enhanced region in the posterior and medial aspect of the right hemisphere (occipital and adjacent parietal lobes).

Subsequent course: The patient was treated with antibiotics (cephalothin sodium, penicillin, and streptomycin). Visual fields, EEG, and spinal fluid findings improved. Within 3 weeks the field defect had resolved to a non congruous left inferior quadrantanopia (Fig. 23-14B).

Ten days later the patient was readmitted to the hospital with a three-day history of right eye pain, sweats, and chills. Neurologic examination now revealed a recurrence of blurred optic-disc margins, a left homonymous hemianopia and a slight increase in deep tendon reflexes on the left. Imaging studies now revealed a large space-occupying lesion in the right parietal/occipital region, displacing the right lateral ventricle forward and downward.

After 10 days treatment with antibiotics (penicillin and streptomycin), a craniotomy was performed by Dr. Bertram Selverstone. A mass could be palpated medially in the right occipital and adjacent posterior parietal area. The abscess and a large surrounding area of hard granulomatous cortex and white matter were removed. (The etiologic organism was subsequently found to be a *microaerophilic streptococcus*.)

Postoperatively, the patient continued on treatment with penicillin. Follow-up examination 6 months after surgery was normal, except for the left homonymous hemianopia (Fig. 23-14C).

Comment: The rapid evolution of neurologic signs and symptoms in this case; the early development of papilledema, and the progressive changes in the electroencephalogram and brain scan; is consistent with the diagnosis of brain abscess. The primary infection in this case was probably in the lung.

The initial visual symptoms of inferior field involvement (quadrantanopia) suggested that the abscess, in its early stages, involved predominantly the superior portion of the optic radiation in the posterior parietal/occipital area or the superior bank of the calcarine fissure. With progression of the lesion, the entire optic radiation or the entire calcarine cortex was involved. The lesion found at surgery had destroyed or damaged both these areas.

The treatment of a brain abscess requires appropriate pre- and postoperative use of antibiotics. Many of these patients develop focal seizures at some time after successful surgical treatment of the abscess. Although prophylactic anticonvulsant medication, such as diphenylhydantoin (Dilantin), has been routinely administered, the value of such treatment remains unclear.

Note an important negative finding in this case: at no time did the patient experience any language disturbance. Reading and writing remained intact, as did the capacity for to construct drawings. This case involving the right occipital lobe should be compared with Case History 21-2, in which a focal lesion of the left occipital lobe was present.

The following is another example of the effects of a lesion in the occipital lobe with very different consequences than those seen in the previous case. The lesion clearly involved the cerebral cortex producing focal seizure activity.

Case 23-4. (Fig 23-15): This 18-year-old left-handed single white female restaurant employee was referred for reevaluation of a seizure disorder. While living in the south western United States, the patient had the onset of her seizures at age 14 when she had a sequence of five seizures in less than 12 hours. Each began with flashing lights, “like Christmas tree lights,” all over her visual field, plus the sensation that peoples’ faces were moving. She then would have an apparent grand mal seizure. She was hospitalized. The neurological examination was reported as normal. An electroencephalogram report noted occasional focal sharp and slow waves in the left hemisphere. The CT scan was interpreted as essentially within normal limits. In retrospect, there was a question of some mottled hypodensity in the left occipital area, not clearly distinguished from artifact. The patient was treated with carbamazepine (Tegretol), 400 mg in the morning, and 230 mg at hour of sleep. In the interim, she apparently had done quite well with no additional grand mal seizures. She had rare episodes of “fear attacks,” which would last 23 to 25 minutes. The last attack had occurred 2 years ago, but as recently as two months ago, she had had one episode of flashing lights. A recent EEG was normal.

Past history was negative, except her birth weight was ten pounds, three ounces, and there was a problem of breathing at birth. She had always done poorly in school. Her family history did not suggest possible causes for a seizure disorder.

Neurologic examination: Normal.

Clinical diagnosis: Seizures of focal origin occipital cortex, (flashing lights and movement of the lights) probably left hemisphere based on the reports received of the EEG. There was subsequent spread of discharge into the temporal lobe based on the report of “fear attacks”

Subsequent course

The patient did well for 3 years then had a recurrence of a generalized convulsive seizure possibly related to omission of medication. Six weeks later, she reported two additional episodes characterized by flashing lights, then movement of the lights away from a center circle, then dizziness, then a

sensation of unreality. She also had other episodes of feeling unreal accompanied by fear. There were no olfactory hallucinations and no other visual or auditory hallucinations. The neurologic examination now demonstrated a minor right central facial weakness not present previously.

Laboratory data:

1. *EEG*: remained normal.
2. *MRI scan*: now revealed a small tumor at the left occipital pole with surrounding edema (Fig. 23-15). On CT scan, this tumor appeared partially calcified but did show enhancement. Angiograms suggested tumor vascularity of a type seen with meningiomas.

Subsequent course: Dr. Bernard Stone removed a discrete encapsulated tumor that appeared to be a meningioma. Subsequent microscopic examination, however, indicated a rare type of indolent follicular adenocarcinoma of the thyroid, which sometimes spreads as a single lesion to brain and remains quiescent for many years. In the postoperative period, a non-congruous right-inferior-field defect was present (partial quadrantanopia). The blood level of thyroid-stimulating hormone (TSH) was elevated. A thyroid nodule was found. A thyroidectomy was performed, and thyroid replacement medication was prescribed. No additional seizures were observed over the next 18 months. A metastatic lesion in the lumbar vertebral body subsequently appeared.

Comment: This patient presented many of the features of focal seizures arising in the occipital cortex: flashing lights, movement of objects and secondary generalization. Some of the seizure phenomenology such as “fear attacks,” dizziness, and “feeling unreal” suggested that spread into the temporal lobe was sometimes occurring. The student should now compare and contrast the cases presented in the previous chapter on the limbic system to this case to be able to note the differences seen after lesions in these adjoining cortical regions.

CHAPTER 24: SPEECH, LANGUAGE FUNCTION, APHASIAS, AGNOSIAS, APRAXIA

The following case, 24-1 presents an example of a selective non fluent aphasia of aphasia. An embolus to the superior division of the left middle cerebral artery produced marked weakness of the face tongue and distal right upper extremity and a severe selective nonfluent aphasia. The

hand weakness rapidly disappeared, the right central facial weakness, an apraxia of tongue movements and some expressive difficulties persisted.

Case 24-1: This 55-year-old, right-handed white housewife while working in her garden at 10:00 a.m. on 04-15-69, the day of admission suddenly developed a weakness of her right side and was unable to speak. Apparently, the right-sided weakness affected predominantly the face and arm since the patient was able to walk. The past history was significant. In 1960, nine years previously, the patient had been admitted to the hospital with a three-year history of progressive congestive heart failure secondary to rheumatic heart disease (mitral stenosis with atrial fibrillation). An open cardiectomy was performed with a mitral valvuloplasty (the valve opening was enlarged). A thrombus found in the left atrial appendage was also removed. Postoperatively, the patient was given an anticoagulant, bishydroxycoumarin (Dicumarol). Although atrial fibrillation continued, she did well until the day of admission. Prothrombin time at the time of admission was close to normal; that is, the patient was not in a therapeutic range for anticoagulation.

General physical examination: Blood pressure was moderately elevated to 170/80. Pulse was 110 and irregular (atrial fibrillation). Examination of the heart revealed the findings of mitral stenosis: a loud first sound, a diastolic rumble and an opening snap at the apex as well as the atrial fibrillation.

Neurological examination:

1. Mental status and language function:
 - a. The patient was alert.
 - b. She had no spontaneous speech and could not use speech to answer questions and could not even use yes or no to provide answers. She could not repeat words.
 - c. The patient was, however, able to indicate answers to questions by nodding (yes) or shaking her head (no), if questions were posed in a multiple choice situation. In this manner it was possible to determine that she was grossly oriented for time, place and person.
 - d. The patient was able to carry out spoken commands and simple written commands, such as, "hold up your hand, close your eyes." However, she had significant difficulty in performing voluntary tongue movements (such as "wiggle your tongue"; "stick out your tongue") on command.
2. Cranial nerves:
 - a. The patient tended to neglect stimuli in the right visual field.
 - b. She was unable to look to the right on command although the head and eyes were not grossly deviated to the left at rest.
 - c. A marked right supranuclear (central) type facial weakness was present.
 - d. The patient had difficulty in tongue protrusion. When the tongue was protruded it deviated to the right. The patient was unable to wiggle the tongue.
3. *Motor system:* Strength: there was a marked weakness without spasticity in the right upper extremity, most prominent distally. Some shoulder movements were possible; no hand or finger movements could be made. There was a minor degree of weakness involving the right lower extremity (75 percent of normal).
4. Reflexes:
 - a. Deep tendon stretch reflexes were increased on the right in the arm and leg.
 - b. Plantar responses were both extensors; more prominent on the right.
 - c. The abdominal reflex was absent on the right; present on the left.
5. Sensory:
 - a. Pain, touch and vibration were intact.
 - b. It was difficult to test other modalities but tactile localization appeared to be intact.

Clinical diagnosis: Embolus from heart to left middle cerebral artery

Laboratory data:

1. *Skull X-rays* were normal.
2. *EEG* was normal (48 hours after admission).
3. Cerebrospinal fluid was normal.
4. *Electrocardiogram* revealed atrial fibrillation

Hospital course: Within 24 hours a significant return of strength in the right hand had occurred; independent finger movements could be made. Within 48 hours after admission the patient was able to

repeat single words but still had almost no spontaneous speech. She appeared aware of her speech disability and would manifest some frustration. She was able to carry out two- or three-stage commands although tongue movements and perseveration remained a problem. Within 6 days of admission the patient used words, phrases and occasional short sentences spontaneously. She was better able to repeat short sentences. At this time strength in the right arm had returned to normal, but a right central facial weakness was still present. More detailed language evaluation two weeks after admission indicated the persistence of expressive disabilities consisting of word-finding and apraxic components. The apraxic components were evident on tongue placement and alternating tongue movements. Although complete sentences were used, sentence formulation in spontaneous speech was slow and labored with word finding difficulties. Repetition was better performed. In reading sentences aloud, substitutions or word omissions were made. The patient did well in naming common pictures and in matching printed words to spoken words or printed words to pictures. She could write from dictation and would often respond preferentially in writing when difficulty in speaking was encountered. No left-right confusion was present. Minor difficulties with simple arithmetic were reported. A right central facial weakness was still present.

Comment: There would appear little doubt that this patient had the sudden passage of an embolus (presumably from the left atrial appendage) into the left middle cerebral artery. In view of the selective face and arm weakness with a predominant expressive aphasia, the involved vessels must have been cortical branches such as the prerolandic and rolandic originating from the superior division of the middle cerebral artery. From the onset, it was clear that although some receptive components might be present, these were minor. The major problem was a severe nonfluent aphasia. As the hand weakness disappeared, the only other residual neurological findings were those of a right central facial weakness and an apraxia of tongue movements. Such findings would, of course, be consistent with a relatively selective involvement of Broca's area in the inferior frontal gyrus.

Why did such a rapid improvement occur in motor function and of the visual field? Most likely, the embolus fragmented and passed into the cortical branches supplying Broca's area.

With the passage of time, this type of patient would continue to show some degree of improvement (Mohr, 1973). Improvement could continue to occur over a two-year period. Although lesions of Broca's area may produce the acute onset of a nonfluent aphasia, rapid amelioration of the deficit occurs even when the acute lesion involves underlying white matter, as well as the superficial cortex.

In the following case 24-2, a more persistent anterior aphasia is demonstrated.

Case 24-2: On May 30, 1985, at midday, this 37-year-old right-handed woman with a past history of rheumatic fever, rheumatic heart disease and "an irregular pulse"(atrial fibrillation) had the sudden onset of loss of speech, central weakness of right face, an inability to protrude the tongue and a right hemiparesis. Although hemiparesis, face and tongue problems disappeared within a week, recovery of speech was slower and limited. At one week, she could produce some two syllable words.

Neurological examination at 17 months revealed the following residual findings:

1. *Language function:* Spontaneous speech was slow and relatively scanty. She could name objects slowly without difficulty, could do some simple repetitions and could write from dictation. She could carry out two and three stage commands. She could read slowly aloud but had little comprehension of what she read.
2. *Reflexes:* A residual right Babinski sign and right-sided hyperreflexia were present.

Clinical diagnosis: Anterior aphasia: embolic infarct of superior division of middle cerebral artery.

Laboratory data:

Although initial CT scans in May 1985 had been reported as negative; the MRIs in November 1986 and June 1990 demonstrated the infarct which included Broca's area, as well as adjacent frontal areas with predominant involvement of frontal operculum (inferior frontal gyrus) and adjacent middle frontal gyrus. In addition, a minor independent infarct was present in right occipital area (presumably embolic to the calcarine artery).

Subsequent course: Similar findings were present at 5 years, June 1990).

A brain section from a patient (Case 24-3) with a persistent nonfluent aphasia (is presented in Figure 24-4.

Case 24-3: This 69-year-old, right-handed male expired in 1965. In 1961 and 1963, The patient, had experienced transient episodes of right hemiparesis and aphasia, both followed by complete recovery. In 1964, a more persistent right hemiparesis and aphasia had developed.

General physical examination: No left carotid pulsation was present.

Neurologic examination(1965):

1. **Language functions:** Speech was nonfluent with only a small verbal output. A significant nominal aphasia with paraphasias was present. Reading was limited. Comprehension of spoken language was good. A marked apraxia was present for movements of tongue, lips and hands.
2. **Motor system:** Right hemiparesis with associated reflex findings.
Post mortem findings: Left carotid occlusion with old infarction, predominantly of left middle cerebral territory with lesser involvement of anterior cerebral territory. Note that minor cortical infarcts are also present involving cortex of right hemisphere.
(Courtesy of Dr. John Hills,; and Dr. Jose Segarra.)

Case 24-4 provides an example of a patient with a Wernicke's type aphasia

Case 24-4: This 40-year-old, right-handed white male had experienced a series of myocardial infarctions beginning 10 months prior to consultation. Angiographic studies indicated occlusion of the right coronary artery and the left anterior descending coronary artery with stenosis of the circumflex artery. The patient was subsequently admitted and a coronary artery bypass procedure was performed using extracorporeal circulation. Although the patient was stated to have tolerated the procedure well, the anesthetist noted that the patient was nonreactive 15minutes after the last administration of halothane anesthesia. When the patient did wake up, he was quite agitated requiring the use of agents to reduce agitation. Throughout the postoperative period, the patient continued in a disoriented and combative manner. Because of the patient's acutely psychotic state, transfer to the psychiatry service was actively planned. Because there were certain organic features to the patient's illness, a neurological consultation was obtained. The neurology resident in reviewing the progress notes discovered a notation that shortly after surgery the patient had transient difficulty in using his right arm.

Neurological examination:

1. **Mental status:**
 - a. The patient was an alert but agitated white male. Additional inquiries indicated that his agitation related to his inability to write a letter to his mother.
 - b. The patient's speech was fluent and usually grammatical. He made use of many paraphasias and neologisms (nonsense words). He often appeared unaware of his errors.
 - c. The patient was unable to name single objects such as pencil, cup, and spoon though he could recognize and demonstrate their use.
 - d. The patient could read occasional individual words; for example, cat, house. He could not comprehend or carry out, either spoken or written commands.
 - e. His attempts at spontaneous writing produced only a few letters. He was unable to write words or phrases from dictation. He did significantly better when asked to copy a printed sentence or phrase.
- f. Repetition of spoken phrases or sentences was poor.
- g. Calculations of even a simple nature were poorly performed.
2. **Cranial nerves:** II-XII was intact.
3. **Motor system:** No actual weakness was present. Gait was intact.
4. **Reflexes:**
 - a. A minor increase in deep tendon stretch reflexes was present on the right side.
 - b. The plantar response on the right was equivocal. The left was flexor.
5. **Sensation:** Pain, touch and vibration were intact.

Clinical diagnosis: Wernicke's type of fluent aphasia probably secondary to an embolus to the inferior division of the middle cerebral artery.

Comment: This patient who was seen before the era of modern neuroimaging provides an example of the clinical picture described by Wernicke. The use of the heart pump for open-heart surgery was associated with a high incidence of cerebral

emboli. The incidence of this complication has decreased as technical advances have been made and as “time on the pump” has decreased. As we have stressed, for solving neurological problems, the details of the history are important if the appropriate diagnosis is to be made. In the patient who is unable to provide a history, the careful review of progress notes and of nurses notes will often provide the clue that allows diagnosis.

The following case history 24-5 demonstrates such a sequence of involvement in a tumor infiltrating the posterior temporal inferior parietal area starting with a conduction aphasia.

Case 24-5: This 42-year-old right handed truck driver noted fatigue and irritability 6-8 weeks prior to admission. Three to four weeks prior to admission, he noted he was using words which he did not mean to use and certain words would not come to him. He had two generalized convulsive seizures; each proceeded by a ringing sensation in the ears, during the week prior to admission.

Neurological examination:

1. Mental status and language function

- a. The patient was alert and oriented to time, place and person.
 - b. He was cooperative and able to carry out the four-step command: “stick out your tongue, close your eyes, hold up your hand and touch the thumb to your ear”. There was however evidence of a significant left-right confusion when laterality was introduced e.g. “left hand to right ear”.
 - c. The ability to do even simple calculations was markedly impaired with or without paper e.g. $100-9=99$.
 - d. Memory was impaired; with immediate recall object recall limited to 2/5 objects and delayed recall in 5 minutes limited to 0/5. Digit span was limited to 2 forward and 0 in reverse. (normal would be 7 forward and 6 in reverse).
 - e. There was little evidence of an expressive aphasia. Flow of speech was slow with only minor mispronunciations. Reading was slow but with few errors. The patient’s did have minor difficulty in naming objects-a mild nominal aphasia. The patient’s greatest difficulty was in repetition of simple test phrases. There were moderate defects in drawings of a house and a clock but few errors in copying simple figures. There was a significant dysgraphia with marked difficulty in writing a simple sentence spontaneously or in writing from dictation. On the other hand, the patient was much better able to copy a simple sentence. Significant errors were made in spelling.
2. **Cranial nerves:** All were intact except for a mild right central facial weakness.
 3. **Motor system:** Strength, gait and cerebellar functions were all intact.
 4. **Sensory system:** Pain, touch, vibration, stereognosis, simultaneous stimulation, graphesthesia, and position sense were all intact, but point localization was impaired on the right side.

Clinical Diagnosis: Fluent posterior aphasia, disconnection syndrome plus elements of Gerstmann’s syndrome (left right confusion, dyscalculia, dysgraphia) plus seizures of focal origin (Heschl’s gyrus posterior temporal lobe) with secondary generalization. All suggested a lesion in the left posterior temporal-posterior parietal area.

Etiology was uncertain but tumor (glioma) or embolus to inferior division of left middle cerebral artery possible.

Laboratory data:

1. Skull and chest x-rays were normal.
2. **EEG:** Focal 4-5 Hz slow wave activity was present in the left parietal and posterior temporal areas.
3. **Brain scan (radioactive Hg 197):** Increased up take of isotope in the left posterior temporal –parietal area measuring 4x5 cm.
4. **Left carotid arteriogram:** Vascular mass in the region of the angular gyrus with tumor stain in the area.

Subsequent course: Papilledema soon developed and Dr. Robert Yuan performed a craniotomy. Although the cortex appeared externally normal, a firm mass could be palpated

slightly above and posterior to the angular gyrus. At 2 cm below the surface, firm yellow tumor tissue was encountered. All visible tumor and adjacent cortex of the angular and supramarginal gyri were removed and a partial left temporal lobectomy was performed. Histologic examination indicated a highly malignant glial tumor with active mitosis and necrosis (a glioblastoma multiforme). Post operatively, the patient had a marked expressive and receptive aphasia. By 30 days after surgery, the patient had a significant improvement in fluency, he continued to have a severe posterior type of aphasia. He was unable to carry out simple commands. His speech was incoherent, with nonsense words and neologisms. He appeared unaware of his errors and did not appear frustrated by his failure to follow commands. In addition to this Wernicke's type aphasia, the patient was unable to repeat words of two syllables. He could do no calculations, had severe difficulties in copying drawings and was unable to even write his name. The patient received radiotherapy but his condition continued to worsen with the development of a progressive expressive and receptive aphasia and hemiparesis all suggesting the spread of a rapidly growing glioblastoma. Coma, pupillary changes and respiratory changes then intervened suggesting the effects of herniation of the residual temporal lobe. Death occurred 7 months after onset of symptoms, and 5 months following surgery.

Comment: The early language and mental status disturbances in this patient were most severe in those tasks requiring repetition. Thus the patient could repeat no more than two digits, was unable to repeat any of the test phrases and was unable to write from dictation at a time when he could copy a sentence. Any expressive aphasia was minor, and he was fluent. He had no evidence of Wernicke type aphasia, since he could carry out a four-stage command without difficulty. Reading was relatively well preserved compared to writing, calculations and drawing construction. All of these findings suggest (1) the speech reception Wernicke's area was disconnected from the motor association areas for speech and writing Broca's areas 44,45 and the related areas of the premotor cortex and (2) the inferior parietal areas associated with writing, calculations, drawing, and the ability to distinguish left and right were damaged. The lesion found at surgery was deep to the angular and supramarginal gyri, the location of the arcuate sulcus. The seizures that finally brought the patient to neurological attention were originating in Heschl's gyrus of the temporal lobe, which would be adjacent to the area of the tumor.

The clinical state at 30 days following surgery reflected the additional effects of ablation of the Wernicke's area as well as the accentuation of the preoperative state. There had been the transient appearance of an expressive aphasia probably reflecting minor effects of the procedure on Broca's area.

The neurosurgical approach to the management of a glioblastoma particularly those involving the speech areas of the dominant hemisphere have changed in 35 years since this patient was seen. A limited stereotaxic biopsy under CT scan guidance would be undertaken and the patient would then be treated with dexamethasone and radiotherapy. The end results would have been similar and actually may even have occurred earlier. The postoperative quality of language function may have been transiently better. Unfortunately this patient had a very malignant and aggressive tumor. The median survival of glioblastomas with surgery alone is 26 weeks, with the addition of radiotherapy; 52-60 weeks. Median means that 50% of patients are going to survive less than these median figures.

The following case (24-6) provides a case of posterior aphasia with the lesion documented with CT scan.

Case 24-6: This 57-year-old female, with a long history of hypertension in the summer of 1985, had a brief episode of difficulty in word finding and a more prolonged episode in December 1985 with confusion, "visual problems", "inappropriate speech and difficulty finding the appropriate words". Following an additional episode in March 1986, she had persistent problems in reading and apraxia of the right hand.

Neurological examination (May 1986): The following abnormalities were present:

1. *Language function:* Spontaneous speech was usually quite fluent. She described the room, the environment and her friend. In contrast, capacity for repetition was very poor both as regards spoken and written speech. Spontaneous writing was very poor except for name and address

Reading to herself aloud was poor with little comprehension. She was able, however, to follow single one stage spoken or written commands but unable to do a sequence of commands. Naming of objects was well performed.

2. *Cranial nerves*: Extinction occurred in the right visual field for bilateral simultaneous stimuli.
3. *Motor system*: No hemiparesis was present.
4. *Reflexes*: Right-sided hyperreflexia and a right Babinski sign were present.

Clinical diagnosis: Posterior aphasia, infarction left posterior temporal and parietal areas, probably due to embolic occlusion of inferior division of the left middle cerebral artery.

Laboratory data:

1. *CT scan*: Infarct left posterior temporal and parietal areas (Fig. 24-6).
2. *Angiograms*: Occlusion of the left internal carotid artery. All anterior and middle cerebral artery branches filled from the right carotid. An artery to artery embolus was presumed.

The following case 24-7 would suggest this type of unilateral lesion producing a transient and partial but selective type of dyslexia.

Case 24-7: Seven days prior to admission, following a period of athletic activity, this 15-year-old, right-handed white male high school student had the onset of a 48-hour period of sharp pain in the left jaw and the supraorbital area. The next day the patient began to complain of blurring of vision and the following day had the onset of vomiting. Four days prior to admission, the patient noted that he was unable to read and to translate his Latin lessons. No definite aphasia was apparent. Two days prior to admission, the patient had the sudden onset of severe left facial pain, accompanied by tingling paresthesias of the right leg. The patient became stuporous and then unresponsive for approximately 90 minutes. An examination of spinal fluid at that time revealed pressure elevated to 290 mm of csf with 250 fresh blood cells.

Neurological examination:

1. *Mental status*: All aspects, including language function were intact.
2. *Cranial nerves*:
 - a. Examination of the fundus showed several small flame shaped hemorrhages. Visual fields were intact.
 - b. A slight, right, supranuclear-type (central) facial weakness was present.
3. *Motor system*: Intact
4. *Reflexes*: Deep tendon reflexes and superficial reflexes were symmetrical and physiologic.
5. *Sensory system*: Primary and cortical modalities were intact.
6. *Neck*: A slight degree of resistance was present on flexion of the neck (nuchal rigidity) consistent with the presence of blood in the subarachnoid space.

Clinical diagnosis: Subarachnoid hemorrhage of uncertain etiology. In view of age and the transient dyslexia, and the transient paresthesias of the right leg, an arteriovenous malformation in the left parasagittal parietal-occipital area might be suspected.

Laboratory data:

Arteriograms: An arteriovenous malformation was present in the left occipital region. The main arterial supply was the posterior temporal branch of the left posterior cerebral artery. The malformation drained into the lateral sinus. The posterior portion of the anterior cerebral artery was shifted across the midline, indicating a hematoma as well as the malformation.

Subsequent course: On that evening after his admission, the patient had the sudden onset of a bifrontal headache. For a 2- to 3-minute period, the patient was unconscious with deviation (repetitive driving) of both eyes to the right, and with sweating and slowing of the pulse rate. Over the next two days an increase in blurring of the optic disc margins was noted (early papilledema). Four days after admission, the patient suddenly complained of being unable to see from his right eye. He became restless and agitated. Additional headache and neck pain with numbness of right arm and leg were reported. Examination now disclosed a dense right visual field defect (homonymous hemianopsia). The deep tendon reflexes were now slightly more active on the right. Funduscopy suggested that

recent additional subarachnoid bleeding had occurred since new retinal hemorrhages were present. The next day (five days after admission), the patient was noted to have a significant reading disability (dyslexia), although other language functions were intact.

Because of the progressive evolution of neurological findings due to an expanding intracerebral hematoma, Doctor Robert Yuan performed a craniotomy. Blood was present in the subarachnoid space. The left lateral occipital cortical surface had numerous areas of bluish discoloration indicating an intracerebral clot. The main arterial vessel was a lateral and inferior branch of the posterior cerebral artery, bearing no relationship to the calcarine region. The draining vein was located in the occipital-temporal area, close to the tentorium. At a depth of 1 cm, a hematoma of 50 cc of clot was found. The clot extended down to the occipital horn of the lateral ventricle but did not enter the ventricle. The malformation, hematoma and related cerebral tissue of the lateral occipital area were removed. The calcarine area remained intact at the end of the procedure. Over a period of several days, the visual field deficits disappeared.

Detailed language and psychological testing approximately two weeks after surgery indicated that language function was intact except for reading. Oral reading was very slow (4 times slower than normal for a test paragraph), halting and stumbling. Comprehension of the material read was good. Minor errors were made in the visual recognition of letters. This was reflected in occasional errors in spelling. Visual recognition and naming of objects was intact. Auditory and tactile recognition of sounds, words, letters, sentences, questions, commands and so forth was intact. Calculations were intact. No right-left confusion or finger agnosia was present. Writing and drawing were intact but slow. Repetition of speech and spontaneous speech were intact.

Follow-up evaluation at 20 and 30 months indicated that, although the patient was doing well in school, receiving A's and B's with excellent grades in mathematics, he still was described as slow in reading compared to his level prior to illness. No actual errors were made in reading when this was tested.

Comment: The arteriovenous malformation in this case had involved and eventually required surgical removal of the lateral occipital area of the dominant hemisphere. The hematoma in the occipital lobe extending in from the lateral surface to the occipital horn was so located as to compress the optic radiation passing to the calcarine cortex or perhaps even to indirectly compress the calcarine cortex. Such a hematoma would also interfere with association fibers passing from left occipital areas to temporal parietal areas and with callosal radiation fibers passing from the occipital region (area 18) of the right hemisphere to the occipital and parietal areas of the dominant hemisphere. Following surgery, the patient had a relatively good recovery with the minor difficulties in reading; (a selective dyslexia) as perhaps the only indication of any damage to these fiber systems.

The complaint of the patient at the time that the right homonymous hemianopsia appeared was of blindness in the right eye. It is not uncommon for patients to localize field defects in this manner to the eye of the same side. The same may sometimes be true of patients with discharging lesions in the occipital area; the flashing lights and lines may be localized to the contralateral eye rather than to the contralateral visual field.

The episode on the night of admission is of interest because it suggests a focal adverse seizure, in this case presumably originating from areas 18 and 19 of the left hemisphere.

Geschwind (1965) has reviewed many of the previously reported cases of selective dyslexia. It is uncertain whether the information from area 18 of the non-dominant hemisphere passes to the non-dominant angular gyrus and then crosses to the dominant temporal parietal areas or whether these fibers pass instead directly to area 18 of the dominant hemisphere with information then conveyed to the dominant temporal parietal areas. He finally concludes that both pathways are probably operative. The relatively minor nature of the final residual deficit in the present case would be consistent with such multiple pathways. In addition, non-fatal hemorrhages always produce less damage than infarcts of comparable size. Finally, Coslett (2000) has reviewed various recovered pure cases of dyslexia where the right hemisphere may have played a role in reading. Such patients do better with concrete nouns than abstract nouns, verbs and functors (pronouns, prepositions, conjunctions and interrogatives). It should be noted that a relatively selective dyslexia in the absence of a severe general visual agnosia might occur. Geschwind has suggested that whether a general visual agnosia or dyslexia occurs may depend on the degree of disconnection of the dominant speech areas from the parietal and occipital areas of the non-dominant hemisphere. In the patient who already has left occipital cortex damage, dyslexia may require only damage to the splenium of the corpus callosum, whereas visual agnosia may require more extensive damage to the posterior body of the corpus callosum as well. As noted bilateral

visual association lesions (areas 18 and 19) would also produce a visual agnosia. (See also Coslett and Saffran 1989 and Friedman and Albert 1985).

In addition there are patients who have acquired dyslexia which is unrelated to the processing of the visual information input. These patients have a central (rather than the peripheral dyslexia of the pure alexia syndrome discussed above). The central dyslexic patient has an impairment of the “deeper” or “higher” reading functions by which visual word forms mediate access to meaning or speech production mechanisms. This problem is reviewed in detail by Coslett (2000).

Feinberg and Farah (2000) review the general topic of agnosias.

CHAPTER 26: VASCULAR SYNDROMES OF THE CEREBRAL HEMISPHERES

The following case history presents a young adult with severe carotid stenosis and infarction of the territories of both the anterior and middle cerebral arteries.

Case 26-1: This 23 year old right handed female on birth control pills, smoking one pack of cigarettes per day, on June 15, 1985 shortly after intranasal “snorting” of cocaine complained of gradually increasing right sided headache and then fell to the floor with a flaccid left hemiplegia with the head and eyes deviated to the right **Neurological examination:**

1. *Mental status:* The patient denied any illness and could not explain why she was in the hospital.
2. *Cranial nerves:* There was a left homonymous hemianopsia, deviation of head and eyes to the left and a left central facial weakness.
3. *Motor system:* A flaccid left hemiparesis was present.
4. *Reflexes:* deep tendon reflexes were initially depressed on the left side. Plantar responses were extensor bilaterally.
5. *Sensory system* a severe left hemisensory deficit, with a neglect of the left side of space and body was present.

Clinical diagnosis: Total right middle cerebral artery territory infarct.

Laboratory data:

1. *Initial CT Scan* demonstrated hypodensity (infarction in right frontal and parietal areas).
2. *Right carotid angiogram* demonstrated severe stenosis of the supraclinoid segment of the right internal carotid artery with severe stenosis of the M-1 segment of the right middle cerebral artery and multiple areas of narrowing of the remainder of the right MCA. *Left carotid angiogram* indicated only limited cross filling of the distal right middle and anterior cerebral arteries.

Subsequent course: On 6-21-85, 6 days after admission the previously alert patient suddenly developed a decreased level of consciousness and a fixed, dilated right pupil suggesting that tentorial herniation had been produced by severe edema or hemorrhagic transformation of the infarct. CT Scan now demonstrated massive infarction and edema-right anterior and middle cerebral artery territories plus-transtentorial and sub falx herniation (Fig.26-6). With emergency management of the increased intracranial pressure-(monitor and osmotic agents) the patient became more alert and was transferred to a rehabilitation facility.

Comment: This young woman had as a major risk factor, the intranasal snorting of cocaine. The vasospasm induced by this agent was sufficient to produce severe stenosis of the internal carotid and the initial segment of the middle cerebral artery. The multiple areas of narrowing seen in the branches of the MCA may well have represented emboli from these more proximal sources. Whether the severe stenosis of the M1 portion also involved an embolic event from the siphon remains unclear. It is clear that the severe stenosis of the carotid artery produced infarction of both the MCA and ACA territories. In this case there was insufficient cross flow from the left carotid supply to prevent infarction. As we will see in case 26-3 massive infarcts of the MCA territory plus or minus adjacent territories constitute a serious threat to life due to massive edema and or hemorrhagic infarction with the risk of herniation. The use of cocaine and of crack cocaine may be associated coronary or cerebral artery vasospasm. In addition to cerebral infarcts, cerebral hemorrhage may also occur, particularly with crack cocaine.

The following case history concerns a patient with severe stenosis at the carotid bifurcation producing both retinal and hemispheric TIA's.

Case 26-2: This 54-year-old, right-handed, white male had experienced intermittent episodes of blurring and blacking out of vision in the left eye for at least 7 years. Each episode would last 30 to 60 seconds and would occur twice per month. Ten days prior to admission, the patient had the onset of numbness of the right side of the face accompanied by minor weakness of the right face, arm, and leg. There was also a transient difficulty

in speech (possibly dysarthria, possibly difficulty in word finding). Symptoms cleared completely in 45 to 60 minutes with the exception of residual numbness of the right side of the face.

Family history: The patient's mother died of a "stroke" at age 66 years, and his father, of heart disease at age 57.

General physical examination:

- (1) Blood pressure was slightly increased to 160/100 in both arms. Pulse rate and rhythm were normal
- (2) Bruits (murmurs) were present over each carotid artery, but the heart was normal with no murmurs.
- (3) The retinal artery pulsation was easily obliterated by pressure on the globe of the left eye. No significant changes occurred on compression of the right globe.
- (4) Peripheral pulses were poor in the lower extremities.

Neurological examination: Mental status, language function, cranial nerves, motor system, reflexes, and sensory system were all normal except for a minor right central facial weakness.

Clinical diagnosis: Carotid stenosis with retinal and hemispheric TIA's.

Laboratory data:

1. Hemoglobin, serological tests for syphilis, skull and chest x-rays, electroencephalogram, and brain scan were all normal. Cholesterol was elevated to 284 mg%.

2. *Arteriography (aortic arch study)* demonstrated a complete occlusion at the origin of the left internal carotid artery. A right brachial arteriogram demonstrated filling of the left anterior and middle cerebral arteries by cross flow through the anterior communicating artery from the right side. Additional studies also demonstrated filling of the intracranial portion of the left internal carotid artery from the left posterior communicating artery.

Subsequent course: Ten days after that hospital admission, a left carotid endarterectomy was performed by Dr. Allan Callow with a restoration of blood flow following removal of the occlusive lesion (atherosclerosis with recent thrombosis) at the carotid bifurcation.

Comment: The location of disease in the left carotid artery was clearly indicated by the episodes of left eye visual disturbances followed by symptoms on the contralateral side of the body. The development of symptoms in the face, with disturbance of speech is consistent with total occlusion of the carotid artery, with greater involvement of the middle cerebral territory than of the anterior cerebral territory. The fact that this patient, with progressive stenosis of the carotid artery, had symptoms for many years only in the ophthalmic-retinal artery distribution, is explained by the excellent collateral flow into the anterior and middle cerebral arteries from the anterior communicating bypass. In addition collateral flow would enter the common carotid artery from the posterior communicating artery above the take off of the ophthalmic artery.

It should be apparent that the final complex of neurological symptoms and signs, occurring with occlusion of the carotid artery, will depend on the total pattern of cerebral blood flow in the individual patient. In many patients total occlusion of the carotid artery will produce an infarction of that portion of the cerebral hemisphere supplied by the carotid artery (primarily the middle cerebral territory). In others, a benign outcome is the result (Bornstein and Norris, 1989). With the development of imaging techniques such as CT and MRI scan - has come the recognition that small silent infarcts may occur in patients with non symptomatic stenosis of the carotid artery (Norris and Zhu, 1992).

In this case, the occurrence of symptoms in the right side of the face plus the difficulty in speech might raise the question of a possible embolus to a branch of the MCA from the thrombus at the bifurcation. A perfusion deficit would have produced problems primarily in the border zone (the area of the arm).

In this particular case, earlier evaluation of the patient might well have resulted in a demonstration of occlusive disease of the extracranial portion of the carotid artery

prior to total occlusion. For such patients surgical therapy is feasible. To restore blood flow 20 days after occlusion as in this case is unusual.

A question which remains unanswered in this case is whether this patient would have proceeded eventually to a completed lasting hemiparesis. Kase et al (1991) have summarized the various studies. The rate of completion of the stroke over a 40 month period varied from 2% (Marshall, 1964) to 51%.

The following case demonstrates a case in which the patient began with carotid TIA's progressed to a carotid border zone syndrome of infarction and then involved additionally all of the middle cerebral artery territory.

Case 26-3 (Pt. of Dr. Thomas Mullins): This 72-year old right-handed white male was admitted for evaluation of two episodes of right upper extremity weakness, each of two hours duration, beginning 2 days prior to admission. Following the first episode, the patient had persistent left-right disorientation, a deterioration in writing (dysgraphia), could not understand what he had read and had transient slurring of speech.

Neurological examination:

1. *Mental status and language function:* Intact for alertness and orientation. Language was fluent with intact repetition, and object naming; however, reading comprehension, writing, and left-right orientation were all impaired.
2. Cranial nerves: Intact.
3. Motor system, reflexes and sensory system were all entirely intact.
4. *Carotids:* A bruit was present on the left.

Clinical diagnosis: Carotid artery stenosis with TIA's reflecting decreased perfusion in the border zone followed by thrombosis and passage of emboli to the inferior division of the middle cerebral artery.

Laboratory Data:

1. CT scan and EKG were normal
2. An *arteriogram* performed on the day following admission demonstrated the following:
 - (a) The left internal carotid artery was completely occluded just above the bifurcation (Fig. 26-7A).
 - (b) The left external carotid artery did fill the left internal carotid artery at the siphon through anastomosis about the orbit (Fig. 26-7B). However, there was a cutoff just below the siphon suggesting that the thrombus (clot) at the bifurcation had extended to this level. Moreover, the left middle and anterior cerebral arteries failed to fill in this manner.
 - (c) The left posterior cerebral artery did originate from this segment of the otherwise occluded carotid siphon segment but with no retrograde filling into the basilar artery (Fig. 26-7B).
- 4) The right carotid artery filled not only the right middle cerebral and anterior cerebral artery but also was the source of the right posterior cerebral artery (Fig. 26-7C).
- 5) The right carotid system also supplied the left anterior cerebral artery and to a limited extent the left middle cerebral artery (Fig. 26-7D).

Subsequent course: On the day following admission, weakness in the right hand at wrist and finger extensors recurred. During the arteriogram, the patient was noted to have additional problems with speech. Weakness in the right upper extremity increased. Despite subsequent anticoagulation, additional progression occurred with total paralysis of the right upper extremity, aphasia and a right homonymous hemianopsia. A *repeat CT scan*, 72 hours after these events, demonstrated acute infarction with severe edema involving the entire cortical and deep territory of the middle cerebral artery and the cortical territory of the posterior cerebral artery but with relative sparing of the anterior cerebral artery territory and of the thalamic territory of the posterior cerebral artery (Fig. 26-8). Coma developed secondary to the herniation effects on the brainstem and the patient expired 8 days after admission.

Comment: This patient clearly had hemispheric carotid border zone TIA's followed by persistent symptoms that suggested involvement of the inferior division of the middle cerebral artery to the inferior parietal lobule. These latter persistent symptoms may well have been embolic from the thrombus at the level of the carotid bifurcation. There then was progression of the border zone findings

followed by involvement of the entire middle cerebral artery territory and of the cortical territory of the posterior cerebral artery. The end result was a massive cerebral infarct with considerable swelling. Such massive swelling with herniation of temporal lobe through tentorium and secondary brainstem compression is the major cause of acute death in patients dying after acute carotid artery or massive middle cerebral artery infarctions (31%). Other causes of death are pneumonia (29%), cardiac arrest (17%), pulmonary embolus (13%) (Bounds et al 1981).

Not all patients with acute carotid infarcts continue to progress. In the series of Jones and Milliken (1976), 39% of patients remained stable. Thirty-five percent had gradual improvement and 19% had a progressing deficit over 48 hours.

The following case history illustrates such an occlusion with massive infarction of the entire territory of the middle cerebral artery.

Case 26-4: This 61-year-old, right-handed black housewife one week prior to admission, suddenly fell to the floor while taking a bath and lost consciousness. She was picked up off the floor by her son who found that she was unable to move her left arm and leg. She was unable to walk and had regained no function in these extremities. Her speech had been thick, but no aphasia had been present. No headache had been noted.

Past history: Hypertension had been present for three years. Five days prior to admission, she had been switched to a new antihypertensive medication. There was no history of heart disease. Both parents had died of heart disease and hypertension.

General physical examination: Blood pressure was 150/100, pulse was regular at 84. Blood pressure was 150/100, the pulse was 84 and regular.

Neurological examination:

1. *Mental status:* The patient was obtunded and slow to respond. However, she was grossly oriented to time, place, and person.
2. *Cranial nerves:*
 - a. The head and eyes were deviated to the right. The patient could not move the eyes to the left on command. However, on vestibular stimulation, the eyes could be moved to the left.
 - b. The patient neglected stimuli in the left visual field. The pupils did respond to light.
 - c. Papilledema was present bilaterally particularly in the right fundus where a recent hemorrhage was present.
 - d. There was a decrease in pain sensation or a neglect of painful stimuli on the left side of the face.
 - e. A marked left central facial weakness was present.
3. *Motor system:* A complete flaccid paralysis of the left arm and leg was present. The patient was unable to sit up without support.
4. *Reflexes:* Deep tendon reflexes were increased on the left compared to the right. The left plantar response was extensor.
5. *Sensory system:* All modalities of sensation were decreased on the left side of the body.

Clinical diagnosis: Acute occlusion of the stem of the middle cerebral artery, possibly embolic, although primary occlusions of intracranial arteries may occur in the non-Caucasian population. Hypertensive intracerebral hemorrhage was a less likely possibility.

Laboratory data:

1. *Chest and skull x-rays* were negative but the *electrocardiogram* showed left ventricular hypertrophy.
2. *Electroencephalogram* indicated focal damage throughout the right hemisphere—most prominent in the right frontal area, (focal 3 to 5 Hz slow waves). In addition there was a relative absence of electrical activity in the right temporal area (Fig. 2-23) consistent with a severe degree of destruction of this area.
3. Brain scan 3 days after admission showed a significant but diffuse uptake of isotope (Hg^{197}) in the right hemisphere. A repeat brain scan on 9 days after admission showed a more marked uptake measuring 11x6x6 cm., extending from the right frontal area to the posterior parietal area. Uptake extended from the surface to the deep midline (Fig. 26-14).
4. Cerebrospinal fluid contained no significant cells. Protein was moderately increased to 57 mg./100 ml. Pressure at the lumbar area was 150 mm. of csf.
6. Right brachial arteriogram revealed a complete occlusion of the right middle cerebral artery at its origin (Fig. 26-15).

Hospital course: The patient showed no significant improvement during a four week hospital course.

Comment: The patient had a sudden occlusion of the right middle cerebral artery with massive infarction of the entire area of the right hemisphere supplied by the middle cerebral artery. Such massive infarctions are often, as in this case, associated with a significant degree of cerebral edema with the development of papilledema. At times the degree of swelling of the cerebral hemisphere may be sufficient to displace the pineal or the anterior cerebral artery. It is also possible in this case that the infarct was secondarily hemorrhagic. In many cases of hemorrhagic infarction the spinal fluid does not contain red blood cells.

The equal involvement of arm, arm, and leg was consistent with the involvement of the penetrating branches of the middle cerebral artery with resultant infarction in the posterior limb of the internal capsule. The deviation of head and eyes to the right indicates destruction of area 8 of the right hemisphere or of the fibers descending from this area, through the corona radiata. Involvement of the cortex in addition to this the internal capsule is also indicated by the findings on the brain scan and electroencephalogram and by the neglect of visual and tactile stimuli on the left side. As regards the etiology, an embolus to the middle cerebral artery is the most likely etiology although in a non-Caucasian patient, primary occlusion could not be ruled out. Today this patient would probably have been treated with t-PA presuming that she had arrived at an emergency room capable of administration of this agent within 3 hours of onset of symptoms and did not have contraindications in terms of preexisting conditions or of CT scan findings (hemorrhage or massive infarction -refer to Brott & Bogusslavsky, 2000) .

Prognosis for survival during the acute state of the first week depends on the degree of edema patients with massive middle cerebral artery territory infarcts due to MCA occlusion who already had early CT scan evidence of brain swelling within 24 hours of the ictus. Fifty five percent of these patients expired ,overwhelmingly of herniation effects. Patients older than 45 years had a poorer prognosis than younger patients. Infection of the lungs is a serious complication of large infarcts and a major cause of death during the second week. If the patient survives ,prognosis for recovery is related to the size of infarct. Less than 3 cm. infarcts may be associated with a good recovery ; greater than 3 cm. with severe disability (Olson ,1991). This patient had already survived for one week prior to reaching the neurologic center. Although she continued to survive, her prognosis for recovery remained poor.

The following case history illustrates many aspects of ischemia within the cortical distribution of the posterior cerebral artery. This patient demonstrates the general rule that posterior cerebral cortical infarcts are usually embolic.

Case 26-5: This 55 year old ambidextrous married white female research coordinator at approximately 11:30 AM on the day of admission suddenly developed blurring of vision possibly all over her field of vision, possibly in her left visual field, possibly in her left eye. A coworker checked her vision, and found that she had a left visual field defect. Shortly thereafter, she developed tingling paresthesias of the left face arm and leg.

Past history: Hypertension treated with hydrochlorothiazide and Lasix.

Physical examination: Blood pressure was elevated to 160/70. Weight was elevated to 264 pounds .A small ecchymosis was present under the toenail of the left second digit.

Neurological examination,(3hours after onset):

1.Mental status: Intact .

2.*Cranial nerves:* A non-congruous left homonymous hemianopsia was presented greater in the left temporal field than the right nasal field.

3.Motor system: Intact.

4.*Reflexes:* Deep tendon stretch reflexes were decreased in the lower extremities (patella,1+ and Achilles,0). Plantar responses were equivocal ,with the left probably extensor.

5.*Sensory system:* There was decreased pain and errors were made in graphesthesia over the left foot.

6.*Vascular:* There were no bruits over the carotids and subclavian areas and the blood pressures in the two arms were equal.

Clinical diagnosis: Posterior cerebral artery ischemia and possible infarct, probably embolic, involving the right calcarine cortex and thalamus or a lacunar event involving the right thalamus.

Laboratory data:

1. Duplex scans of the carotid and vertebral arteries and CT scan of the head on the day of the event were normal. RPR, ESR, TSH, proteins C, S, antithrombin 3 and all anticardiolipin antibodies were normal.
2. *MRI*, 4 days after onset (Fig.26-18) :small area of increased signal in the right occipital lobe in region of the visual cortex consistent with an infarct in distribution of the calcarine artery.
3. *MRA* (Fig.26-19): decreased flow in the distal right posterior cerebral artery probable embolic occlusion with filling of distal branches by anastomotic flow.
4. *Holter monitoring* demonstrated multiple brief episodes of paroxysmal atrial fibrillation.
5. The routine *transthoracic echocardiogram* demonstrated no clear cut abnormalities. However the *transesophageal echocardiogram* demonstrated a definite patent foramen ovale with right to left shunting.

Subsequent course: Reevaluation of the patient 22 hours after the onset of symptoms demonstrated clearing of all neurologic findings. When seen 2 weeks after the event her only complaint related to some problems in reading. This patient already been receiving aspirin at the time of the event and this was discontinued. She was begun on lifelong systemic anticoagulation with coumadin by the consultant cardiologist Dr. Filiberti since she had two conditions associated with embolization: paroxysmal atrial fibrillation and patent foramen ovale with right to left shunting. The patient did well over the subsequent 5 years.

Comment: When initially evaluated, the posterior cerebral artery location was clear but the pathophysiology was not. The subsequent imaging studies clearly indicated a small infarct involving the calcarine artery territory. Whether the previous sensory findings indicated some involvement of the posterior cerebral penetrating supply to the ventral posterior lateral nucleus of the thalamus remains unclear. The decreased flow in the right posterior cerebral artery was clearly demonstrated. In general as with the middle cerebral artery, cortical infarcts of the posterior cerebral artery territory, in the Caucasian population are almost always embolic. In this case the patient had two possible sources for emboli and was placed on long term anticoagulation.

The following case 26-6 presented at the onset with a transient bilateral posterior cerebral ischemia but with more severe residual symptoms reflecting unilateral posterior cerebral disease.

Case 26-6. This 75-year-old, white, right-handed widow developed sudden headache on the day prior to admission, with nausea, vomiting, and a poorly described bilateral disturbance of vision. She was found by a relative the morning of admission complaining of total blindness and of severe headache. She was noted to be confused and incoherent (believed she was in New Jersey rather than Massachusetts). She was able to walk only with assistance.

Past history: A minor degree of hypertension had been noted several days prior to admission.

Physical examination: The patient was an obese female with blood pressure elevated to 170/100. She was holding her head complaining of headache.

Neurological examination:

1. Mental status:
 - a. The patient was restless and disoriented for time and place.
 - b. There were difficulties in cooperation so that detailed testing of mental status could not be performed.
 - c. Simple calculations were poorly performed.
 - d. Digit span was markedly limited.
 - e. There was no left-right confusion and no evidence of aphasia.
2. Cranial nerves:
 - a. Initially the patient was unable to detect objects (e.g., a face or lights) in either visual field. Within six hours, a change had occurred. Although conjugate extraocular movements were full, the patient tended to keep her eye deviated to the right and failed to follow objects introduced from the periphery of the left visual field. The eyes could be deviated to the left on command.
 - b. The pupils responded to light.
3. Motor system:
 - a. Strength was grossly intact.

- b. A slight unsteadiness (ataxia) of gait was present.
- 4. Reflexes:
 - a. Deep tendon reflexes were grossly symmetrical.
 - b. A Babinski response was present on the left; a probable Babinski sign was also present on the right.
- 5. *Sensory system*: All modalities were intact.

Clinical diagnosis: Ischemia bilateral posterior cerebral arteries, cortical branches, probably embolic.

Laboratory data:

1. *Hematocrit* was normal. *Total cholesterol* was elevated to 312 mg./100 ml. The *glucose tolerance test* was consistent with diabetes mellitus.
2. Chest and skull x-rays and the electrocardiogram were normal.
3. The *electroencephalogram* demonstrated focal 3 to 4 cps slow waves in the right posterior parietal occipital area with rare slow waves in the right posterior temporal area consistent with focal damage in this area.
4. *Lumbar puncture* indicated clear spinal fluid with no cells and a normal protein of 18 mg./ml.

Hospital course: The patient had a significant improvement in headache and a clearing of confusion with a return of mental status to her normal level. Her hospital stay was prolonged by the development of thrombophlebitis of the left femoral vein. At the time of hospital discharge, one month after admission, there was still a residual left field defect (homonymous hemianopsia) with preservation of vision in the macular area (macular sparing). Follow-up evaluation approximately 14 months after discharge indicated no significant neurological findings except for the residual left field defect (homonymous hemianopsia with macular sparing) (Fig. 23-16).

Comment: The initial symptom of total blindness suggested bilateral posterior cerebral ischemia. The development of confusion and disorientation is also consistent with bilateral posterior cerebral ischemia. The nausea, vomiting, and minor ataxia of gait may well have indicated ischemia of the brain stem, suggesting that the basic occlusive process may have originated at a lower point in the basilar artery. The residual and most severe degree of involvement was certainly within the territory of the right calcarine artery.

The occurrence of severe headache is not usually considered in connection with ischemic-occlusive disease. A review of our cases of posterior cerebral occlusion indicates that the occurrence of severe headache is often a prominent symptom. Often in these cases prior to lumbar puncture, the diagnosis of subarachnoid hemorrhage was considered.

At the present time evaluation would include a CT or MRI scan. Other examples of posterior cerebral artery cortical infarcts are presented in the visual system chapter with appropriate CT scans.

The following case 26-7 provides an example of an intracerebral hematoma of unknown etiology in a young patient.

Case History 26-7. This 33-year-old white, right-handed, male linotype operator, at approximately 8:30 p.m. had the sudden onset of numbness of the left side of his mouth. At 10:30 p.m. he developed a severe right frontal headache and noted sudden onset of numbness of the left upper extremity which rapidly spread to involve the entire left side. Marked weakness of the left arm and leg developed. Evaluation that evening at his local community hospital indicated a dense left homonymous hemianopia, a marked left central facial weakness, an absence of any voluntary movement of the left arm and leg and no awareness of painful stimulation of the entire left side. A left Babinski sign was present. Lumbar puncture revealed opening pressure elevated to 235 mm. of water; and 50 fresh red blood cells per cubic mm. The patient was subsequently transferred to the neurosurgical service at New England Center Hospital.

Past history: There were no remarkable features as regards hypertension, renal disease, or diabetes mellitus. No history of drug use was obtained.

Physical examination: The patient was moderately obese with a normal blood pressure of 110/85. Examination of the heart revealed no abnormalities. No rigidity of the neck was present. There were no murmurs over the cranium.

Neurological examination:

1. **Mental status:** Orientation, speech and the ability to provide a coherent history were all intact.
 2. **Cranial nerves:**
 - a. Examination of the fundi showed no hemorrhage or papilledema.
 - b. A dense left homonymous hemianopsia was present.
 - c. Sensation was defective on the left side of the face, as well as the left side of the body.
 - d. A left central facial weakness was present.
 - e. The tongue deviated to the left.
 3. **Motor system:**
 - a. A dense flaccid paralysis of the left arm and leg was present.
 - b. There was no resistance to passive motion in the left arm and leg.
and little in the left lower extremity (that is, a flaccid paralysis was present).
 - c. Cerebellar tests were negative.
 4. **Reflexes:**
 - a. Deep tendon reflexes were absent in the left upper extremity but increased in the left lower extremity
 - b. A Babinski sign was present on the left. The plantar on the right was flexor.
 - c. No grasp reflexes were present.
 5. **Sensation:**
 - a. There was no perception of pinprick or of tactile stimulus on the entire left side of the body.
 - b. Position and vibratory sensation were absent on the on the left.
- Clinical diagnosis:** Intracerebral hematoma right putamen-thalamus or embolus stem of MCA with hemorrhagic transformation.

Laboratory data:

1. Hematocrit, white blood count, and differential were all within normal limits. Sedimentation rate was normal.
2. *Tests of bleeding time, clotting time, and prothrombin time* were all within normal limits.
4. *Skull x-rays* revealed a shift of the pineal, 7 mm. from right to left.
5. *Electroencephalogram* revealed frequent focal 4 to 5 cps slow waves in the right hemisphere most prominent in the frontal and parietal areas consistent with focal damage in these areas.
6. *Arteriograms* (right common carotid) revealed a 12 mm. shift of the pericallosal branch of the anterior cerebral artery. The internal cerebral vein was also shifted 8 mm. from right to left. The middle cerebral branches emerging through the sylvian fissure were depressed. There was no evidence of an abnormal arteriovenous shunt or of an aneurysm. Cortical vessels and veins in the suprasylvian area were stretched over relatively avascular areas. The conclusion was a space-occupying mass in the right posterior frontal parietal area consistent with an intracerebral hematoma.

Subsequent course:

On the day of admission, the patient was taken to the operating room. A right parietal burr hole was made. The underlying cortex was noted by the neurosurgeon, Dr. Robert Yuan, to bulge prominently. A needle was inserted to a depth of 1 cm. into the cortex where 25 cc. of old, dark red blood under pressure was expelled. Free drainage of blood continued through a catheter which remained in place for 2 days.

Return of voluntary movement in the left lower extremity at the hip and knee was noted on the day following surgery. Reevaluation of neurological status 2 weeks after surgery, revealed continued improvement. The left homonymous hemianopsia was no longer present but the patient did have some difficulty in reading (losing the left half of the line of print). A left central facial weakness was present; voluntary hand-foot movements on the left were still not possible. Proximal muscle groups (shoulder, hip, knee) had returned to 60 per cent of normal strength. Deep tendon reflexes were now hyperactive in the upper and lower left extremities with a left Babinski sign. A dense

sensory deficit remained on the left side with no perception of pain, touch, vibration, and position in the upper and lower extremities. Reevaluation 4 weeks after surgery, revealed a return of pain and temperature sensation but continued deficits in proprioception. Reevaluation by Dr. Yuan 4 months after surgery, indicated a return of strength in the left hand with a strong grip. The gait was typical of a spastic hemiplegia. Reflexes were unchanged. Sensory examination revealed a return of primary modalities such as vibration and pain, but marked errors in cortical modalities, such as position sense, were made. Follow-up 7 months after surgery indicated an excellent return of strength on the left side but continued incoordination in the left hand due to deficits in proprioception.

Comment:

This patient from several standpoints presents a number of unusual features not seen in the typical case of intracerebral hemorrhage. The patient was relatively young (33 years old) and had no history of hypertension. He had none of those conditions such as leukemia, bleeding disorders, and the like which predispose to intracerebral hemorrhage. The arteriogram provided no evidence of an intrinsic or a secondary metastatic brain tumor. Moreover, histological examination of the tissue and drainage material obtained at the time of surgery failed to reveal tumor cells. No aneurysm was demonstrated on angiography. Although no arteriovenous malformation was demonstrated at the time of arteriography, such a malformation may have been present previously but destroyed in the process of hemorrhage. The significance of the minor prodromal sensation of numbness of the face remains uncertain. This may have reflected an initial small area of ischemia with secondary hemorrhage.

Where was the initial site of hemorrhage? In this case, the hemorrhage apparently originated in the subcortical white matter of the parietal lobe presenting as a lobar hemorrhage. The pattern of initial evolution of symptoms and the final pattern of sensory deficit is perhaps more consistent with such a parietal lobe location. From the prognostic standpoint, he did not lapse into coma and did not have compromise of brain stem functions as so often occurs when there is tentorial herniation or an extension of the hemorrhage into the ventricular system. That these various events did not occur, may in part relate to the drainage of the hematoma by the neurosurgeon with removal of this supratentorial mass lesion. The management of intracerebral hemorrhages is discussed in greater detail by Ojemann and Heros, (1983).

The following three cases provide examples of subarachnoid hemorrhage from aneurysms at the three major sites: posterior communicating-internal carotid (Case 26-8), middle cerebral bifurcation (Case 26-9) and anterior communicating –anterior cerebral junction (Case 26-10)

Posterior communicating- internal carotid junction.(Figs. 26-24)

Case 26-8: This 66-year-old white housewife, five days prior to admission, had the sudden onset of a severe bicipital bifrontal headache associated with vomiting. The headache was constantly present for 3 days but was increased by coughing. At the same time, she noted an alteration of vision in the right eye. She noted also a drooping of the right eyelid. The headache subsided, only to recur one night prior to admission as a severe occipital headache associated with vomiting. There was no past history of hypertension. The patient was admitted to her community hospital. A lumbar puncture revealed the presence of subarachnoid blood and the patient was transferred to the neurology/neurosurgical services of the New England Medical Center on 10/2/66.

General physical examination: The patient was an obese female with blood pressure of 140/80 and complaints of severe headache. Her temperature was normal.

Neurological examination:

1. *Mental status:* The patient was alert with mental status intact.
2. Cranial nerves:
 - a. Fundus: Blurred discs were present bilaterally, being greater on the right. No venous pulsations were present on the right.
 - b. Nerve III: The right pupil measured 4 mm. and was not reactive to light on direct or consensual stimulation.. The left pupil measured 2mm and was reactive to light. Ptosis of the right eyelid was present. At rest on forward gaze, there was outward deviation of the right eye. The patient was unable to adduct the right eye on left lateral gaze and failed to move this eye on upward or downward gaze. Other extraocular movements were intact.

c. Nerve VII: Minimal flattening of the right nasal labial fold was present.

3. *Motor system*: Strength, coordination, and gait were intact.
 4. *Reflexes*: Deep tendon: A minimal relative increase was present on the right. Plantar responses: The left was flexor, the right was equivocal.
 5. *Sensation*: All modalities were intact.
 6. *Neck*: Mild nuchal rigidity was present (resistant to passive flexion of head onto chest).
- Clinical diagnosis**: Subarachnoid hemorrhage due to an aneurysm at the posterior communicating–internal carotid junction.

Laboratory data:

1. Skull and chest x-rays were normal.
2. Studies of bleeding time, clotting time, and prothrombin time were all within normal limits.
3. *Arteriograms* revealed an aneurysm of the right internal carotid artery just below its junction with the posterior communicating artery. There was no left-to-right flow through the anterior communicating artery. There was narrowing of the anterior cerebral arteries near their origin bilaterally. This suggested to the radiologist the possibility of vasospasm, secondary to the presence of subarachnoid blood.

Hospital course:

Because the history suggested several episodes of bleeding, surgical therapy was selected. A right temporal craniotomy was performed by Dr. Robert Yuan with clipping of the neck of the aneurysm. The temporal lobe was retracted revealing a 13 mm.-long saccular aneurysm, arising from the internal carotid artery close to the junction with the posterior communicating artery. Distally the aneurysm enlarged into a large sac which was hidden behind the oculomotor nerve. This nerve was bulging at the point where the aneurysm, which was clipped, was well formed. The more distal sac of the aneurysm was thin and showed signs of previous rupture with yellow staining of the adjacent meninges. The sac of the aneurysm was covered with Gelfoam. Postoperatively, significant deficits as compared to the preoperative neurological status were evident. The level of consciousness waxed and waned with periods of alertness alternating with periods of apathy and drowsiness. Twenty days after surgery, she was described as sitting with both eyes closed, continuously grasping and palpating the arm of the chair with the right hand, less frequently with the left. There was a marked bilateral release of an instinctive grasp reflex. There was increased resistance in both upper extremities, at times described as plastic rigidity, at times as the “Gegenhalten,” associated with bilateral frontal lobe disease. No spontaneous voluntary movements of the left leg occurred. Bilateral Babinski signs were present. A bilateral resting tremor of the hands and of the head was also present. At times inappropriate jocularity was present. All of these findings suggested a bilateral front lobe syndrome with infarction in the territory of the anterior cerebral arteries and additional involvement of the basal ganglia. The complete paralysis of the right third nerve remained at preoperative level. At the time of hospital discharge, one month after surgery, the frontal lobe findings and the weakness in the left leg remained prominent.

Comment:

The presence of severe headache in association with a mild degree of nuchal rigidity suggests meningeal irritation. Such irritation could indicate a subarachnoid hemorrhage or a meningitis (inflammation of the meninges due to bacterial or viral infection). The sudden onset of the headache is more consistent with a subarachnoid hemorrhage. The lack of fever and of accompanying or prodromal systemic findings is also against the diagnosis of meningitis. Finally, the clearly focal third nerve findings are more in favor of the diagnosis of subarachnoid hemorrhage (although focal or multifocal neurological findings may develop as complications of a bacterial meningitis).

In this case, the significant findings on neurological examination related to the right third cranial nerve. The third cranial nerve is particularly subject to compression by aneurysms of the posterior communicating artery because having emerged from the midbrain it pursues an anterior course towards the cavernous sinus in a close parallel relationship to the posterior communicating artery. In general, compressive lesions of the third nerve produce initially an alteration in pupillary constrictor functions, then involvement of the levator palpebrae and finally involvement of the superior, medial and inferior

rectus, and inferior oblique muscles. The initial alteration in vision in the right eye and ptosis of the right eyelid at the onset of headache are then consistent with a compressive lesion. The patient at the onset of symptoms did not report a diplopia.

The third nerve as it emerges from the midbrain also passes in close relationship to the posterior cerebral and superior cerebellar arteries, but aneurysms of these vessels are much less common than those which occur in relation to the posterior communicating artery and internal carotid artery.

These findings with extrinsic compressive disease of the third nerve are to be contrasted with the pattern of intrinsic brain stem involvement of the third nerve nucleus where medial rectus or superior rectus function is more likely to be initially compromised.

The patient had minimal findings suggesting involvement of the left corticospinal and corticobulbar tracts: minimal right central facial weakness, minimal increase in deep tendon reflexes on the right side, and an equivocal right plantar response. The findings may have been produced by a slight shift of the brain stem to the left due to the small mass of aneurysm on the right side of brain stem. With such a shift, compression of the left cerebral peduncle against the tentorium might occur. In any case, these findings were minimal. The significant findings in this case clearly related to the third cranial nerve and it is these findings which allowed localization of the lesion prior to arteriography.

As regards the postoperative course, it is evident that this patient had severe involvement of the frontal lobes presumably as a result of bilateral infarction within the territory of the anterior cerebral arteries. In retrospect, the narrowing of the anterior cerebral arteries at their origin, presumed secondary to "spasm" noted at the time of arteriography, may have provided a clue as to the development of the complication. The neurosurgeon, faced with the decision as to the best time to intervene, would prefer as the ideal situation, the moment when arterial spasm has not yet developed or is no longer present but bleeding has not yet recurred. In reality the risk of recurrent hemorrhage is so great that the aneurysm should be clipped as soon as possible for example the day of presentation. Vasospasm can now be treated with calcium channel blockers and after clipping by increasing the blood pressure to increase perfusion. The typical angiographic appearance of aneurysms in this location is demonstrated in Figure 26-24. Occasionally large aneurysms can be demonstrated on the CT scan.

Middle cerebral bifurcation (Fig 26-25).

Case 26-9: This 46-year-old, right-handed, white, married male, was admitted to the neurology/neurosurgical services of the New England Medical Center on 6/10/66. He presented a history that 10 days prior to admission, he had the sudden onset of a severe, throbbing, supraorbital and vertex headache. The headache began while the patient was in bed in the early stages of sexual intercourse. The patient noted no weakness except that his tongue "felt funny" in articulation for approximately one minute. There was a transient difficulty in speech during this period.

Past history: Mild hypertension had been present.

General physical examination: Blood pressure was 160/100.

Neurological examination:

1. *Mental status* was intact.
2. *Cranial nerves* were intact.
3. *Motor system* was intact.
4. *Reflexes* were physiologic
5. *Sensory system* was intact.
6. Headache could be precipitated by *head movement*.
7. With *cervical flexion*, pain occurred in the neck and lumbar area occurred.

Laboratory data:

1. Skull and chest x-rays were normal.
2. *Electroencephalogram* revealed focal damage in the lateral aspect of the left hemisphere (focal 3 to 5 cps slow waves).
3. *Lumbar puncture* on the day following admission revealed opening pressure elevated to 270 mm. of water and closing pressure to 210 mm. of csf. The fluid was xanthochromic (yellow discoloration). In addition 38 fresh red blood cells per cubic mm. were present. Protein was elevated to 80 mg./100 ml. Hinton was negative.

4. *Arteriography* revealed a bilobed aneurysm at the trifurcation of the left middle cerebral artery measuring 8 x 4 mm. Spasm and narrowing of the proximal anterior and middle cerebral arteries were noted.

Hospital course:

On the day following admission, the patient complained of a few-minute episodes of numbness in the right face, tongue, and right upper extremity with thickness of speech. Examination now revealed right central facial weakness and slight slurring of speech. The patient also now complained of additional neck pain on extreme forward flexion. On June 12, 1966, the patient had another short episode beginning with numbness over the right thumb, spreading to the right hand and then to the angle of the mouth.

Because of the several episodes which occurred, following hospital admission, involving the right face, tongue, and hand in association with the finding of fresh red blood cells in the spinal fluid, it was considered likely that bleeding from the aneurysm was continuing to occur. Surgical therapy was therefore considered necessary to prevent additional (and possibly fatal) subarachnoid hemorrhage. On May 20, 1966 a left frontotemporal craniotomy was performed by Dr. Robert Yuan with subsequent plastic coating of the entire aneurysm to reinforce its wall. There was evidence of recent hemorrhage in the subarachnoid space with yellow discoloration of the meninges. In order to expose the aneurysm, it was necessary to remove the anterior tip of the temporal lobe back to a distance of 2.5 cm. There was a small amount (5 to 10 cc.) of intracerebral blood clot in the superior temporal region close to the aneurysm. The aneurysm itself had no actual neck that could be clipped. Several middle cerebral branches appeared to arise from the dome or lateral wall of the aneurysm.

In the postoperative period, the patient initially did well. A minor expressive aphasia was present, but the patient was alert and well oriented. However, fever and jaundice developed. With the development of significant alterations of liver functions approximately 7 days after surgery, the patient became confused and agitated. The prothrombin time fell to 3 per cent of normal and there was evidence of bleeding into the gastrointestinal tract at this time. The prothrombin deficit was corrected by administration of vitamin K. It was unclear, however, as to whether any minor intracranial bleeding occurred during this time. Some improvement in liver functions occurred, and the patient became more alert but continued to manifest inappropriate behavior, emotional lability, and disturbance of memory. He left the hospital against medical advice one month after surgery, on July 20, 1966.

The patient was readmitted to the hospital approximately one month later on August 13, 1966. For two days, the patient had been less active, appeared confused, glassy eyed, and failed to communicate. The degree of obtundation cleared when adequate dosage of the anticonvulsant medication, Dilantin, was administered. This fact taken on conjunction with the electroencephalogram, which demonstrated frequent focal spikes (excessive neuronal discharge) in the left temporal area (Fig. 29-1C) led to the conclusion that the episode which precipitated his readmission might well have represented a prolonged seizure discharge. The electroencephalogram also demonstrated an increase in slow wave activity in the left hemisphere, particularly the left temporal area indicating a possible increase in damage in the left temporal area. This appeared to be correlated with apparent progression of the patient's aphasia which was now receptive as well as expressive in nature. At the time of discharge, a severe expressive aphasia was still present.

Comment:

The sudden onset of severe headache during exercise or exertion (sexual intercourse in this case) is characteristic of subarachnoid hemorrhage. The location of the aneurysm was suggested by the symptoms relevant to the tongue and speech during the initial episode. The episode on June 11, 1966, involving numbness of the right face, tongue, and right upper extremity, could only indicate disease within the territory of the left middle cerebral artery. The lumbar puncture at this time indicated not only evidence of the initial leakage of blood 10 days prior to admission (an elevation of cerebrospinal fluid protein and a xanthochromia), but also fresh red blood cells suggesting that additional leakage of blood had occurred.

The nature of the episodes which occurred on June 11 and 12 is not certain. Most likely these were ischemic in nature related to decrease in blood flow as a result of clot formation within the aneurysm or from spasm of the adjacent portion of the middle cerebral artery. At times, however, symptoms such as rapidly spreading numbness occurring in episodes may suggest focal epileptic discharge. The development of an area of excessive discharge would not be unusual since this aneurysm involves those

middle cerebral artery branches which are supplying the cerebral cortex. In addition hemorrhage within the Sylvian fissure is likely to damage the surrounding cerebral cortex. Blood and iron are epileptogenic.

The patient's course following surgery was complicated by the development of severe liver dysfunction. The etiology of this problem was never clear, the various studies suggesting either a toxic hepatitis related to various drugs and anesthetic agents or a variety of obstructive jaundice. What the patient's eventual recovery would have been had this problem not developed is uncertain. It is clear, however, that during this post-

operative period the patient did develop significant impairment of language functions, possibly related to infarction or oozing of blood in areas supplied by the middle cerebral artery. It is also evident that a seizure focus had developed in this area. Such seizure foci may have developed in relation to the preoperative hematoma noted in the temporal lobe, in relation to the surgical manipulation of the area, or in relation to the postoperative complications.

Today (2002), the history presented by this patient would have prompted an immediate CT scan and a lumbar puncture if the CT scan were negative. An arteriogram would have been performed immediately after these studies. Surgery would have been performed immediately after the evaluation of the angiographic studies to prevent the recurrent episodes of bleeding.

Anterior communicating -anterior cerebral junction(Figs. 24-26, 24-27, 24-28)

Case History 26-10. . (Patient of Dr. John Sullivan). This 49-year-old, right-handed truck driver was transferred from his local community hospital for evaluation of subarachnoid hemorrhage.

The patient had experienced occasional frontal headaches for the previous 5 years. In June, 1965, while changing a tire, he had a severe throbbing frontal headache which cleared after thirty minutes. Since that time he had experienced daily throbbing frontal headaches, usually present on arising in the morning. On September 4, 1965, the patient had the onset of a particularly severe headache which began while he was engaged in heavy work on a boat. There was associated stiffness of the neck, nausea, vomiting, and a general sensation of weakness.

Evaluation at his local community hospital revealed papilledema (blurred optic disk margins on funduscopic examination). Nuchal rigidity was present. The lumbar puncture demonstrated grossly bloody cerebrospinal fluid. He was subsequently transferred to the neurology/neurosurgical services of the New England Medical Center on 9/7/65.

Past history:

1. Hypertension had been noted in June, 1965.
2. The patient's father had died at age 59 of a cerebrovascular accident.

General physical examination:

1. Blood pressure was moderately elevated to 180/100. Pulse was 60.
2. No bruits (murmurs) were present over the skull.
3. A significant degree of nuchal rigidity was present. The neck could not be actively or passively flexed.

Neurological examination:

1. Mental status:
 - a. The patient was somnolent but could be aroused, although attention span was noted to be shortened.
 - b. He was oriented for place and situation but confused as to time.
 - c. Digit span was shortened to 5 forward and 4 in reverse.
 - d. The patient was unable to do calculations.
2. Cranial nerves:
 - a. Sense of smell was decreased on the right side.
 - b. Disk margins were indistinct on examination of the fundus. Arterioles were tortuous and irregular.
3. Motor system:
 - a. Strength and tone were intact.
 - b. Cerebellar tests were normal.
4. Reflexes:
 - a. Deep tendon reflexes were symmetrical.

- b. Plantar responses were flexor.
- 5. Sensory system: All modalities were intact.

Laboratory data:

1. Bleeding, clotting, and prothrombin times were all normal. Platelets were normal on smear.
2. Chest and skull x-rays were normal.
3. *Arteriograms* demonstrated an aneurysm of the anterior communicating artery which extended posteriorly and to the right. The aneurysm filled from the left carotid circulation.

Hospital course: During the evening of September 11, 1965, the patient became lethargic and would not speak or obey commands. Blood pressure rose to 240 mm. systolic. The patient became totally unresponsive with pupils fixed and dilated and with incontinence of urine. Deep tendon reflexes were exaggerated with plantar responses extensor. Within minutes, the patient became responsive again; pupils were reactive, although the right remained sluggish. The patient made purposive movements and obeyed commands. Lumbar puncture subsequently indicated grossly bloody spinal fluid. The patient remained confused and less alert with a tendency to fall asleep.

On September 17, 1965, the patient again suddenly complained of violent headache and lost consciousness for approximately 30 minutes. The right pupil became dilated, and the right eye deviated to the right suggesting a right medial rectus weakness. The blood pressure again rose to 240/140. As previously, the patient regained consciousness. Although confused, he had no clearly lateralizing signs. Subsequent lumbar puncture again revealed the presence of fresh red blood cells.

Because repeated episodes of bleeding had occurred, surgical therapy was undertaken. On September 21, 1965 a left frontal craniotomy was performed by Dr. Robert Yuan. The left frontal pole was resected exposing the left anterior cerebral artery and the aneurysm which arose from the anterior communicating artery. The medial surface of the right frontal lobe was cystic and contained 20 cc. of hematoma. The hematoma was evacuated. The aneurysm was reinforced by spraying with a plastic coating.

Neurological examination approximately 1 week after surgery indicated that the patient was confused and disoriented, with a "rather negative response" refusing to follow directions and to speak to examiners. Blood pressure was noted to be extremely labile with a drop of 50 mm. of mercury systolic when the patient moved from prone to sitting position. Equivocal Babinski signs were present, and the patient was incontinent of urine and feces.

Reevaluation on November 17, 1965, approximately two months after surgery, indicated that although the patient was ambulatory and able to take care of his daily needs, he remained confused for time and place. When the patient was examined 6 months after surgery, confusion was no longer present; intellectual functions were consistent with his education.

Approximately 2 years after surgery, the patient, who had recently been married, reported that he was impotent, unable to obtain an erection.

Comment:

In this case, the history of sudden onset of severe headache and stiffness of the neck, precipitated by exertion, clearly suggested a subarachnoid hemorrhage originating from the rupture of an intracranial aneurysm. It is likely that several episodes of subarachnoid bleeding occurred in June and September of 1965. While the clinical findings of somnolence and confusion with a decrease in olfaction on the right may have suggested the possibility of an anterior communicating-artery location, these were certainly not firm diagnostic clues. The episodes characterized by sudden alteration in blood pressure, while nonspecific, might have raised the question of orbital-frontal, anterior cingulate, or hypothalamic effects (areas within the distribution of the anterior-cerebral arteries).

The negativity of the patient following surgery undoubtedly indicated preoperative and operative damage to the orbital and prefrontal areas. The bilateral Babinski signs and the incontinence of urine and feces in the postoperative period probably reflected damage to the parasagittal motor and premotor areas within the distribution of the anterior cerebral arteries. The impotence may have reflected damage at the frontal or hypothalamic level.

Today, an initial episode such as occurred in June 1965 would have prompted a CT scan and a lumbar puncture if that study had been negative. Of course many exertional headaches are not a result of

subarachnoid hemorrhage. Nevertheless the more serious entity must be ruled out at the emergency room level, since the mortality and morbidity of the frequent recurrent hemorrhage are so high. Again the use of early arteriography and early surgery are to be emphasized.

Case 26-11 illustrates many of the neurologic aspects of bacterial endocarditis.

Case 26-11: This 34-year old right hand married white male hair dresser was admitted with a one month history of night sweats, fever to 102-103° F., generalized aches and pains. Within the previous 3-4 months, the patient had undergone repeated dental procedures for dental infection. He had been reported to have a mild heart murmur 2-3 years prior to admission. His urine had recently become dark. The day prior to admission he had noted a small hemorrhagic lesion on the dorsum of his left hand.

Physical exam:

1) Skin: A small indurated red lesion dorsum left hand and a small red lesion under the nail bed 3rd left toe.

2) Heart: A grade IV/VI high-pitched holosystolic murmur was present at the apex; and a high-pitched II/VI murmur at the base; both not previously noted to this degree.

3) Temperature was elevated to 101° F

Neurological examination: Entirely within normal limits.

Clinical diagnosis: Bacterial endocarditis with systemic emboli but without neurological symptoms at this point.

Laboratory data:

1) **CBC:** Anemia with hematocrit 31 and hemoglobin of 10.1.
White blood count was 9900 with differential of 78% poly-morphonuclears and 9 atypical lymphocytes.

2) Sedimentation rate was elevated to 38 mm.

3) **Urinalysis** indicated 8-10 red blood cells per high power field.

4) All three **blood cultures** drawn on the day of admission produced growth of streptococcus viridans (alpha hemolytic).

5) **Echocardiogram** indicated a prolapsed mitral valve with probable mitral insufficiency. In addition, irregular densities on the mitral leaflets suggested vegetations.

Hospital course: All of these findings were consistent with a diagnosis of subacute bacterial endocarditis with evidence of microemboli to extremities (skin lesions) and to kidneys (hematuria). The patient was begun on high dosage intravenous penicillin (24 million units per day) with an excellent response as regards fever and general symptoms. Thirteen days after admission he again developed a temperature elevation. The following day, at 2 p.m., he abruptly developed difficulty with speech and a right hemiplegia. Over the next 2 hours this rapidly evolved to the following neurological state.

Neurological examination:

1) Mental Status and Language Function

a) The patient was drowsy - holding the left side of his head as though in pain.

b) He was mute.

c) He was unable to carry out any spoken or written commands.

2) Cranial Nerves

a) The patient neglected the right visual field and had no response to threat in the field.

b) The fundoscopic exam indicated blurring of the disc margins on the left.

c) Right central facial weakness was present.

d) Pain sensation was decreased on the right side of the face.

3) **Motor System:** A flaccid right hemiparesis was present although some purposive withdrawal of the right arm and leg occurred on painful stimulation.

4) Reflexes

a) Deep tendon reflexes were increased bilaterally but right were greater than left with clonus of the right ankle.

- b) The right plantar response was extensor, the left flexor.
 - 5) *Sensation*: A right-sided hypalgesia was present. Other modalities could not be tested.
 - 6) Neck and Skin
 - a) No nuchal rigidity was present.
 - b) New splinter hemorrhages were present under the nails of the upper extremities.
- Neurological diagnosis:** Cerebral embolus left middle cerebral artery, with possible mycotic aneurysm and possible hematoma left middle cerebral artery secondary to bacterial endocarditis.

Laboratory data:

An immediate CT Scan (Fig. 26-30) demonstrated a large intracerebral hematoma involving the left basal ganglia and insula with massive shift of the left hemisphere to the right.

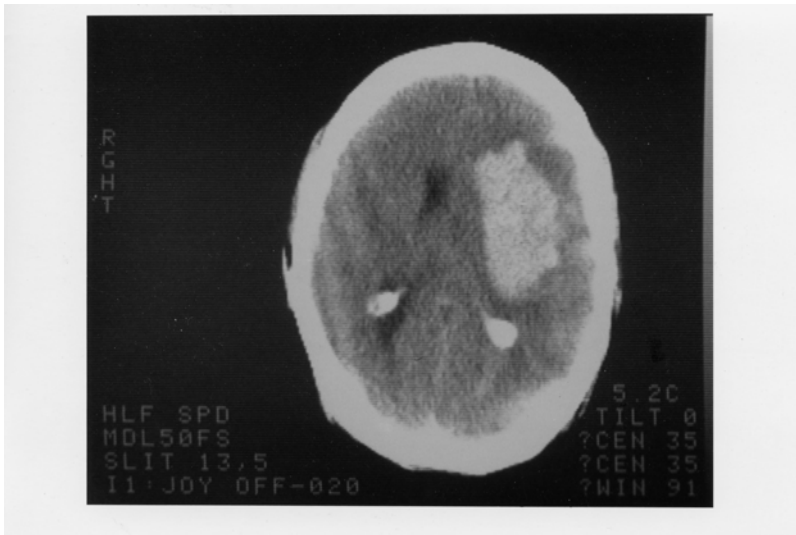
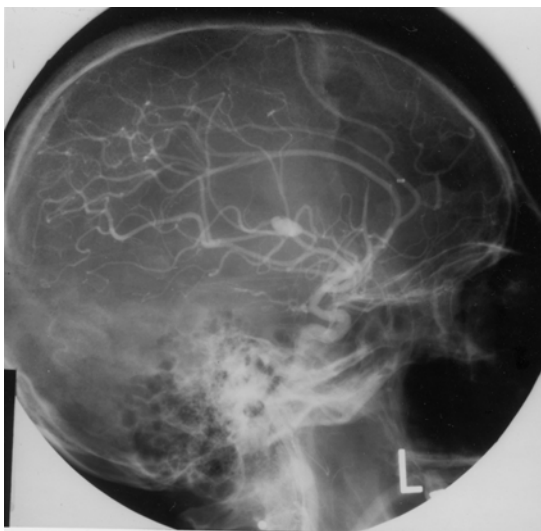


Figure 26-30.

2. An immediate arteriogram: (Fig. 26-31A) demonstrated a small aneurysm (arrow) arising from a small branch of the left middle cerebral artery (MCA) within the Sylvian fissure. A large avascular area surrounded this aneurysm with upward and lateral displacement of anterior cerebral arteries, medial displacement of lenticular striate, branches of the MCA and lateral and downward placement of the cortical MCA branches.



Subsequent course: That evening Dr. Robert Johnson removed a large intracerebral clot. Over the next 2 weeks the patient began to have some improvement in his right hemiparesis and aphasia. However two weeks after surgery, he developed right-sided focal status epilepticus. The patient had been receiving Phenytoin (Dilantin) but the level was low. Intravenous Phenytoin, intravenous Dexamethasone and Mannitol were administered. The CT scan now demonstrated a larger hemorrhage surrounded by edema. The patient was taken to surgery and additional old clot and a small amount of recent clots were removed. The patient failed to respond. He developed fixed dilated pupils and bilateral Babinski signs. The arteriogram (Fig.26-31 B,C) was repeated and now demonstrated a much larger aneurysm (measuring 11 mm vs 4-5 mm in previous films). There was also evidence of additional shifts of the anterior cerebral artery and internal cerebral vein. Anterior-frontal branches of the middle cerebral artery were occluded. Regression occurred and 8 days later patient met brain death criteria with absence of all brainstem reflexes, no spontaneous respirations and an absence of all cerebral electrical activity (silent EEG).

Comment: This patient presents a panorama of almost all of the cerebral complications of bacterial endocarditis including:

- a) Multiple septic emboli to brain, kidney, and small peripheral arteries;
- b) Mycotic aneurysm;
- c) Intracerebral hematoma
- d) Eventual mortality.

The mycotic aneurysm with eventual rupture was not a feature noted on presentation but instead was a late complication. (A silent unruptured aneurysm may well have been present on admission.) This subacute delayed presentation is more common in streptococcal endocarditis as opposed to the more virulent staphylococcal infections where acute intracranial presentations are the rule.

In this case, the aneurysm when initially discovered was small and associated with an intracerebral hemorrhage.

The aneurysm continued to enlarge after evacuation of the initial hematoma and eventually additional hemorrhage occurred. Not all patients with mycotic aneurysm will have intracranial hemorrhage. In the series of Brust et al (1990), 41% were associated with rupture. Of 20 aneurysms followed with angiography or CT scan, ten became smaller or disappeared, 10 remained unchanged or enlarged despite an adequate treatment course with antibiotics. In the present case, initial rupture occurred almost 2 weeks after admission and beginning of antibiotic treatment.

The recommended approach in patients with endocarditis to avoid the fatal complications of mycotic aneurysm rupture is to perform 4 vessel angiography in those patients with endocarditis who develop neurological symptoms. If a mycotic aneurysm is found, prompt surgical treatment (clipping) should be performed. Unfortunately many patients with mycotic aneurysms have no neurological symptoms prior to rupture. To perform angiography in all patients with bacterial endocarditis, would not be practical and would fail to detect aneurysms that developed after the studies. However, when long-term anticoagulation is planned in patients on the completion of antibiotic treatment to prevent additional emboli, angiography should be performed or repeated. The entire role of anticoagulation in bacterial endocarditis remains unclear. (See Salgade et.al 1987 and Hart et.al 1987, 1990). MRI may have an increasing role in non-invasive diagnosis, since MRI angiography should be able to detect aneurysms greater than 2-3 mm in diameter

Figure 26-32. Arteriovenous malformation in the right parietal area demonstrating the abnormal tangle of vessels and infarction of the surrounding cerebral cortex and white matter.

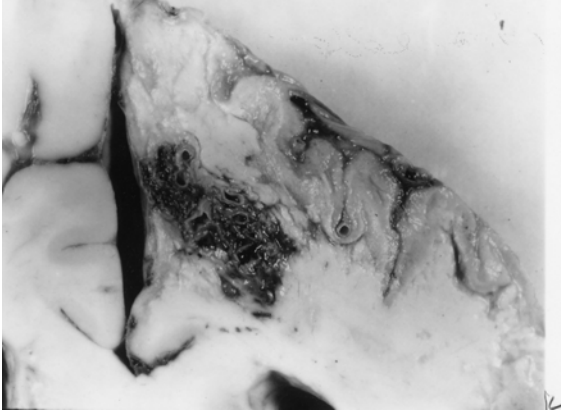


Figure 26-32. In this case, the malformation was fed mainly by the right anterior cerebral artery and drained into the superior sagittal sinus. This 46-year-old woman had, as a primary problem, subarachnoid hemorrhage from an anterior-communicating saccular aneurysm, with other unruptured aneurysms at left posterior communicating, and right superior cerebellar. (Courtesy of Dr. John Hills).

Case history 26-12 provides an example of a long-term unruptured arteriovenous malformation presenting as a seizure disorder.

Case 26-12: This 51-year old right-handed female experienced two nocturnal generalized convulsive seizures 6 years prior to evaluation . Evaluation by Dr. Robert Bazemore at that time revealed a significant 30-year history of minor episodes: “little sensations”. The patient described sudden strange feelings as though moving in slow motion. With other episodes she would feel at a distance from her surroundings with a sense of detachment at times with a strange odd smell. After 2-3 minutes the “spell” would alter, she would feel depressed with a sense of terrible fear. The patient also had a long history of migraine headaches (bilateral throbbing) which were often preceded by visual auras more prominent in the right visual field. The neurological examination was normal. She was treated with anticonvulsant (Phenytoin). When seen by the author for other unrelated neurological problems 6 years later , the interval history indicated no additional generalized seizures but complex partial seizures had continued.

Neurological examination: entirely within normal limits.

Clinical diagnosis : Simple and complex partial seizures of temporal lobe origin .

Laboratory data:

1. The *CT scan without enhancement* now demonstrated a calcified lesion in the anterior-medial right temporal lobe which enhanced with contrast (Fig. 26-32A). Large early draining veins were also noted (Fig. 26-32B).

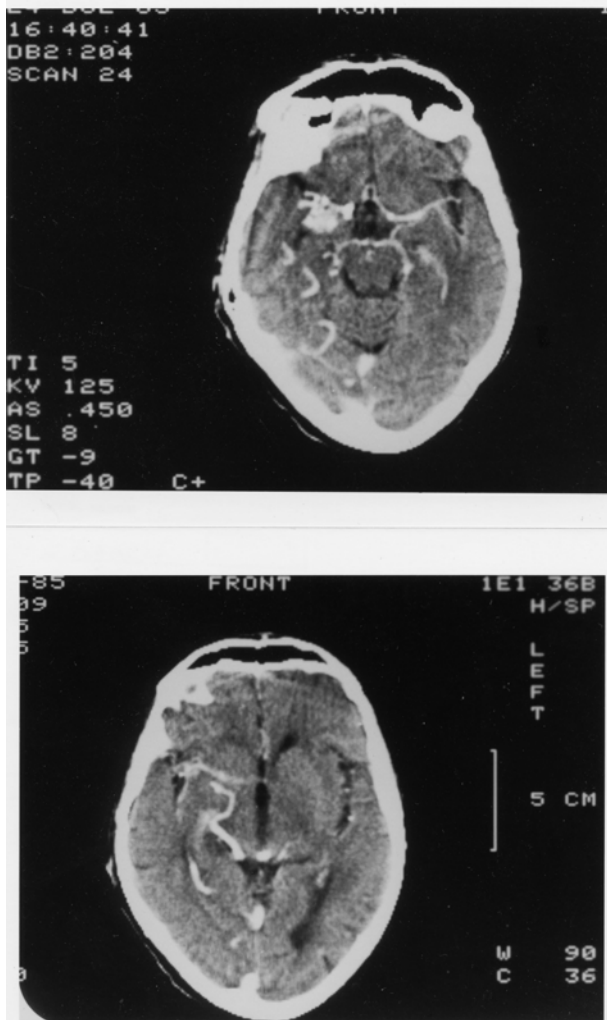


Figure 26-33. Arteriovenous malformation. Right anterior temporal:
 Case History 24-12 CT Scan. This 51-year-old right-handed female
 was evaluated in 1983. She had generalized seizures in 1977 and 36-
 year history of complex partial seizures. She would feel "weird
 sensations" and detached with a "strange odd smell", then a sense of
 terrible fear. She also had a history of migraine headaches preceded
 by visual auras, and a normal neurological examination. was not
 remarkable. The CT Scan without contrast demonstrated a calcified
 lesion in the right anterior temporal lobe (not shown).
 A). With contrast a large enhancing lesion was present in the deep
 Sylvian fissure area - involving anterior medial temporal areas, uncus
 and adjacent insula.
 B) At a higher level of section a large draining vein was visualized (see
 also fig 26-35 and text for details).

Subsequent angiographic studies confirmed the anterior venous malformation with supply from right internal carotid, middle cerebral and anterior choroidal arteries (26-33A) and the presence of shunting into a large early draining vein (26-33B).

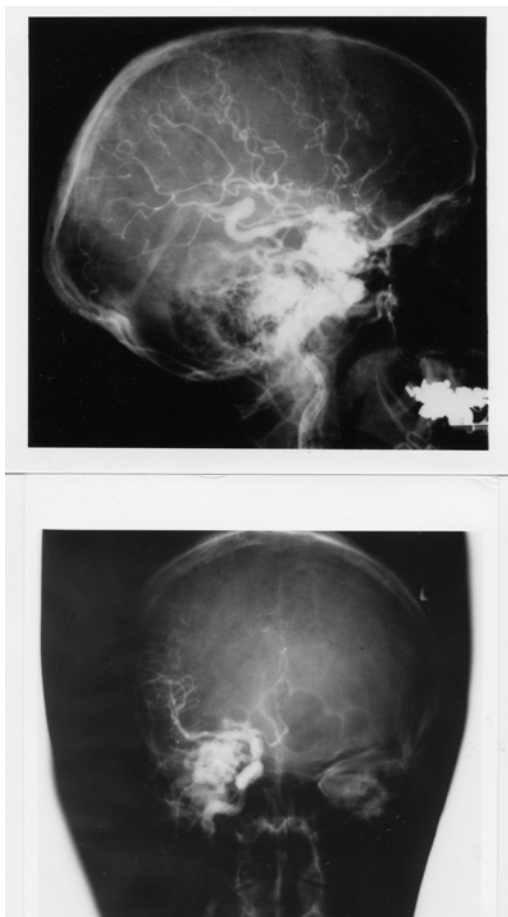


Figure 26-34. Arteriovenous malformation: Right anterior temporal lobe. Right carotid arteriograms. Case History 24-12

- A) Malformation - supplied by right internal carotid, middle cerebral, and anterior choroidal branches.
- B) There is early shunting of arterial blood into a large draining vein. See Text and Fig. 26-34 for details.

Comment: This patient presented with classical complex partial seizures originating in the right temporal lobe. No definite evidence of either subarachnoid or intracerebral hemorrhage was present over 35 years. With the use of CT and MRI scan, more of these lesions are being identified in an unruptured state in patients investigated for seizures and headaches.

Considerable controversy remains as to the appropriate therapy for the unruptured cerebral arteriovenous malformation (compare Aminoff, 1987 and Heros and Yong-Kwang, 1987). Long-term follow-ups - 12-20 years - does suggest a 25-39% risk of hemorrhage with a mortality from that hemorrhage of 10-14%. The risk of recurrent hemorrhage the first year is 6% with the subsequent annual risk for hemorrhage for both ruptured and unruptured 3% per year (see also Crawford et al, 1986, Brown et al 1988, Rigamont, et al 1988).

Surgical therapy involved excision after ligation or embolization of feeding vessels (Stein and Wolpert, 1986, Stein and Mohr, 1988, and Mohr, et al 1986).

CHAPTER 27: NON VASCULAR SYNDROMES : TRAUMA, TUMORS, INFECTIONS, TOXIC METABOLIC AND SYSTEMIC DISORDERS

I TRAUMA

Case 27-1 presents an example of an epidural hematoma seen in 1963 prior to modern neuroimaging.

Case 27-1: This twenty-two-year-old, white airman, during a winter storm, was involved in an auto accident at 11:30 p.m., in which he struck his head against the windshield. He also sustained minor abrasions of the shoulder, hands and chest. The patient apparently was dazed, perhaps unconscious, for a matter of seconds to minutes. He was taken by ambulance to the emergency room of the nearby army hospital where a brief evaluation indicated that the patient was alert, without definite neurological findings, and apparently without significant injuries. Skull X-rays did indicate a linear fracture over the right temporal area which did not, however, definitely cross the major groove of the middle meningeal artery. The patient was, therefore, admitted to the intensive care ward for head injury observation.

The patient was apparently alert upon his arrival on the ward. It should be noted, that the major attention of the physicians in the emergency room and of the nurses on the intensive care ward was given to four other patients from the same accident who sustained very severe and obvious injuries. However, by 5 a.m., the patient was reported by the nurses to be agitated and confused.

Neurological examination: (8 a.m.)

1. *Mental Status:* The patient was agitated and unable to cooperate. He was sitting up in bed, holding his head, moaning and hyperventilating to a marked degree. He answered only occasional questions and then with a yes or no.

2. *Cranial Nerves:* intact except

Fundi: The examination was negative but incomplete.

Pupils: There was a bilateral but sluggish response to light. A minimal asymmetry was present. The right pupil was perhaps slightly larger and slightly more sluggish than the left.

3. *Motor System:* All limbs were moved spontaneously. There was a variable increased resistance to passive motion, but this was apparently due to the patient's inability to cooperate.

4. *Reflexes:* Deep tendon reflexes were increased bilaterally. Plantar responses were bilaterally equivocal.

5. *Sensation:* Pain sensation appeared to be intact.

6. *Neck:* There was variable resistance to attempted flexion.

7. *Head:* The patient moaned when palpated over left or right temporal areas.

Neurological diagnosis : Possible evolving acute bilateral epidural or subdural hematoma

Subsequent course: The patient was to be evaluated by the civilian neurosurgical consultant, whose arrival was delayed by several other emergencies and a snowstorm. In the meantime, progression occurred.

Neurological examination (4 p.m.): The patient was now deeply comatose with little response to stimulation. The pupils were now bilaterally fixed and dilated. The four limbs were extended in a decerebrate posture with significant spasticity on passive motion. The degree of spasticity in the upper limbs could be modified by tonic neck maneuvers. The plantar responses were bilaterally extensor. Spontaneous respirations were now irregular and infrequent, and the patient required the assistance of a mechanical respirator.

Neurological diagnosis: Acute tentorial herniation with brain stem compression secondary to epidural hematoma.

Subsequent course: A general surgeon immediately performed definitive therapy. Bilateral burr holes were placed. An epidural hematoma over the right temporal-parietal area was evacuated and the

bleeding middle meningeal artery branch was coagulated and ligated with a significant rapid improvement in the patient's status. Follow-up examination approximately two months later indicated that the patient had returned to active duty but was experiencing some problems related to changes in recent memory and to changes in motivation and personality. No significant motor or sensory findings were present. Minor and inconsistent asymmetry of deep tendon reflexes was present.

Comment: This patient followed the usual pattern of a short lucid period followed by the rapid progression of confusion, agitation, coma and brain stem deterioration of function. As indicated by Plum and Posner (1980), the development of hyperventilation is often indicative of a midbrain-upper pontine stage of damage from an expanding supratentorial lesion. The early appearance of hyperventilation followed by bilaterally fixed dilated pupils and a decerebrate state may well indicate that the supratentorial lesion was producing a more central downward compression of the midbrain and less of a lateral uncal-type compression. In any case, it is evident that brain stem compromise was progressing rapidly. So rapidly, in fact, that therapy had to be undertaken immediately. In such a case, there was no longer time for the transfer of the patient to a specialized treatment center and no longer any time for specialized laboratory studies. Today, such a patient would have undergone CT scan studies at the time of emergency room evaluation or at the first sign of change in mental status. Similar cases of recovery of function from brain stem compression in patients with acute subdural or epidural hematomas have been reported by Brendler and Selverstone (1970).

The following case provides an example of chronic bilateral subdural hematomas

Case 27-2. (Patient of Dr. Alex Danylevich). This 83-year-old white female was transferred from her local hospital because of increasing confusion. Two months prior to admission, she had been involved in a motor vehicle accident sustaining fractures of her ribs and left clavicle. She also struck her head and had a scalp hematoma in the right frontal area. She was admitted to her local hospital at that time for several days. She was described as having post-traumatic anterograde and retrograde amnesia and obtundation which cleared over her hospital stay. She returned to her usual activities. Two months after the trauma she re-entered her local hospital with a three day history of increasing confusion and lethargy. When she became mute she was transferred to St. Vincent Hospital. Serum sodium at her local hospital had been low at 124 mEq/liter and CSF protein was reported at 62 mg%. EEG was reported as diffusely slow.

Neurological examination:

1. *Mental status:* She was relatively lethargic but could be aroused to an alert state. The patient was mute and did not follow commands even when relatively alert.
2. *Cranial nerves:* Pupils were 2 mm. and reactive. Sudden paroxysmal nystagmoid deviations of the eyes to the right occurred during the exam.
3. *Motor system:* Strength was intact. Tone was increased in the right leg.
4. *Reflexes:* Deep tendon stretch reflexes were symmetrical. Plantar responses were extensor bilaterally.
5. *Sensory system:* Pain responses were intact.

Clinical diagnosis: Chronic subdural hematomas, probably bilateral .

Laboratory data:

1. The CT scan (Fig. 27-3) demonstrated significant bilateral chronic subdural collections much denser on the left where the lateral ventricle was obscured and shifted to the right. The right lateral ventricle and sylvian fissure were enlarged. There was a question of additional recent rebleeding into the subdural collection on the left.
2. Serum sodium was low at 117 mEq/liter. Serum osmolality was 236. Urine sodium was 53 mEq/liter.

Hospital course: Serum sodium was corrected. Then, bilateral subdural hematomas were removed via burr holes on the right and a bone flap on the left where substantial chronic membrane and fluid were found. Neurological examination eight hours after conclusion of the procedure, indicated an alert patient who had no apparent language disorder and no weakness. Follow-up CT scan ,6 days after surgery revealed re-expansion of the cerebral hemispheres. Considerable cortical atrophy was

now evident. This was presumably long-standing predating the subdural hematomas. She was transferred back to her local hospital, 10 days after surgery. At that point she was alert; ambulating with assistance and was able to feed herself. She did develop transient right face and hand focal motor seizures which were treated with anti-convulsants.

Comment: If the history of trauma two months previously had not been present with a prior hospital admission related to the trauma, the confused obtunded mute state in this patient might easily have been attributed to a metabolic encephalopathy (low serum sodium) or to the cortical atrophy of a senile dementia of Alzheimer's type. Many patients with primary cerebral disease will develop a low serum sodium due to inappropriate secretion of anti-diuretic hormone with retention of water and dilution of serum sodium. The mute state in this patient in retrospect probably reflected the severe involvement of the dominant left cerebral hemisphere. The sudden eye movements to the right probably represented focal seizure activity originating in the left frontal eye fields, not far from the cortical area providing the focus for the post operative seizures.

In some patients without a definite history of trauma, the predominant findings may be those of a progressive bilateral frontal lobe involvement with confusion, bilateral grasp reflexes, and a frontal lobe apraxia of gait. In such patients, the nature of the pathological process involving the frontal lobes may be uncertain. The differential diagnostic list may include metastatic disease, frontal parasagittal meningioma or frontal glioma.

There are patients who are at increased risk for subdural hematomas: patients receiving anticoagulant medications, or patients with bleeding disorders, e.g., as in leukemia. The problem is more common in the elderly, in chronic alcoholics, and in patients with Parkinson's disease perhaps because such population groups are more prone to unsteadiness and falls. In the patient with cortical atrophy as in Alzheimer's disease, the bridging veins may be stretched and thus more prone to tear. In addition, the patient is unable to recall minor trauma and is already confused. In addition, because of the atrophy, a large amount of blood may accumulate in the subdural space without producing early symptoms of headache and other symptoms.

The problem also exists in the infant during the first year of life. The picture presented, however, differs significantly from that seen in the adult because in the infant, separation of the sutures may occur, allowing the intracranial cavity to expand. The onset is then often nonspecific and nonfocal: an enlargement of the head, a failure to thrive, a failure to gain weight, a failure to reach developmental landmarks. At times, generalized seizures, vomiting, and papilledema may be noted. The etiology often relates to presumed birth trauma.

A related problem may also be seen in infants following meningitis. This is the problem of subdural effusions usually occurring in relation to Haemophilus influenzae meningitis. The diagnosis of both subdural hematoma and subdural effusions may be made in the infant by CT or MRI scan replacing the earlier technique of subdural taps. The cerebrospinal fluid in these cases is often found to be abnormal with the presence of blood or xanthochromia and an elevated protein content.

II TUMORS

The following case history provides an example of the course of a low grade glial tumor.

Case 27-3: This 41 year old right handed white widow was admitted to the hospital because of increasing frequency of seizures. At age 30, eleven years prior to admission, the patient experienced her first generalized convulsive seizures. The neurological examination and the electroencephalogram were normal. Four years prior to admission, the patient had a change in the character of her seizures, she began to experience focal seizures involving the right arm and leg. These would begin with the sensation of a "chill" or stiffening of the right leg and a "numbness" (a tingling) which would then spread to the lower back. At the same time, weakness would occur in the right leg followed by repetitive clonic movements of the right arm. During this time, the patient would be unable to talk distinctly but would be aware of her surroundings. Although the episode continued for several minutes, there was no apparent loss of consciousness. Examination by Dr. John Hills at that time revealed a slowness of response but no definite neurological deficits. The EEG was again normal. Neurological evaluation three years later (one year prior to admission) was again unremarkable although focal seizures were still occurring every 2-4 weeks. Evaluation 2 months prior to admission, now indicated a more increase in deep tendon stretch reflexes in the

right lower extremity and an equivocal plantar response on the right side .Hospital admission finally occurred because the weakness experienced in the right leg during the seizure was becoming more severe.

Neurological examination

1. *Mental status*: The patient was anxious and tremulous with moderate psychomotor retardation and poor attention span. Digit span was limited to 5 digits forward and 4 in reverse .However orientation, memory ,delayed recall , calculations and language function were all intact.
2. *Cranial nerves*: All were intact with no papilledema.
3. *Motor system*: Strength, gait and cerebellar signs were all normal.
4. *Reflexes*: Deep tendon reflexes were slightly increased on the right side. The plantar response on the right was equivocally extensor.
5. *Sensory system*: Intact except for a minimal bilateral decrease in sensation at the toes.

Clinical diagnosis: Left parasagittal tumor most likely a meningioma, low grade glial tumor such as oligodendroglioma or low grade astrocytoma considered possible but very unlikely.

Laboratory data:

1. Chest and skull x rays ,radioactive brain scan(Hg 197) and left carotid arteriogram were all normal.
2. *EEG* was now mildly abnormal because of occasional focal sharp waves ,left parietal parasagittal area.
- 3.*Pneumoencephalogram* demonstrated a slight downward depression left lateral ventricle suggesting a possible left parasagittal mass. The CSF obtained was normal.

Subsequent course: Since the brain scan and arteriogram were normal, a meningioma was considered unlikely and a low grade glioma was considered the most likely diagnosis. The lack of calcification on the skull x rays was considered a point against the diagnosis of an oligodendroglioma and more in favor of a low grade astrocytoma. Since the patient was relatively free of neurological deficit and the dominant hemisphere was involved, neurosurgical intervention was deferred .Her anticonvulsant medications were readjusted. Frequent office evaluations indicated that significant progression was occurring with increasing weakness of the right leg, and an inability to form letters in handwriting. .Four months after hospital discharge ,the patient now had a right central facial weakness ,a mild right hemiparesis, and increased deep tendon stretch reflexes on the right and a right Babinski sign. Speech was dysarthric with a minor degree of misnaming or inability to name objects. A left carotid arteriogram now indicated a deep left posterior frontal mass lesion. There was also a suggestion of abnormal vascularity in the region of the pericallosal and callosal marginal branches of the anterior cerebral artery. Surgical exploration of the left frontal area indicated slight discoloration of and widening of gyri. Probe counting located an area of increased uptake of isotope (P32) at 16X normal in the mid and posterior frontal area. A partial frontal lobectomy was performed from the level of the sphenoid wing laterally and forward but sparing the speech areas. However tumor was still present at the posterior margin of the resection . Histologic examination of the tumor removed indicated a grade I- II astrocytoma. Following surgery ,the right sided weakness progressively improved, speech was unchanged. Following hospital discharge the patient ,received a 3 month course of supervoltage radiation (7,500 roentgens)directed to the left frontal parietal area. When last evaluated 18 months after surgery, there was a moderate disorientation for time , a nominal aphasia a slowness in following commands ,a perseveration of speech and performance, a right central facial weakness and a clumsiness in following commands.

Comment: The onset of seizures at age 30 ,always raises the question of a possible brain tumor. The initial seizures however were generalized convulsive seizures and the neurological examination and the EEG were normal, thus decreasing the risk of a tumor. When focal seizures appeared at age 36,the risk of a tumor was significantly increased but still ,the exam and the EEG remained normal .In retrospect ,the slowness of response might have suggested some frontal lobe involvement. By age 41, it was evident that a focal process was slowly evolving with some involvement of parasagittal motor cortex. Again the psychomotor retardation and the deficit in digit span at a time that delayed recall was normal (possibly consistent with an impairment of working memory) might have suggested some degree of. prefrontal involvement. Certainly, by the time of surgical intervention, 11 years after onset of symptoms, the pace of progression had accelerated. This might have indicated some alteration in the basic biological activity of the tumor.

Finally a note about diagnostic techniques . This patient was initially seen in 1956 and hospitalized in late 1967. At the time CT scan and MRI were not yet available. Today, an adult with onset of seizures at age 30 would have undergone an MRI or at least a CT scan with contrast. The diagnosis would have been made much earlier in time but the eventual treatment and results of treatment would probably not differ significantly from those obtained in 1967. The role of radiotherapy in low grade gliomas remains controversial. There is a role once transformation to a higher grade of malignancy has occurred.

MALIGNANT GLIOMAS

The following case demonstrates the apparent acute (possibly stroke like) onset and rapid progression of a very malignant glioblastoma multiforme.

Case 27-4 (patient of Dr. Tom Mullins): This 68 year old right handed white male was admitted to St Vincent Hospital with an apparent 4 to 5 day history of difficulty in doing calculations and in speaking, "he could think of the word ,but had difficulty getting it out".

Neurological examination :

1. *Mental status and language function*: Speech was limited to short phrases with loss of connectors and sentence structure. Writing was impaired but, repetition, comprehension, naming and reading were intact.
2. *Cranial nerves*: Intact.
3. *Motor system*: Strength and gait were intact .However fine motor movements of the right hand were impaired .
4. *Reflexes*: Tone was increased on the right. The right patellar reflex was increased. Bilateral Babinski signs were present.
5. *Sensory system*: Intact.

Clinical diagnosis: Diagnosis was uncertain .The abrupt onset suggested a possible vascular event such as an embolus in the middle cerebral artery territory but the overall pattern including bilateral Babinski signs without significant hemiparesis was unusual. Thus other possibilities had to be considered including focal herpes simplex encephalitis, tumor or a small lobar hemorrhage.

Laboratory data :

1. EEG : Focal left hemisphere delta and theta slow wave activity was present.
2. CT scan(Fig.27-7):A. The non enhanced study demonstrated a low density mass in the mass in the left frontal-parietal parasagittal region with areas of hemorrhage. B. The contrast enhanced study demonstrated an irregular rim of enhancement.
3. Angiogram indicated an avascular mass in the left frontal-parietal area.

Subsequent course: Dr. Alex Danylevich performed a subtotal resection of this tumor which was found to contain blood clot and cystic fluid. The histology of the tumor was glioblastoma multiforme (Fig.27-5). The patient subsequently received 4000cGy whole brain radiation and an additional 2000cGy to the tumor site. Three months following surgery ,the patient developed increasing obtundation. CT scan revealed a large left frontal necrotic mass. Fever, hypocalcemia and hypernatremia developed and he expired one month later.

Comment: This patient presented with what appeared to be an abrupt onset of language problems raising the question of a cerebrovascular accident. In retrospect , it was evident on the CT scan and at surgery that the acute onset reflected the hemorrhage and necrosis which had occurred within the tumor. This was a rapidly growing ,extremely malignant tumor which apparently had outstripped its blood supply despite the neovascularity.

III INFECTIONS

FOCAL

Subdural empyema

The following case provides an example of subdural empyema complicating frontal sinusitis.

Case 27-5. This forty-eight year old, right-handed, white male was referred for evaluation because of headaches and papilledema. For 3 weeks prior to admission, the patient had severe bifrontal headaches which were constantly present and interfered with sleep. One week prior to admission, the patient developed a fever of 105° with a white blood count (WBC) of 25,000. X-rays indicated "sinusitis". The patient was hospitalized at his local community hospital. Confusion soon developed. Three days prior to transfer to a neurologic unit, the patient had a series of seizures characterized by turning of the head and eyes to the left. Lumbar puncture had indicated clear cerebrospinal fluid with pressure of 300 mm. and protein increased to 65 mg./100 ml. The patient had chronic right nasal discharge for ten years. Eight weeks prior to admission, the patient, while stooping down, struck his right frontal areas but was not - unconscious. A right periorbital ecchymoses developed, and the patient also had the onset of bilateral frontal headaches.

General physical examination: Temperature was elevated to 101°. There was right periorbital edema. Excoriation of right nasal mucosa was present.

Neurological examination:

1. *Mental status:* The patient was alert but irritable and slightly confused. He was poorly attentive and failed to persist in carrying out motor activities. He was oriented grossly for time, place and person. Calculations were poorly performed. Delayed recall was defective.
2. *Cranial Nerves:* All were intact with the exception of the fundi. Low-grade papilledema was present and venous pulsations were absent.
3. *Motor System:* Strength was intact, but there was a slight drift downward of the outstretched left arm.
4. *Reflexes:* Deep tendon reflexes were somewhat brisker at left arm and leg (3+) as compared to the right (2+). Plantar responses were flexor. A bilateral grasp reflex was present.
5. *Sensory system:* Intact
6. *Skull & Neck:* There were slight tenderness over the right periorbital area. Minimal nuchal rigidity (resistance to passive flexion of the neck) was present.

Clinical diagnosis: Right frontal subdural empyema or brain abscess.

Laboratory data:

1. The *WBC* was increased to 14,350 cells per cubic mm., and the sedimentation rate was increased to 110 mm. in one hour.
2. *Sinus X-rays:* Bilateral maxillary and frontal sinusitis was present with resorption of bone.
3. *Electroencephalogram:* Focal 4 to 7 cps slows wave activity was present in the right parietal area suggesting focal damage. Moreover, focal voltage suppression (reduction of voltage) was present in the right anterior frontal area suggesting a possible subdural collection.
4. *Right carotid arteriogram* showed an apparent slight shift of the anterior cerebral vessels to the left suggesting a right hemisphere space-occupying lesion.

Hospital Course: Following these studies a right frontal trephine (burr) hole was placed by Dr. Robert Yuan. When the dura was incised, 5 cc. of yellow purulent material escaped from the subdural space and additional purulent drainage was aspirated. Additional burr holes were placed in the right occipital area where a few drops of subdural pus were encountered. No pus was obtained from the left subdural area. Subsequent cultures demonstrated *Staphylococcus aureus* as the responsible organism. The dura and cortex otherwise appeared unremarkable although cerebral edema was present. The patient was subsequently treated with appropriate antibiotics. His temperature gradually subsided to normal and his mental

status cleared. Three weeks later, a bilateral frontal sinusotomy was performed by Dr. Thomas Klein with drainage of the sinus. Histological examination of a section of sinus mucosa removed demonstrated intense chronic inflammation. The patient continued to improve. When seen in followup examination four months after admission, papilledema had subsided, no neurological findings were present except for a slight reflex asymmetry (slightly increased on the left).

Comment: This patient presented a definite history of chronic nasal sinus infection with a recent exacerbation. The role of trauma in the exacerbation is uncertain. It is clear, however, that the sinusitis had produced involvement of the adjacent bone with subsequent spread to the adjacent frontal subdural space. The severe headache experienced by the patient reflected not only the process of infection involving the sinus and meninges but presumably also the increase in intracranial pressure. The early involvement of the right frontal area was suggested by the initial symptoms of confusion and by the occurrence of focal seizures characterized by turning of the head and eyes to the left. The findings of the electroencephalogram suggested a subdural collection of fluid or pus in the right frontal area.

These clinical and laboratory impressions were confirmed by the subsequent surgical observations. In the present case the arteriogram suggested only a non-specific space-occupying lesion in the right frontal area. The more specific finding in these cases would involve the displacement of distal branches of the anterior and middle cerebral artery from the inner table of the skull as in a subdural hematoma. Today the CT scan or the MRI/MRA is the study of choice for confirming the diagnosis of a subdural collection. Additional review of subdural empyemas will be found in Miller et al 1987. In the pre-antibiotic era, infections involving the nasal sinuses could produce thrombophlebitis of the cortical veins and superior sagittal sinus. With that complication, infarction of that area of motor cortex representing the leg could occur resulting in unilateral or bilateral leg weakness as well as focal motor seizures. Infection of the nose or face or of the ethmoid or sphenoid sinuses could produce thrombophlebitis of the cavernous sinus resulting in the syndrome discussed in the cranial nerve chapter: unilateral or bilateral involvement of the cranial nerves found in the lateral wall of the cavernous sinus (III, IV, VI and the ophthalmic division of V). The ophthalmic vein may be obstructed producing edema of the eyelid and face. Obstruction of the retinal vein produces papilledema. Infection of the middle ear or mastoid may produce involvement of the transverse or lateral sinus. If this extends to the jugular vein, increased intracranial pressure may also occur. However increased intracranial pressure may follow any involvement of the other venous sinuses. At the present time, dural venous sinus thrombosis is usually more indicative of dehydration and other systemic conditions in the infant and in the adult of immunological disorders or of conditions that produce a state of hypercoagulation such as polycythemia, carcinoma, pregnancy or birth control drugs. (refer to Daif et al, 1995 and DeVeber et al, 2001)

CHAPTER 30 MEMORY

A case of Wernicke-Korsakoff syndrome is presented in case 30-1.

Case 30-1. Patient of Doctor John Sullivan and Doctor John Hills): This 62-year-old, white, right-handed stonecutter had been a known heavy alcoholic spree drinker for many years. The patient would drink large quantities of wine for 6 to 8 weeks at a time. Two years previously, the patient had been admitted to the Boston City Hospital because of delirium tremens (tremor and visual hallucinations). Two months prior to admission shortly following the death of a brother-in-law, the patient began his most recent drinking spree. He unaccountably found himself in Florida, not knowing where he was and

why he was there. Apparently, he had drifted aimlessly for 5 weeks with no definite food intake for a month. The patient was brought back by his family and hospitalized at his local community hospital with diplopia, ataxia and marked impairment of memory. The patient had complaints of numbness of his fingertips and unsteadiness of gait. The patient after beginning treatment was shortly thereafter referred to the Neurology Service at the New England Medical Center.

General physical examination: No abnormalities were present except for an enlarged liver with the edge palpated approximately 2-1/2 finger breadths below the costal margin.

Neurological examination:

1. Mental status:

- a. The patient was markedly disoriented for time and place. At times, the patient thought that he was in New Jersey; at other times, he stated correctly that he was in Boston.
- b. The patient, with suggestion, would recall his apparent travels that day to various other locations within and outside Boston (he was actually in the hospital). Confabulation was also evident when it was suggested that he had recently seen various fictitious persons.
- c. Remote memory; The patient was unable to state his age. The patient was able to provide his birth date correctly. He could not give his address or telephone number. When quizzed as to the President of the United States, he selected on multiple choices the previous president. At times, the patient often indicated to visitors that his mother and father were still alive, though both parents had been dead for over 20 years.
- d. Insight; He appeared to have little insight for his disorientation in time. He had no insight as to his condition or for the reason for his hospitalization.
- e. The patient's digit span was normal at 7 forward and 6 in reverse.
- f. The patient could name various objects correctly when these were presented to him and yet he was unable to retain any memory of which objects had been presented to him five minutes previously. He was unable to retain any information concerning a story that he had been requested to learn.
- g. The patient was able to do 2 and 3 figure additions and multiplications without difficulty. He was able to do the initial subtractions in the serial 7 test but then lost track of the number to be subtracted.
- h. The patient was able to read and to write without difficulty. He showed no constructional apraxia and no left-right confusion.

2. *Cranial nerves:* There was horizontal diplopia on right lateral gaze. The minor degree of separation of images, however, did not allow precise identification of the muscle involved. A minor weakness of the right lateral rectus was suspected.⁶ Horizontal nystagmus was present on lateral gaze, bilaterally and vertical nystagmus on vertical gaze.

3. *Motor system:* Strength was intact except for a minor degree of weakness in the distal portions of the lower extremities evident on ankle dorsiflexion and toe dorsiflexion.

The patient walked on a narrow base with eyes open and showed no evidence of an ataxia of gait. On a narrow base with eyes closed, the patient had a positive Romberg test.

No cerebellar findings were present.

4. *Reflexes:* Deep tendon reflexes were normal at triceps and biceps, decreased at radial periosteal. And absent at patellar and Achilles even with reinforcement.

⁶ The minor nature of the diplopia undoubtedly reflected the improved nutritional status that had occurred during the previous 5 days of hospitalization at his community hospital. We presume that if the patient had been examined prior to hospitalization, more marked lateral rectus palsy probably would have been delineated.

Plantar responses were flexor bilaterally.

No grasp reflex was present.

5. Sensory System: Pain and touch were decreased in the lower extremities below the mid calf. Vibratory sensation was absent at the toes and decreased over the tibia to a marked degree and to a lesser degree over the knees. There was to a lesser extent, a decrease in the upper extremities at the fingertips and wrists.

Position sense was decreased at fingers and toes.

Clinical diagnosis: Wernicke' encephalopathy plus nutritional poly neuropathy

Laboratory data: Complete blood count, liver functions and renal functions, CSF, EEG, and X-rays of the skull and chest were all normal.

Subsequent course: The patient was treated with thiamine, 50 MGS daily. There was a significant improvement in extraocular functions. The patient had no diplopia after the day of admission. There was no significant change in his mental condition or peripheral neuropathy. Evaluation 3 months later, indicated persistent disorientation for time and place and severe selective deficits in memory (delayed recall was still grossly defective).

Comment: This patient presents a relatively typical history of the Wernicke-Korsakoff syndrome. He had been a heavy alcoholic spree drinker. The major symptomatology that was apparent to the patient's family and to his physician, related to his marked confusion, severe impairment of memory and confabulation. The patient himself had no significant complaints and little insight into his disease. In some cases, the severe memory disturbances may be present without any definite evidence of confabulation. Not only the retentive memory for new material was impaired but also the patient's distant memory was also significantly impaired. In such cases with severe impairment of memory the prognosis for a complete recovery of mental status is very poor. The diplopia and nystagmus, as expected, resolved significantly with treatment with thiamine. The ataxia of gait, which had been present early in the case, had apparently resolved by the time of transfer from his local hospital. A significant peripheral neuropathy, mainly distal sensory, was present related to multiple B vitamin nutritional deficiency.

In many cases, the state of confusion in Wernicke's encephalopathy is preceded by or accompanied by a period of delirium tremens indicating alcohol withdrawal. The use of intravenous glucose feedings without supplemental intravenous thiamine during such a withdrawal state may actually increase the requirements for thiamine, thus exacerbating the thiamine deficiency state. For this reason, all patients under treatment for alcohol withdrawal (or admitted to the hospital with a recent past history of alcoholism) should be treated with high dosage vitamin therapy as well, on the presumption that they are candidates for nutritional deficiency.

A case of transient global amnesia is presented in case 30-2 below.

Case 30-2: This 55-year-old, right-handed, white male, college professor, awoke at 3:00 a.m. on the morning of admission in an uneasy and restless state. He asked his wife what day it was but then did not recall what she had told him. He did not know the month, kept repeating himself and asking the same questions. His wife arranged for him to be seen early in the morning by his family physician who lived a short distance away. The patient, who was familiar with the route, was unable to find his way there. When he arrived at the doctor's office, he was unable to explain why he had come. The patient apparently had forgotten about the incidents, which had occurred earlier that morning. He had no recollection that he had a grandchild born three weeks before. He could remember no significant events from this 3-week period prior to the onset of his illness. The patient's more remote recall and other intellectual capacities remained intact. The patient drove into Boston later that day but became lost despite the usually familiar route.

The patient had a past history of gout with an elevated serum uric acid level.

Neurological examination: Findings were essentially limited to the mental status examination.

When examined in the early afternoon, the patient was beginning to regain some of his ability to retain new information. The patient was generally oriented to person and place. However, he was disoriented for the day and month but was oriented for the year. The patient's store of information was quite intact suggesting a highly intelligent person.

The patient had marked difficulty with delayed recall. He could recall none of the 4 objects after 5 minutes. He could not remember any of the three test phrases given to him when asked about these 5

minutes later. He did recall in a vague manner that a memory test had been given him. As regards recent memory, the patient was unable to remember his visit to his family physician earlier in the day. Digit retention, however, was relatively well preserved; 6 forward and 5 backward. The patient had no defects in calculation. There was no evidence of a constructional apraxia. Language function was entirely intact.

Clinical diagnosis: Probable transient global amnesia

Laboratory data:

1. Complete blood count, serology, blood urea nitrogen, total cholesterol, uric acid skull and chest X-rays, EEG and complete CSF were all within normal limits.
2. The *brain scan* demonstrated a small area of increased uptake of radioisotope (Hg197) in the left temporal region.

Subsequent course: Over the several hours following admission, the patient gradually regained his ability to retain new information and to recall the events of the preceding 3 weeks, the more remote events being recalled first. The memory for the events of the day prior to admission was regained last. This pattern is referred to as a shrinking retrograde amnesia. The specific events that occurred on the morning of admission were never recalled. The following morning delayed recall was four-out-of-four objects after 8 minutes. The patient's mental status and neurological examination were otherwise within normal limits. A repeat brain scan, 3 months after the episode demonstrated considerable improvement, and all brain scan findings had resolved at 5 months. No additional episodes occurred during the one-year after the acute episode.

Comment: The patient's main deficit was in learning new information (anterograde amnesia) with the old stored long-term memory information still intact. During the episode there was a retrograde amnesia that initially extended back for three weeks. As recovery occurred, this retrograde amnesia disappeared. These relatively recent past memories were intact but transiently not accessible. The labile stage of long-term memory has been estimated to be a matter of 20-180 minutes. This case suggests that there is not a sharp border between the labile more recent stage and the remote stage of long-term memory or perhaps of the ability to access those memories. The patient could not remember what happened during the episode. That is suggestive of mesial temporal lobe involvement, in this case left hippocampal region in dominant hemisphere. The ability to perform calculations and language functions was otherwise intact. This would suggest that lateral temporal areas were not involved. The electroencephalogram was normal and consistent with such a lack of involvement of the lateral aspects of the cerebral hemispheres. Occasionally, the EEG will demonstrate a minor focal involvement of the temporal lobe. More often, as in this case, the study is normal. CT scan and MRI when performed are usually unremarkable. SPECT scan might well indicate transient focal involvement as indicated above. The brain scan in this case did suggest a transient abnormality, which would be consistent with an area of ischemia/ infarction, which resolved over the succeeding months. Such an episode must be distinguished from episodes of amnesia, which may occur in relation to, and following a temporal lobe seizure.

The effects produced by electrical stimulation of the hippocampus may also occur as relatively selective ictal and postictal phenomena in a complex partial seizure originating in mesial temporal lobe structures as illustrated in case history 30-3 which follows. Focal temporal lobe seizure phenomena were followed by a period of impaired recent memory with an inability to record new memories.

Case 30-3: This 68-year-old, white male one year prior to valuation fell, striking his occiput and transiently losing consciousness. Except for a persistent defect in his sense of smell, the patient had no apparent neurological defects following this injury. Approximately six months later, the patient had the first of a series of recurrent episodes of amnesia. These episodes occurred most often on awakening. On some, but not all, occasions the episodes were preceded by a sensation of gastric upset, a strange odor and a sensation of familiarity (*déjà vu*). The episodes of total amnesia would last 30 to 60

minutes. There would then be an impairment of memory for approximately one to two days. The patient was said during the episode of total amnesia and during the subsequent episode, to behave in an otherwise normal and rational manner. For example, he would be able to converse with his wife and others. During the episodes, he was said to be unable to remember tasks, which his wife had asked him to do during that day. A significant impairment of retentive memory would be apparent to his wife and to others. His memory for more distant and remote events was also impaired to a variable but lesser degree. The patient would then regain memory progressively over the course of the next one to two days. Apparently, memory was not regained in any orderly pattern from recent to remote or vice versa. The patient at no time had any abnormal movements suggestive of a generalized convulsion.

No automatisms had been noted and to others the patient would appear fully conscious during the episodes.

Neurological examination:

1. *Mental Status*: The patient was oriented for time, place, and person. Delayed recall was intact. The patient could remember 4-out-of-5 objects in 5 minutes. Remote memory was intact. Digit span was slightly impaired at 6 numbers forward and 4 in reverse.

2. *Cranial Nerves*: All areas were intact with the exception of cranial nerve I where olfaction was decreased for the odor of coffee grounds, bilaterally.

3. *Motor system, reflexes and sensory system*: *Intact*.

Clinical diagnosis: 1) Complex partial seizures (most likely post traumatic) with episodes of amnesia as an ictal and or post ictal phenomena. 2) Post traumatic anosmia.

Laboratory data: 1. *Skull X-rays, routine EEG, radioactive brain scan, fasting blood sugar and glucose tolerance tests, pneumoencephalogram and spinal fluid examination were normal..*

2. *The EEG obtained after a period of sleep deprivation revealed occasional multifocal spikes during sleep in the right anterior temporal area and to a lesser degree the left frontal-anterior temporal area.*

Subsequent course: The patient was treated with anticonvulsant medication. The episodes continued to occur once per month but were now of shorter duration, lasting only 15 to 20 minutes. The impairment of memory was less marked and involved only the ability to learn new material without prolonged periods of retrograde amnesia. After 8 months no additional episodes occurred. When seen three years after initial evaluation his neurological examination was unremarkable except for the defect in olfaction suggesting that more serious progressive disorder was not present.

Comment: In this case the episodes experienced by the patient could have posed a diagnostic problem if the occasional warning symptoms of olfactory aura, déjà vu and epigastric sensation had not been present. Most of the episodes experienced by the patient were not preceded by these clear symptoms of temporal lobe seizure, but were instead simply episodes of amnesia. Though the actual temporal lobe seizures apparently lasted only a matter of 30 to 60 minutes, some degree of impairment of memory was present for one to two days following the episode.

The etiology of the seizures in this case must relate to the patient's preceding head trauma. The loss of olfactory sensation following the trauma suggested that this trauma was of sufficient nature to tear the nerve filaments passing through the cribriform plate to the olfactory bulb on the orbital surface of the frontal lobe. Such trauma does produce contusions of the orbital frontal cortex and epileptogenic foci may result. We may also assume that this trauma may have been sufficient to produce some minor contusion of the anterior poles, inferior and medial surfaces of the temporal lobes against the bony walls of the middle fossa with a resultant scar and epileptogenic focus. The fact that olfactory hallucinations and the experience of déjà vu preceded some of the amnesic episodes

would make the temporal origin more likely. The routine electroencephalogram is not reliable in the detection of seizure discharges in either the mesial temporal or the orbital frontal areas. The electroencephalogram showed significant areas of discharge in the temporal lobe only under conditions of sleep deprivation which acts to precipitate seizure discharges in individuals who have an underlying predisposition for seizure discharges. For additional discussion, see Gallassie, et al (1988), Hughlings-Jackson (1889), Tassinari, et al (1991).

The following case history presents an example of presenile dementia.

Case 30-4: This 64 year old right handed white male formerly an administrative assistant for the veteran's administration and newspaper distributor was initially evaluated for impairment of recent memory. Initially, the wife indicated this had been progressive over 4 years, but she was subsequently able to date this back to age 54 years, 10 years previously. A review of his record indicated that another neurologist of our department had seen him 4 years previously with similar memory complaints. The neurological examination at that time demonstrated no focal features, but his mental status examination indicated an inability to recall any of four objects. There were minor changes in time orientation: his date was off by one month and the day of the week was incorrectly stated. In the interim, the memory problems had progressed. In addition there were now personality changes. He no longer participated in those activities which had previously been of great interest. He was also having some problems in finding words. There were no problems in the activities of daily living and he was not getting lost in his familiar environments.

Family history: There was no history of neurological disease in his siblings or father. His mother had died at the relatively young age of 48 of cancer.

Neurological examination:

1. *Mental status:* The mini mental status exam indicated a total score of 19 out of 30. He had particular problems in time orientation. He was able to do the immediate recitation of three objects and of a test phrase but could remember none of these on a delayed recall test. He also had difficulty copying a test figure. The patient was often tangential in his answers and demonstrated inappropriate joking.

2. *Cranial nerves:* intact

3. *Motor system* was intact as regards strength, gait and cerebellar functions. However premotor /frontal lobe functions were abnormal. He had a release of the instinctive grasp reflex. He had difficulties performing the Luria three stage motor sequences demonstrated by the examiner (slap thigh with palmar surface, then with ulnar edge of hand and then with ulnar surface of closed fist.).

4. *Reflexes:* deep tendon stretch reflexes, and plantar responses were physiologic.

5. *Sensory system:* intact

Clinical diagnosis: Alzheimer's disease

Laboratory data:

1. All screening studies such as *complete blood count, sedimentation rate, B -12, folate, thyroid functions and serological test for syphilis* were normal.

2. *CT scan* demonstrated significant dilatation of the temporal horns. (This change in the size of the temporal horns suggested hippocampal atrophy.) In addition there was a general increase in lateral ventricular size. There was also blunting of the angles of the frontal horns.

3. *SPECT scan* was within normal limits except for a slight decrease in perfusion in the left parietal region.

Subsequent course: The patient was begun on treatment with 5mg per day of donepezil (Aricept) a centrally acting acetylcholinesterase inhibitor and high dosage of vitamin E (a possible antioxidant). . When re-evaluated at one month, his family reported improvement in memory; the mini mental status exam score was now 21 out of 30. At 10 weeks into treatment, the score had increased to 25 out of 30. There was particular improvement in the delayed recall section of the exam. There was however no change in personality. He still showed inappropriate jocularity when he could not answer a question and at times was tangential in his answers. Administration of the acetylcholinesterase inhibitor temporarily improved memory function for approximately 18 months. However by age 67, behavioral disturbance (agitation, aggression nocturnal wandering and sexual disinhibition) and urinary incontinence were becoming major problems. He could no longer be managed in his home and day care setting despite the

use of haloperidol. This resulted in his placement in a nursing home. At age 69, he was now described as relatively nonfluent, and very confused. He recognized his own name and occasionally recognized relatives but showed no other response to questions. He was usually restricted to a wheel chair, could walk with assistance. He was “stiff and afraid” when requested to walk.

Comment: This patient presents a typical example of the slowly progressive course of Alzheimer’s disease. Memory problems had begun insidiously at approximately age 54. Initially these problems in the older adult may be attributed to a benign age related process in which there is minor difficulty in accessing information such as names although the ability to incorporate new information is still intact (“wait a minute, the name or word will come to me eventually”). When evaluated by a neurologist at age 60, the major finding was a severe deficit in delayed recall suggesting a process at the level of the hippocampus. The patient failed to return for follow up at that time and when he did reappear at age 64, he was now beginning to show changes in personality and frontal release signs suggesting involvement of the prefrontal and premotor areas. The use of a cholinesterase inhibitor produced some improvement in memory for about 18 months but had little effect on the changes in personality and behavior. The use of this agent has been estimated to postpone nursing home placement by approximately 15 months. Eventually by age 69, fifteen years after disease onset, gait and other motor functions were seriously affected.

The rationale for the use of cholinesterase inhibitors is based on the demonstration by Drachman and Leavitt (1974) that administration of scopolamine, an anticholinergic drug that crosses the blood brain barrier, would produce a transient syndrome similar in many respects to memory and cognitive changes of Alzheimer’s disease. Subsequent studies demonstrated a marked loss of neurons in the basal forebrain nucleus of Meynert, a major source of cholinergic fibers to the cerebral cortex. (Whitehouse et al 1981 Rogers et al, 1985 editorial of Growden 1992). However, a simplistic cholinergic hypothesis is insufficient to explain all of the features of Alzheimer’s disease. Administration of acetylcholine esterase inhibitors in mild cases (mini mental status score of 10-25) has only a limited value as in the present case. Other neuronal systems are involved (noradrenergic synapses are also involved. hippocampal system is severely involved).

The following case 30-5 provides an example of general paresis producing severe changes in cognitive function and personality.

Case 30-5 : This 59-year-old right-handed white male, cleaning establishment owner, five years prior to evaluation, manifested a personality change - increased rigidity and irritability. He would become enraged over trivial matters many times per day. During the last 1.5 years, this process accelerated. He became more antisocial, unable to interact with employees and customers. His level of comprehension declined. He became more aggressive towards his wife and children. He often manifested frank paranoia and suspiciousness, accusing his wife of unreal, sexual infidelity. During the last 1.5 years, a significant gait disturbance had also developed, with impairment of balance. A slowing in speech and a tremor of hands had developed over the previous year.

The patient had been born in Poland. All significant infections were denied. He had received injections of “liver” and B12 after the war “for anemia” but had received no recent B12 injections.

Neurological examination:

1. *Mental status:* The patient was oriented for time, place and person.

Delayed recall was markedly impaired none of five in five minutes without assistance, one of five with assistance. Repetitions and naming of objects were intact. Distant (remote) memory was good. The patient could list all major world leaders during World War II and all assassination attempts.

The patient was often tangential in his responses and often initiated irrelevant conversations.

Serial 7 subtractions could not be done but the patient could reverse 12 months of the year.

Abstract reasoning for similarities was poor.

He often got up from the bed and looked outside the curtain, checking the activities of his roommate.

2. *Cranial nerves:* Pupils were small, 2 mm., and irregular but did respond to light.

Twitching and grimacing of face, eyelids and tongue occurred. He also had a lid lag.

3. *Motor system*: Strength was intact. Gait was wide-based, with a positive Romberg test. The patient was quite tremulous with occasional myoclonic jerks. He could not do rapid alternating movements.

4. *Reflexes*: Deep tendon reflexes were normal (2+) in the upper extremities, trace at patellar and absent at Achilles. Plantar responses were flexor, bilaterally. There was no release of the grasp reflex. Other frontal release signs were absent.

5. *Sensory system*: Pain, touch and position sense intact. Vibration was markedly decreased at toes, and ankle with minor preservation at knees.

Clinical diagnosis: Progressive dementia and personality change. Multiple entities to be considered including (1) the combination general paresis and tabes dorsalis, (2) B12 deficiency, (3) frontal lobe tumor, (4) frontal dementia and (5) Lewy body dementia

Laboratory data: The abnormal findings included:

1. *Vitamin B12 level* was borderline low at 209 picograms/ml., *Schilling test*, however, demonstrated normal absorption (25.4% excretion of radioactive B12 in urine).

2. Serum serological test for syphilis (RPR) was reactive with the more specific FTA markedly reactive.

3. *Cerebrospinal fluid*: 98 white cells were present - all lymphocytes. CSF protein was elevated to 116 mgs.% (normal <45 mgs.%). Sugar was low at 44 mgs.% with a simultaneous blood sugar of 90. Spinal fluid serological test for syphilis (VDRL) was positive.

4. *CT scan* showed mild frontal and temporal atrophy

Subsequent course: The patient was hospitalized for two weeks and received high dosage intravenous penicillin therapy, three million units every four hours for 10 days (18 million units per day).

When seen again 2 months later, the patient and his family reported that gait and coordination had significantly improved. Memory and personality had not improved. He still had episodes of agitation and irritability. Reflex and sensory findings were unchanged. The patient had been inconsistent in taking any medication such as haloperidol, aimed at altering his agitation.

He failed to return again for 18 months. Paranoid ideation had become more prominent. He could no longer manage his fiscal affairs. Orientation and delayed recall were intact. There was minor tremor of the hands and an unsteadiness of gait. Romberg was positive although position and vibratory sensation were intact. Serum serology was now negative. Lumbar puncture now indicated no significant cells, a normal protein.

Subsequently he did require hospitalization for renal failure secondary to enlarged prostate and a neurogenic bladder. Spinal fluid VDRL and serum RPR serological tests for syphilis, were both nonreactive. Serum FTA ABS - a much more specific and more sensitive test for previous syphilis was still 3+ reactive.

Telephone follow-up 11 years after the initial episode indicated that personality and cognitive changes had essentially leveled off, irritability and hostility were less. He had no urinary problems. He was unsteady in walking, but was still able to drive small distances and was living at home. Additional information approximately 20 years after the initial evaluation indicated that he spoke very little, he no longer demonstrated agitation. His mobility was more limited. Of interest, one pupil no longer responded to light but did respond to accommodation. CT scan demonstrated greater atrophy.

Comment: This patient had clinical manifestations predominantly related to general paresis. Both the history and the examination also provided evidence of tabes dorsalis. Penicillin therapy resulted in a non-active state, as regards serum serology and any cellular activity in the spinal fluid. However, the damage to cerebral cortex was not reversed and continued to provide a significant problem, as regards personality function. Thus, once cognitive function has been altered, due to damage to and loss of neurons, the changes in memory and personality may be persistent. Disturbances of frontal lobe and limbic system function once initiated may continue to evolve.

Moreover once the patient reaches the late 60's and the 70's, apparent progression of neurological changes in memory and other cognitive functions may occur related to the combined effects of the previous acquired lesions of general paresis and the effects of even mild Alzheimer's disease. A double hit has occurred.

The following case provides an example of a patient whose initial symptoms related primarily to a severe alteration in personality function and social interactions. Features of Parkinson's disease were apparent on her examination. Diagnosis was uncertain but diffuse Lewy body dementia should be considered.

Case 30-6: This 60-year old, right handed separated white housewife, residing in a nursing home, was referred for evaluation of problems in walking, progressive behavioral change and memory disturbance. Six years previously at age 54, a change in behavior was first noted by her family. She began to accumulate papers about the house. She would leave the shades down all day, and expressed fears that people would break into her house. As a result, she became isolated from her neighbors and friends. Shortly there after, she made repeated phone calls to the local police and it was apparent that she was confused. After investigation, the police had to break into the house and take her to an emergency room. In the emergency room she was described as confused and frightened. Paranoid ideation was prominent with considerable self-referral ideation. Thought process was described as tangential, with considerable perseveration. There was poor insight and judgment was impaired. She was confused as to time and place and she could recall two of three objects in 5 minutes. She had great difficulty with serial sevens, often losing track of the number to be subtracted. Judgment and insight were poor. She would read a book by rapidly turning the pages, but then had little recall of what she had read. With treatment with haloperidol, lability of mood and paranoia decreased. A CT Scan demonstrated "mild cortical atrophy". The patient was then transferred to a nursing home with a diagnosis of Alzheimer's Disease. In retrospect, a gait problem had also been present in January 1984, about the time that her symptoms had begun, and prior to the use of haloperidol.. The patient was walking flexed with small steps. These gait problems progressed so that she was unable to stand up from a chair and was unable to walk. She had become fearful of walking.

Family History - Indicated parents died at ages 70-80 years, without neurological disease. A sibling was age 79 without neurological disease.

Neurological examination:

1.*General:* A thin female appearing older than her stated age. She sat in a wheelchair with little facial expression and with little body movement. She was passive in the interview situation -allowing her husband to provide many answers.

2.*Mental Status:* She was oriented to the year but when requested to provide the month and day, she answered "it is the beginning of school time". As regards the location, she gave the name of the town where she formerly lived but could not name the town where the nursing home was located. She did name the nursing home and then said "its a jazzy place with more facilities, most of the people there are nice, some just sit around".

Asked to describe herself, she said, "I am nothing, I can't even take care of my child". She was, however, able to provide the name of her only daughter, now grown, and was able to indicate that the daughter had been born in 1945 in Philadelphia (all of which the husband verified as correct).

Asked to indicate her own birthplace and birth date, she indicated she herself had been born at home in Fitchburg in 1925 and then added, "I imagine everything has been tossed out there". When I asked "what had been tossed out?", she provided a tangential answer, "I do not know you" and then rambled on to a conversation topic about her husband's trip to Turkey on a "Fulbright" - some time in 1960 or 1970.

Delayed recall even with multiple choice assistance was zero out of five in five minutes. For serial seven subtractions, 100 - 7 "might equal 86 or might equal 55". She could name 3 out of 5 objects, could do repetitions, could write her name but not her address and refused to draw a house (? unwilling, ? unable).

3. *Cranial Nerves:* Intact except for a tremor of the closed eyelids and a positive glabellar sign. There was a lack of facial expression.

4. *Motor System*: Strength was difficult to assess, but appeared intact when maximal effort was made. Significant akinesia and bradykinesia were present. There was cogwheel rigidity of minor degree at wrist and elbow. There was variable resistance at hip and knee, which had primarily the character of frontal lobe type "Gegenhalten".
The patient had to be assisted to the standing position from her wheelchair. In the standing position, initially, her feet appeared to be stuck to the floor, as in a magnetic foot syndrome. Eventually, she was able to take small shuffling steps, as assistance was provided by holding her outstretched hands lightly. If unsupported, she tended to fall backwards - whether standing or walking.
 5. *Reflexes*: Deep tendon reflexes were physiologic at 2+ except for Achilles - 1+. Plantar responses were equivocal. There was marked release of the grasp reflex.
 5. *Sensory system*: Pain and vibration were intact. Position sense could not be tested.
- Clinical diagnosis:** Lewy body dementia , or a variant of frontal dementia.

Laboratory data:

1. *Metabolic surveys* were not remarkable in terms of electrolytes, BUN, creatinine, glucose, hepatic functions, vitamin B12, folate levels and thyroid functions.
2. Routine serum serological test and FTA absorption for syphilis were negative.
3. *Sedimentation rate* was moderately increased to 53 mm/hr. *Alkaline phosphatase* was elevated to 272 and bone scan suggested possible Paget's Disease.
4. *EEG* demonstrated a slow dominant awake activity of 6-7 Hz (compared to normal alpha rhythm of 8-13 Hz). In addition, rhythmic bilateral delta slow wave were present, most prominent in the frontal recording areas.
5. *CT Scan*, demonstrated marked cortical atrophy with enlargement of sulci, ventricular system and cisternal spaces.

Subsequent course:

The patient continue a slowly progressive course to the present time. According to her primary physician, she is essentially restricted to bed. She remains, from a medical standpoint, relatively clear of other medical problems and complications - at age 67, 13 years after onset of the disease.

Comment: The diagnosis in this case is uncertain . The patient at age 54 had the onset of a significant change in behavior which resulted in major problems in interpersonal relationships. Initially, she had been able to live by herself in her small seaside community. Eventually, however, the frequent night calls to friend, neighbors, and the police, resulted in her coming to medical attention. Even at that point, the patient's separated husband, who visited her frequently and supported her, appeared unaware of the patient's confusion and memory deficit. The husband had considerable difficulty appreciating the degree of disability. Such a pattern is not unusual.

In contrast to the previous case histories of this chapter, the memory problems were far beyond the selective involvement of recent memory seen in Wernicke's or hippocampal lesions. Moreover, a more diffuse involvement of other cognitive functions was present. As the disease progresses, motor aspects become prominent, indicating the effects of involvement of frontal and premotor areas. Mild "Parkinsonian" features may appear, due to either the medications employed (neuroleptic agents such as pheno thiazides, haloperidol, etc.) or to alterations in the frontal premotor basal, nuclei circuits or to loss of neurons, at the level of S. nigra or basal nuclei. Note however that the gait problems occurred prior to the use of haloperidol. The CT scan did not demonstrate the focal atrophy seen in frontotemporal dementia .Therefore the most likely diagnosis might be diffuse Lewy body dementia since personality changes were most prominent at onset, and Parkinsonian features developed early in the disease course. Contrast this case to the Alzheimer disease patient of case 30-4 in which the initial problems were restricted to changes in memory.

When seen at age 60 this patient was clearly late in her disease course. As indicated, remedial causes of the syndrome of progressive dementia must be ruled out. The effects of medication must be considered. Moreover, however, any masking depression should be treated. At this point in time, no specific therapy to reverse the progressive course of the disease is known.

Case 30-7: This 74-year-old right-handed widow presented to the emergency room at St Vincent hospital on 2-19-02 with an 8-10 week history of worsening memory problems. In December 2001, accompanied by her boyfriend she made her annual trip to Florida. Although she had been in her usual state of independent living prior to her departure, she was found to have serious problems with

memory on arrival. She was unaware as to where she was. In a telephone conversation with her daughter, “she was talking nonsense”. During the next 2 months, memory and word finding continued to deteriorate. She was taken to the emergency room of the local hospital in Florida where a CT scan without contrast on 02/07/02 demonstrated mild cortical atrophy but no acute process. Her son drove to Florida and found that her memory was poor and her conversation did not make sense. “My husband is in the service: my mother died last year.” However she could play cards with her grand daughter. Her gait was slow and stooped. She had urinary incontinence on her way to the bathroom.

She had no history of alcoholism and took various vitamins and herbs.

Family history: her brother had died of a brain tumor of unknown type.

Neurologic examination: The positive findings were the following:

1. *Mental status:* The patient was awake and alert. Overall Mini-Mental Status Score was 19/30. The major problems were in orientation and in delayed recall. She was able to indicate that she was in a hospital in Massachusetts. And the date was February. She registered 3 objects but could recall any in 3 minutes. She was however able to read, name objects, follow instructions, spell “world” backwards and copy a figure. She was unable to draw a clock with the hands set at 11:10.

2. *Cranial nerves:* intact

3. *Motor system:* Although strength and tone were normal, her gait was broad-based and shuffling.

4. *Reflexes:* Patellar and Achilles reflexes were absent but plantar responses were flexor.

5. *Sensory system:* Intact.

Clinical diagnosis: 1) Subacute dementia: etiology uncertain possibly of Alzheimer’s or Lewy body type. Various entities such as chronic subdurals, tumor etc to be ruled out 2) Peripheral neuropathy, most likely etiology at this age diabetes mellitus.

Laboratory data:

1. *Basic CBC and chemistries:* Normal except for an elevated fasting glucose.

2. *CT scan (Fig 30-10):* An enhancing 2.75 cm tumor with a necrotic center was present in the thalamus at the level of the upper third ventricle. There was bilateral involvement of the anterior and medial thalamus but with no involvement of the posterior thalamus or hypothalamus. The study suggested a lymphoma or glioblastoma

Subsequent course *Stereotaxic biopsy of the right thalamus:* Frozen section raised the question of a lymphoma or glioblastoma but special immunological stains were consistent with a glioblastoma. Necrosis and endothelial hyperplasia were present. The patient was treated with dexamethasone and radiotherapy with improvement in gait.

Comment: This patient presents an unusual cause of a progressive alteration in memory. As indicated earlier in this chapter those patients with Wernicke’s encephalopathy who progress to the Korsakoff syndrome had persistent pathology in the medial and anterior thalamus with sparing of the posterior thalamus. In this case the pathology was a rapidly progressive glioblastoma multiforme. As discussed above, an occasional patients, glioblastomas may also produce dementia and a change in personality by infiltrating the prefrontal areas and corpus callosum. Occasionally a patient with a more diffuse neoplasm gliomatosis cerebri may also present with a similar syndrome of dementia which may mimic Alzheimer’s disease. These are however rare causes compared to the more frequent degenerative disorders.

COMPLETE CASE HISTORIES FROM TEXTBOOK: *INTEGRATED NEUROSCIENCES*
PART IV. CASES; CEREBRUM VISION, DISEASES, MEMORY

CHAPTER 23: VISUAL SYSTEM

The following case is an example of a lesion involving the optic nerve, anterior to the optic chiasm.

Case History 23-1 (Fig 23-8).

This 53-year-old white right-handed housewife was referred for evaluation of progressive right-sided supraorbital headache of 23 years duration and decreasing acuity in the right eye. The loss of acuity had progressed to the point of almost total unilateral blindness. During the 3 years before admission, intermittent tingling paresthesia had been noted in the left face, arm, or leg. About 1 year before admission the patient had a sudden loss of consciousness and was amnesic for the events of the next 48 hours. She was hospitalized, but no explanation for the episode was clearly established, although cerebrospinal fluid protein was reported to be elevated (230 mg/dl).

The patient and her family reported some personality changes over a period of several years, including a loss of spontaneity and increasing apathy.

General Physical Examination: Unremarkable except for a minor degree of proptosis (downward protrusion of the right eye).

Neurologic Examination:

1. *Mental Status*: The patient was, in general, alert but at times would become lethargic. Her affect was flat. At times, she would laugh or joke in an inappropriate manner.
2. *Cranial Nerves*: There was anosmia for odors, such as cloves, on the right and a reduced sensitivity on the left.

Marked papilledema (increased intracranial pressure with protrusion of the optic disk and venous engorgement due to obstruction of the normal flow of CSF) was present in the left eye.

Pallor of the right optic disc was present, indicating optic atrophy. Visual acuity in the right eye was markedly reduced. The patient had only a small crescent of vision in the temporal field of the right eye, where only vague outlines of objects could be seen. A slight left central facial weakness was present.

3. *Motor Systems*: Intact although movements on the left side were slow.

4. *Reflexes*: A release of grasp reflex was present on the left side.

5. *Sensory system*: Intact

Clinical diagnosis: Subfrontal meningioma arising from olfactory groove or inner third sphenoid wing.

Laboratory data:

1. *Skull* x-rays demonstrated erosion of the dorsum sellae. Special lamniograms demonstrated hyperostosis of the sphenoid bone (planum sphenoidale) suggesting a meningioma originating from the sphenoid bone.

2. *EEG* demonstrated focal 2-4 Hz slow waves in the right anterior temporal and anterior lateral frontal area.

3. *Brain scan (H_g 197)* revealed a heavy uptake of isotope in the right posterior subfrontal area.

4. *Arteriograms* indicated that the anterior cerebral arteries were shifted backwards, posteriorly and the left. A tumor blush was present on the venous phase in the right subfrontal area extending back to the optic nerve groove (Fig 23-8). These findings were felt to be most consistent with an olfactory groove meningioma.

Hospital course: Dr. Samuel Brendler performed a bifrontal craniotomy which exposed a well-encapsulated smooth tumor attached to the medial third of the sphenoid wing. After intracapsular removal of 90 to 95% of the tumor, the right optic nerve could be visualized. The small portion of the tumor attached to the bone could not be removed because of considerable bleeding from the bone. Examination 4 months after surgery, indicated right anosmia and right optic atrophy were present.

Comment

If one considered only the patient's primary complaint, decreasing vision in the right eye, and the findings of right optic atrophy and left-sided papilledema (Foster-Kennedy syndrome), then the most probable diagnosis was inner-third sphenoid meningioma. The preservation of a small crescent of vision in the temporal field is consistent with compression of the optic nerve on its lateral surface. By the time of hospitalization, the lesion was quite large and had extended into the subfrontal area, producing anosmia on the right and some changes in personality. At this point, the various diagnostic studies suggested only a subfrontal mass and did not clearly differentiate between an olfactory-groove meningioma and a sphenoid-wing meningioma. One might suggest, in retrospect, that the degree of involvement of the right optic nerve was much more pronounced than the changes in prefrontal functions, and therefore, the inner-third sphenoid-wing location was more likely.

The surgical approach in any case was the same. The eventual recovery of vision in such cases is uncertain because the effects of compression often are not reversible.

The following case 23-2 provides an example of a macroadenoma of the pituitary producing a bitemporal adenoma..

Case 23-2. Patient of Dr. Martha Fehr. This 45-year-old man had an 18-month history of a progressive alteration in vision. He was unable to see objects in the right or left periphery of vision. He was concerned that in the process of driving he might hit pedestrians stepping off the sidewalks in the periphery of vision. He had also experienced over 6-8 months, progressive headaches, loss of energy and libido.

Neurological examination: Normal except for a bitemporal hemianopia.

Clinical diagnosis: Pituitary adenoma compressing the optic chiasm.

Laboratory data:

1. *Endocrine studies:* all were normal including prolactin, am cortisol, and thyroid functions.

2. *MRI:* A large macroadenoma measuring 3 cm in diameter extended outside of the sella turcica to compress the optic chiasm (fig. 23-11).

Subsequent course: Dr. Gerald McGuillicuddy performed a gross total trans sphenoidal resection of the tumor, with a significant improvement in vision. Three years later, the patient again had visual symptoms and eye pain. MRI scans indicated regrowth of tumor with possible impression on the right optic nerve. He was treated with radiotherapy.

Comment: Note that males are more likely to present with large pituitary adenoma compressing the optic chiasm. Women are more likely to present with microadenomas or small macroadenomas since they are more likely to be seen at an earlier stage due to an initial complaint of amenorrhea. Thus complaints of decreased libido in men are likely to be mentioned only in retrospect and not as an early presenting complaint.

The following case illustrates the effects of a space-occupying lesion in the occipital lobe. One should compare these findings to those reported earlier in Case 23-1, in which there was a lesion in the visual system anterior to the optic chiasm.

Case 23-3: This 47-year-old white, right-handed, real estate salesman was referred for evaluation of headache and visual disturbance. One month before admission the patient had a cough with some blood present in the sputum (hemoptysis). Five days before admission the patient developed a generalized headache, which was

precipitated by coughing or straining and which awakened him or prevented him from sleeping.

Two days before admission, the patient noted blurring in the left inferior quadrant of his field of vision.

The day before admission, he noted complete loss of vision in this quadrant. On the day of admission, the headache increased, and the patient was unable to see anything in the left visual field.

He had experienced no weakness, no disturbance of memory, and no language disturbance.

Past history was significant. The patient had multiple pulmonary infections, treated with antibiotics.

Neurologic examination:

1. Mental status: Intact

2. *Cranial nerves* were intact, except that blurring of disc margins was present bilaterally, with venous engorgement, indicating early papilledema.

A left non congruous homonymous hemianopia was present (Fig. 23-14A).

3. Motor system: Intact

4. **Reflexes:** *Deep tendon reflexes were slightly more active on the left. The plantar response on the left was extensor that on the right was flexor*

Laboratory data:

1. *Electroencephalogram* was abnormal because of frequent focal 3 to 4 cps, slow waves in the right occipital area and to a lesser degree, in the right posterior parietal area, consistent with focal damage in the right occipital area.

2. *Cerebrospinal fluid* pressure was elevated to 210 mm H₂O. The number of white blood cells was increased to 97 lymphocytes (upper normal limit is 5 to 7 lymphocytes). Protein was increased to 75 mg/dl (upper normal limit is 45 mg/dl). Glucose was 75 mg/dl (normal when compared to blood sugar of 95 mg/dl).

3. Imaging (radioactive brain scan Hg 197) demonstrated an enhanced region in the posterior and medial aspect of the right hemisphere (occipital and adjacent parietal lobes).

Subsequent course: The patient was treated with antibiotics (cephalothin sodium, penicillin, and streptomycin). Visual fields, EEG, and spinal fluid findings improved. Within 3 weeks the field defect had resolved to a non congruous left inferior quadrantanopia (Fig. 23-14B).

Ten days later the patient was readmitted to the hospital with a three-day history of right eye pain, sweats, and chills. Neurologic examination now revealed a recurrence of blurred optic-disc margins, a left homonymous hemianopia and a slight increase in deep tendon reflexes on the left. Imaging studies now revealed a large space-occupying lesion in the right parietal/occipital region, displacing the right lateral ventricle forward and downward.

After 10 days treatment with antibiotics (penicillin and streptomycin), a craniotomy was performed by Dr. Bertram Selverstone. A mass could be palpated medially in the right occipital and adjacent posterior parietal area. The abscess and a large surrounding area of hard granulomatous cortex and white matter were removed. (The etiologic organism was subsequently found to be a *microaerophilic streptococcus*.)

Postoperatively, the patient continued on treatment with penicillin. Follow-up examination 6 months after surgery was normal, except for the left homonymous hemianopia (Fig. 23-14C).

Comment: The rapid evolution of neurologic signs and symptoms in this case; the early development of papilledema, and the progressive changes in the electroencephalogram and brain scan; is consistent with the diagnosis of brain abscess. The primary infection in this case was probably in the lung.

The initial visual symptoms of inferior field involvement (quadrantanopia) suggested that the abscess, in its early stages, involved predominantly the superior portion of the optic radiation in the posterior parietal/occipital area or the superior bank of the calcarine fissure. With progression of the lesion, the entire optic radiation or the entire calcarine cortex was involved. The lesion found at surgery had destroyed or damaged both these areas.

The treatment of a brain abscess requires appropriate pre- and postoperative use of antibiotics. Many of these patients develop focal seizures at some time after successful surgical treatment of the abscess. Although prophylactic anticonvulsant medication, such as diphenylhydantoin (Dilantin), has been routinely administered, the value of such treatment remains unclear.

Note an important negative finding in this case: at no time did the patient experience any language disturbance. Reading and writing remained intact, as did the capacity for to construct drawings. This case involving the right occipital lobe should be compared with Case History 21-2, in which a focal lesion of the left occipital lobe was present.

The following is another example of the effects of a lesion in the occipital lobe with very different consequences than those seen in the previous case. The lesion clearly involved the cerebral cortex producing focal seizure activity.

Case 23-4. (Fig 23-15): This 18-year-old left-handed single white female restaurant employee was referred for reevaluation of a seizure disorder. While living in the south western United States, the patient had the onset of her seizures at age 14 when she had a sequence of five seizures in less than 12 hours. Each began with flashing lights, “like Christmas tree lights,” all over her visual field, plus the sensation that peoples’ faces were moving. She then would have an apparent grand mal seizure. She was hospitalized. The neurological examination was reported as normal. An electroencephalogram report noted occasional focal sharp and slow waves in the left hemisphere. The CT scan was interpreted as essentially within normal limits. In retrospect, there was a question of some mottled hypodensity in the left occipital area, not clearly distinguished from artifact. The patient was treated with carbamazepine (Tegretol), 400 mg in the morning, and 230 mg at hour of sleep. In the interim, she apparently had done quite well with no additional grand mal seizures. She had rare episodes of “fear attacks,” which would last 23 to 25 minutes. The last attack had occurred 2 years ago, but as recently as two months ago, she had had one episode of flashing lights. A recent EEG was normal.

Past history was negative, except her birth weight was ten pounds, three ounces, and there was a problem of breathing at birth. She had always done poorly in school. Her family history did not suggest possible causes for a seizure disorder.

Neurologic examination: Normal.

Clinical diagnosis: Seizures of focal origin occipital cortex, (flashing lights and movement of the lights) probably left hemisphere based on the reports received of the EEG. There was subsequent spread of discharge into the temporal lobe based on the report of “fear attacks”

Subsequent course

The patient did well for 3 years then had a recurrence of a generalized convulsive seizure possibly related to omission of medication. Six weeks later, she reported two additional episodes characterized by flashing lights, then movement of the lights away from a center circle, then dizziness, then a

sensation of unreality. She also had other episodes of feeling unreal accompanied by fear. There were no olfactory hallucinations and no other visual or auditory hallucinations. The neurologic examination now demonstrated a minor right central facial weakness not present previously.

Laboratory data:

1. *EEG*: remained normal.
2. *MRI scan*: now revealed a small tumor at the left occipital pole with surrounding edema (Fig. 23-15). On CT scan, this tumor appeared partially calcified but did show enhancement. Angiograms suggested tumor vascularity of a type seen with meningiomas.

Subsequent course: Dr. Bernard Stone removed a discrete encapsulated tumor that appeared to be a meningioma. Subsequent microscopic examination, however, indicated a rare type of indolent follicular adenocarcinoma of the thyroid, which sometimes spreads as a single lesion to brain and remains quiescent for many years. In the postoperative period, a non-congruous right-inferior-field defect was present (partial quadrantanopia). The blood level of thyroid-stimulating hormone (TSH) was elevated. A thyroid nodule was found. A thyroidectomy was performed, and thyroid replacement medication was prescribed. No additional seizures were observed over the next 18 months. A metastatic lesion in the lumbar vertebral body subsequently appeared.

Comment: This patient presented many of the features of focal seizures arising in the occipital cortex: flashing lights, movement of objects and secondary generalization. Some of the seizure phenomenology such as “fear attacks,” dizziness, and “feeling unreal” suggested that spread into the temporal lobe was sometimes occurring. The student should now compare and contrast the cases presented in the previous chapter on the limbic system to this case to be able to note the differences seen after lesions in these adjoining cortical regions.

CHAPTER 24: SPEECH, LANGUAGE FUNCTION, APHASIAS, AGNOSIAS, APRAXIA

The following case, 24-1 presents an example of a selective non fluent aphasia of aphasia. An embolus to the superior division of the left middle cerebral artery produced marked weakness of the face tongue and distal right upper extremity and a severe selective nonfluent aphasia. The

hand weakness rapidly disappeared, the right central facial weakness, an apraxia of tongue movements and some expressive difficulties persisted.

Case 24-1: This 55-year-old, right-handed white housewife while working in her garden at 10:00 a.m. on 04-15-69, the day of admission suddenly developed a weakness of her right side and was unable to speak. Apparently, the right-sided weakness affected predominantly the face and arm since the patient was able to walk. The past history was significant. In 1960, nine years previously, the patient had been admitted to the hospital with a three-year history of progressive congestive heart failure secondary to rheumatic heart disease (mitral stenosis with atrial fibrillation). An open cardiectomy was performed with a mitral valvuloplasty (the valve opening was enlarged). A thrombus found in the left atrial appendage was also removed. Postoperatively, the patient was given an anticoagulant, bishydroxycoumarin (Dicumarol). Although atrial fibrillation continued, she did well until the day of admission. Prothrombin time at the time of admission was close to normal; that is, the patient was not in a therapeutic range for anticoagulation.

General physical examination: Blood pressure was moderately elevated to 170/80. Pulse was 110 and irregular (atrial fibrillation). Examination of the heart revealed the findings of mitral stenosis: a loud first sound, a diastolic rumble and an opening snap at the apex as well as the atrial fibrillation.

Neurological examination:

1. Mental status and language function:
 - a. The patient was alert.
 - b. She had no spontaneous speech and could not use speech to answer questions and could not even use yes or no to provide answers. She could not repeat words.
 - c. The patient was, however, able to indicate answers to questions by nodding (yes) or shaking her head (no), if questions were posed in a multiple choice situation. In this manner it was possible to determine that she was grossly oriented for time, place and person.
 - d. The patient was able to carry out spoken commands and simple written commands, such as, "hold up your hand, close your eyes." However, she had significant difficulty in performing voluntary tongue movements (such as "wiggle your tongue"; "stick out your tongue") on command.
2. Cranial nerves:
 - a. The patient tended to neglect stimuli in the right visual field.
 - b. She was unable to look to the right on command although the head and eyes were not grossly deviated to the left at rest.
 - c. A marked right supranuclear (central) type facial weakness was present.
 - d. The patient had difficulty in tongue protrusion. When the tongue was protruded it deviated to the right. The patient was unable to wiggle the tongue.
3. *Motor system:* Strength: there was a marked weakness without spasticity in the right upper extremity, most prominent distally. Some shoulder movements were possible; no hand or finger movements could be made. There was a minor degree of weakness involving the right lower extremity (75 percent of normal).
4. Reflexes:
 - a. Deep tendon stretch reflexes were increased on the right in the arm and leg.
 - b. Plantar responses were both extensors; more prominent on the right.
 - c. The abdominal reflex was absent on the right; present on the left.
5. Sensory:
 - a. Pain, touch and vibration were intact.
 - b. It was difficult to test other modalities but tactile localization appeared to be intact.

Clinical diagnosis: Embolus from heart to left middle cerebral artery

Laboratory data:

1. *Skull X-rays* were normal.
2. *EEG* was normal (48 hours after admission).
3. Cerebrospinal fluid was normal.
4. *Electrocardiogram* revealed atrial fibrillation

Hospital course: Within 24 hours a significant return of strength in the right hand had occurred; independent finger movements could be made. Within 48 hours after admission the patient was able to

repeat single words but still had almost no spontaneous speech. She appeared aware of her speech disability and would manifest some frustration. She was able to carry out two- or three-stage commands although tongue movements and perseveration remained a problem. Within 6 days of admission the patient used words, phrases and occasional short sentences spontaneously. She was better able to repeat short sentences. At this time strength in the right arm had returned to normal, but a right central facial weakness was still present. More detailed language evaluation two weeks after admission indicated the persistence of expressive disabilities consisting of word-finding and apraxic components. The apraxic components were evident on tongue placement and alternating tongue movements. Although complete sentences were used, sentence formulation in spontaneous speech was slow and labored with word finding difficulties. Repetition was better performed. In reading sentences aloud, substitutions or word omissions were made. The patient did well in naming common pictures and in matching printed words to spoken words or printed words to pictures. She could write from dictation and would often respond preferentially in writing when difficulty in speaking was encountered. No left-right confusion was present. Minor difficulties with simple arithmetic were reported. A right central facial weakness was still present.

Comment: There would appear little doubt that this patient had the sudden passage of an embolus (presumably from the left atrial appendage) into the left middle cerebral artery. In view of the selective face and arm weakness with a predominant expressive aphasia, the involved vessels must have been cortical branches such as the prerolandic and rolandic originating from the superior division of the middle cerebral artery. From the onset, it was clear that although some receptive components might be present, these were minor. The major problem was a severe nonfluent aphasia. As the hand weakness disappeared, the only other residual neurological findings were those of a right central facial weakness and an apraxia of tongue movements. Such findings would, of course, be consistent with a relatively selective involvement of Broca's area in the inferior frontal gyrus.

Why did such a rapid improvement occur in motor function and of the visual field? Most likely, the embolus fragmented and passed into the cortical branches supplying Broca's area.

With the passage of time, this type of patient would continue to show some degree of improvement (Mohr, 1973). Improvement could continue to occur over a two-year period. Although lesions of Broca's area may produce the acute onset of a nonfluent aphasia, rapid amelioration of the deficit occurs even when the acute lesion involves underlying white matter, as well as the superficial cortex.

In the following case 24-2, a more persistent anterior aphasia is demonstrated.

Case 24-2: On May 30, 1985, at midday, this 37-year-old right-handed woman with a past history of rheumatic fever, rheumatic heart disease and "an irregular pulse"(atrial fibrillation) had the sudden onset of loss of speech, central weakness of right face, an inability to protrude the tongue and a right hemiparesis. Although hemiparesis, face and tongue problems disappeared within a week, recovery of speech was slower and limited. At one week, she could produce some two syllable words.

Neurological examination at 17 months revealed the following residual findings:

1. *Language function:* Spontaneous speech was slow and relatively scanty. She could name objects slowly without difficulty, could do some simple repetitions and could write from dictation. She could carry out two and three stage commands. She could read slowly aloud but had little comprehension of what she read.
2. *Reflexes:* A residual right Babinski sign and right-sided hyperreflexia were present.

Clinical diagnosis: Anterior aphasia: embolic infarct of superior division of middle cerebral artery.

Laboratory data:

Although initial CT scans in May 1985 had been reported as negative; the MRIs in November 1986 and June 1990 demonstrated the infarct which included Broca's area, as well as adjacent frontal areas with predominant involvement of frontal operculum (inferior frontal gyrus) and adjacent middle frontal gyrus. In addition, a minor independent infarct was present in right occipital area (presumably embolic to the calcarine artery).

Subsequent course: Similar findings were present at 5 years, June 1990).

A brain section from a patient (Case 24-3) with a persistent nonfluent aphasia (is presented in Figure 24-4.

Case 24-3: This 69-year-old, right-handed male expired in 1965. In 1961 and 1963, The patient, had experienced transient episodes of right hemiparesis and aphasia, both followed by complete recovery. In 1964, a more persistent right hemiparesis and aphasia had developed.

General physical examination: No left carotid pulsation was present.

Neurologic examination(1965):

1. **Language functions:** Speech was nonfluent with only a small verbal output. A significant nominal aphasia with paraphasias was present. Reading was limited. Comprehension of spoken language was good. A marked apraxia was present for movements of tongue, lips and hands.
2. **Motor system:** Right hemiparesis with associated reflex findings.
Post mortem findings: Left carotid occlusion with old infarction, predominantly of left middle cerebral territory with lesser involvement of anterior cerebral territory. Note that minor cortical infarcts are also present involving cortex of right hemisphere.
(Courtesy of Dr. John Hills,; and Dr. Jose Segarra.)

Case 24-4 provides an example of a patient with a Wernicke's type aphasia

Case 24-4: This 40-year-old, right-handed white male had experienced a series of myocardial infarctions beginning 10 months prior to consultation. Angiographic studies indicated occlusion of the right coronary artery and the left anterior descending coronary artery with stenosis of the circumflex artery. The patient was subsequently admitted and a coronary artery bypass procedure was performed using extracorporeal circulation. Although the patient was stated to have tolerated the procedure well, the anesthetist noted that the patient was nonreactive 15minutes after the last administration of halothane anesthesia. When the patient did wake up, he was quite agitated requiring the use of agents to reduce agitation. Throughout the postoperative period, the patient continued in a disoriented and combative manner. Because of the patient's acutely psychotic state, transfer to the psychiatry service was actively planned. Because there were certain organic features to the patient's illness, a neurological consultation was obtained. The neurology resident in reviewing the progress notes discovered a notation that shortly after surgery the patient had transient difficulty in using his right arm.

Neurological examination:

1. **Mental status:**
 - a. The patient was an alert but agitated white male. Additional inquiries indicated that his agitation related to his inability to write a letter to his mother.
 - b. The patient's speech was fluent and usually grammatical. He made use of many paraphasias and neologisms (nonsense words). He often appeared unaware of his errors.
 - c. The patient was unable to name single objects such as pencil, cup, and spoon though he could recognize and demonstrate their use.
 - d. The patient could read occasional individual words; for example, cat, house. He could not comprehend or carry out, either spoken or written commands.
 - e. His attempts at spontaneous writing produced only a few letters. He was unable to write words or phrases from dictation. He did significantly better when asked to copy a printed sentence or phrase.
- f. Repetition of spoken phrases or sentences was poor.
- g. Calculations of even a simple nature were poorly performed.
2. **Cranial nerves:** II-XII was intact.
3. **Motor system:** No actual weakness was present. Gait was intact.
4. **Reflexes:**
 - a. A minor increase in deep tendon stretch reflexes was present on the right side.
 - b. The plantar response on the right was equivocal. The left was flexor.
5. **Sensation:** Pain, touch and vibration were intact.

Clinical diagnosis: Wernicke's type of fluent aphasia probably secondary to an embolus to the inferior division of the middle cerebral artery.

Comment: This patient who was seen before the era of modern neuroimaging provides an example of the clinical picture described by Wernicke. The use of the heart pump for open-heart surgery was associated with a high incidence of cerebral

emboli. The incidence of this complication has decreased as technical advances have been made and as “time on the pump” has decreased. As we have stressed, for solving neurological problems, the details of the history are important if the appropriate diagnosis is to be made. In the patient who is unable to provide a history, the careful review of progress notes and of nurses notes will often provide the clue that allows diagnosis.

The following case history 24-5 demonstrates such a sequence of involvement in a tumor infiltrating the posterior temporal inferior parietal area starting with a conduction aphasia.

Case 24-5: This 42-year-old right handed truck driver noted fatigue and irritability 6-8 weeks prior to admission. Three to four weeks prior to admission, he noted he was using words which he did not mean to use and certain words would not come to him. He had two generalized convulsive seizures; each proceeded by a ringing sensation in the ears, during the week prior to admission.

Neurological examination:

1. Mental status and language function

- a. The patient was alert and oriented to time, place and person.
 - b. He was cooperative and able to carry out the four-step command: “stick out your tongue, close your eyes, hold up your hand and touch the thumb to your ear”. There was however evidence of a significant left-right confusion when laterality was introduced e.g. “left hand to right ear”.
 - c. The ability to do even simple calculations was markedly impaired with or without paper e.g. $100-9=99$.
 - d. Memory was impaired; with immediate recall object recall limited to 2/5 objects and delayed recall in 5 minutes limited to 0/5. Digit span was limited to 2 forward and 0 in reverse. (normal would be 7 forward and 6 in reverse).
 - e. There was little evidence of an expressive aphasia. Flow of speech was slow with only minor mispronunciations. Reading was slow but with few errors. The patient’s did have minor difficulty in naming objects-a mild nominal aphasia. The patient’s greatest difficulty was in repetition of simple test phrases. There were moderate defects in drawings of a house and a clock but few errors in copying simple figures. There was a significant dysgraphia with marked difficulty in writing a simple sentence spontaneously or in writing from dictation. On the other hand, the patient was much better able to copy a simple sentence. Significant errors were made in spelling.
2. **Cranial nerves:** All were intact except for a mild right central facial weakness.
 3. **Motor system:** Strength, gait and cerebellar functions were all intact.
 4. **Sensory system:** Pain, touch, vibration, stereognosis, simultaneous stimulation, graphesthesia, and position sense were all intact, but point localization was impaired on the right side.

Clinical Diagnosis: Fluent posterior aphasia, disconnection syndrome plus elements of Gerstmann’s syndrome (left right confusion, dyscalculia, dysgraphia) plus seizures of focal origin (Heschl’s gyrus posterior temporal lobe) with secondary generalization. All suggested a lesion in the left posterior temporal-posterior parietal area.

Etiology was uncertain but tumor (glioma) or embolus to inferior division of left middle cerebral artery possible.

Laboratory data:

1. Skull and chest x-rays were normal.
2. **EEG:** Focal 4-5 Hz slow wave activity was present in the left parietal and posterior temporal areas.
3. **Brain scan (radioactive Hg 197):** Increased up take of isotope in the left posterior temporal –parietal area measuring 4x5 cm.
4. **Left carotid arteriogram:** Vascular mass in the region of the angular gyrus with tumor stain in the area.

Subsequent course: Papilledema soon developed and Dr. Robert Yuan performed a craniotomy. Although the cortex appeared externally normal, a firm mass could be palpated

slightly above and posterior to the angular gyrus. At 2 cm below the surface, firm yellow tumor tissue was encountered. All visible tumor and adjacent cortex of the angular and supramarginal gyri were removed and a partial left temporal lobectomy was performed. Histologic examination indicated a highly malignant glial tumor with active mitosis and necrosis (a glioblastoma multiforme). Post operatively, the patient had a marked expressive and receptive aphasia. By 30 days after surgery, the patient had a significant improvement in fluency, he continued to have a severe posterior type of aphasia. He was unable to carry out simple commands. His speech was incoherent, with nonsense words and neologisms. He appeared unaware of his errors and did not appear frustrated by his failure to follow commands. In addition to this Wernicke's type aphasia, the patient was unable to repeat words of two syllables. He could do no calculations, had severe difficulties in copying drawings and was unable to even write his name. The patient received radiotherapy but his condition continued to worsen with the development of a progressive expressive and receptive aphasia and hemiparesis all suggesting the spread of a rapidly growing glioblastoma. Coma, pupillary changes and respiratory changes then intervened suggesting the effects of herniation of the residual temporal lobe. Death occurred 7 months after onset of symptoms, and 5 months following surgery.

Comment: The early language and mental status disturbances in this patient were most severe in those tasks requiring repetition. Thus the patient could repeat no more than two digits, was unable to repeat any of the test phrases and was unable to write from dictation at a time when he could copy a sentence. Any expressive aphasia was minor, and he was fluent. He had no evidence of Wernicke type aphasia, since he could carry out a four-stage command without difficulty. Reading was relatively well preserved compared to writing, calculations and drawing construction. All of these findings suggest (1) the speech reception Wernicke's area was disconnected from the motor association areas for speech and writing Broca's areas 44,45 and the related areas of the premotor cortex and (2) the inferior parietal areas associated with writing, calculations, drawing, and the ability to distinguish left and right were damaged. The lesion found at surgery was deep to the angular and supramarginal gyri, the location of the arcuate sulcus. The seizures that finally brought the patient to neurological attention were originating in Heschl's gyrus of the temporal lobe, which would be adjacent to the area of the tumor.

The clinical state at 30 days following surgery reflected the additional effects of ablation of the Wernicke's area as well as the accentuation of the preoperative state. There had been the transient appearance of an expressive aphasia probably reflecting minor effects of the procedure on Broca's area.

The neurosurgical approach to the management of a glioblastoma particularly those involving the speech areas of the dominant hemisphere have changed in 35 years since this patient was seen. A limited stereotaxic biopsy under CT scan guidance would be undertaken and the patient would then be treated with dexamethasone and radiotherapy. The end results would have been similar and actually may even have occurred earlier. The postoperative quality of language function may have been transiently better. Unfortunately this patient had a very malignant and aggressive tumor. The median survival of glioblastomas with surgery alone is 26 weeks, with the addition of radiotherapy; 52-60 weeks. Median means that 50% of patients are going to survive less than these median figures.

The following case (24-6) provides a case of posterior aphasia with the lesion documented with CT scan.

Case 24-6: This 57-year-old female, with a long history of hypertension in the summer of 1985, had a brief episode of difficulty in word finding and a more prolonged episode in December 1985 with confusion, "visual problems", "inappropriate speech and difficulty finding the appropriate words". Following an additional episode in March 1986, she had persistent problems in reading and apraxia of the right hand.

Neurological examination (May 1986): The following abnormalities were present:

1. *Language function:* Spontaneous speech was usually quite fluent. She described the room, the environment and her friend. In contrast, capacity for repetition was very poor both as regards spoken and written speech. Spontaneous writing was very poor except for name and address

Reading to herself aloud was poor with little comprehension. She was able, however, to follow single one stage spoken or written commands but unable to do a sequence of commands. Naming of objects was well performed.

2. *Cranial nerves*: Extinction occurred in the right visual field for bilateral simultaneous stimuli.
3. *Motor system*: No hemiparesis was present.
4. *Reflexes*: Right-sided hyperreflexia and a right Babinski sign were present.

Clinical diagnosis: Posterior aphasia, infarction left posterior temporal and parietal areas, probably due to embolic occlusion of inferior division of the left middle cerebral artery.

Laboratory data:

1. *CT scan*: Infarct left posterior temporal and parietal areas (Fig. 24-6).
2. *Angiograms*: Occlusion of the left internal carotid artery. All anterior and middle cerebral artery branches filled from the right carotid. An artery to artery embolus was presumed.

The following case 24-7 would suggest this type of unilateral lesion producing a transient and partial but selective type of dyslexia.

Case 24-7: Seven days prior to admission, following a period of athletic activity, this 15-year-old, right-handed white male high school student had the onset of a 48-hour period of sharp pain in the left jaw and the supraorbital area. The next day the patient began to complain of blurring of vision and the following day had the onset of vomiting. Four days prior to admission, the patient noted that he was unable to read and to translate his Latin lessons. No definite aphasia was apparent. Two days prior to admission, the patient had the sudden onset of severe left facial pain, accompanied by tingling paresthesias of the right leg. The patient became stuporous and then unresponsive for approximately 90 minutes. An examination of spinal fluid at that time revealed pressure elevated to 290 mm of csf with 250 fresh blood cells.

Neurological examination:

1. *Mental status*: All aspects, including language function were intact.
2. *Cranial nerves*:
 - a. Examination of the fundus showed several small flame shaped hemorrhages. Visual fields were intact.
 - b. A slight, right, supranuclear-type (central) facial weakness was present.
3. *Motor system*: Intact
4. *Reflexes*: Deep tendon reflexes and superficial reflexes were symmetrical and physiologic.
5. *Sensory system*: Primary and cortical modalities were intact.
6. *Neck*: A slight degree of resistance was present on flexion of the neck (nuchal rigidity) consistent with the presence of blood in the subarachnoid space.

Clinical diagnosis: Subarachnoid hemorrhage of uncertain etiology. In view of age and the transient dyslexia, and the transient paresthesias of the right leg, an arteriovenous malformation in the left parasagittal parietal-occipital area might be suspected.

Laboratory data:

Arteriograms: An arteriovenous malformation was present in the left occipital region. The main arterial supply was the posterior temporal branch of the left posterior cerebral artery. The malformation drained into the lateral sinus. The posterior portion of the anterior cerebral artery was shifted across the midline, indicating a hematoma as well as the malformation.

Subsequent course: On that evening after his admission, the patient had the sudden onset of a bifrontal headache. For a 2- to 3-minute period, the patient was unconscious with deviation (repetitive driving) of both eyes to the right, and with sweating and slowing of the pulse rate. Over the next two days an increase in blurring of the optic disc margins was noted (early papilledema). Four days after admission, the patient suddenly complained of being unable to see from his right eye. He became restless and agitated. Additional headache and neck pain with numbness of right arm and leg were reported. Examination now disclosed a dense right visual field defect (homonymous hemianopsia). The deep tendon reflexes were now slightly more active on the right. Funduscopy examination suggested that

recent additional subarachnoid bleeding had occurred since new retinal hemorrhages were present. The next day (five days after admission), the patient was noted to have a significant reading disability (dyslexia), although other language functions were intact.

Because of the progressive evolution of neurological findings due to an expanding intracerebral hematoma, Doctor Robert Yuan performed a craniotomy. Blood was present in the subarachnoid space. The left lateral occipital cortical surface had numerous areas of bluish discoloration indicating an intracerebral clot. The main arterial vessel was a lateral and inferior branch of the posterior cerebral artery, bearing no relationship to the calcarine region. The draining vein was located in the occipital-temporal area, close to the tentorium. At a depth of 1 cm, a hematoma of 50 cc of clot was found. The clot extended down to the occipital horn of the lateral ventricle but did not enter the ventricle. The malformation, hematoma and related cerebral tissue of the lateral occipital area were removed. The calcarine area remained intact at the end of the procedure. Over a period of several days, the visual field deficits disappeared.

Detailed language and psychological testing approximately two weeks after surgery indicated that language function was intact except for reading. Oral reading was very slow (4 times slower than normal for a test paragraph), halting and stumbling. Comprehension of the material read was good. Minor errors were made in the visual recognition of letters. This was reflected in occasional errors in spelling. Visual recognition and naming of objects was intact. Auditory and tactile recognition of sounds, words, letters, sentences, questions, commands and so forth was intact. Calculations were intact. No right-left confusion or finger agnosia was present. Writing and drawing were intact but slow. Repetition of speech and spontaneous speech were intact.

Follow-up evaluation at 20 and 30 months indicated that, although the patient was doing well in school, receiving A's and B's with excellent grades in mathematics, he still was described as slow in reading compared to his level prior to illness. No actual errors were made in reading when this was tested.

Comment: The arteriovenous malformation in this case had involved and eventually required surgical removal of the lateral occipital area of the dominant hemisphere. The hematoma in the occipital lobe extending in from the lateral surface to the occipital horn was so located as to compress the optic radiation passing to the calcarine cortex or perhaps even to indirectly compress the calcarine cortex. Such a hematoma would also interfere with association fibers passing from left occipital areas to temporal parietal areas and with callosal radiation fibers passing from the occipital region (area 18) of the right hemisphere to the occipital and parietal areas of the dominant hemisphere. Following surgery, the patient had a relatively good recovery with the minor difficulties in reading; (a selective dyslexia) as perhaps the only indication of any damage to these fiber systems.

The complaint of the patient at the time that the right homonymous hemianopsia appeared was of blindness in the right eye. It is not uncommon for patients to localize field defects in this manner to the eye of the same side. The same may sometimes be true of patients with discharging lesions in the occipital area; the flashing lights and lines may be localized to the contralateral eye rather than to the contralateral visual field.

The episode on the night of admission is of interest because it suggests a focal adverse seizure, in this case presumably originating from areas 18 and 19 of the left hemisphere.

Geschwind (1965) has reviewed many of the previously reported cases of selective dyslexia. It is uncertain whether the information from area 18 of the non-dominant hemisphere passes to the non-dominant angular gyrus and then crosses to the dominant temporal parietal areas or whether these fibers pass instead directly to area 18 of the dominant hemisphere with information then conveyed to the dominant temporal parietal areas. He finally concludes that both pathways are probably operative. The relatively minor nature of the final residual deficit in the present case would be consistent with such multiple pathways. In addition, non-fatal hemorrhages always produce less damage than infarcts of comparable size. Finally, Coslett (2000) has reviewed various recovered pure cases of dyslexia where the right hemisphere may have played a role in reading. Such patients do better with concrete nouns than abstract nouns, verbs and functors (pronouns, prepositions, conjunctions and interrogatives). It should be noted that a relatively selective dyslexia in the absence of a severe general visual agnosia might occur. Geschwind has suggested that whether a general visual agnosia or dyslexia occurs may depend on the degree of disconnection of the dominant speech areas from the parietal and occipital areas of the non-dominant hemisphere. In the patient who already has left occipital cortex damage, dyslexia may require only damage to the splenium of the corpus callosum, whereas visual agnosia may require more extensive damage to the posterior body of the corpus callosum as well. As noted bilateral

visual association lesions (areas 18 and 19) would also produce a visual agnosia. (See also Coslett and Saffran 1989 and Friedman and Albert 1985).

In addition there are patients who have acquired dyslexia which is unrelated to the processing of the visual information input. These patients have a central (rather than the peripheral dyslexia of the pure alexia syndrome discussed above). The central dyslexic patient has an impairment of the “deeper” or “higher” reading functions by which visual word forms mediate access to meaning or speech production mechanisms. This problem is reviewed in detail by Coslett (2000).

Feinberg and Farah (2000) review the general topic of agnosias.

CHAPTER 26: VASCULAR SYNDROMES OF THE CEREBRAL HEMISPHERES

The following case history presents a young adult with severe carotid stenosis and infarction of the territories of both the anterior and middle cerebral arteries.

Case 26-1: This 23 year old right handed female on birth control pills, smoking one pack of cigarettes per day, on June 15, 1985 shortly after intranasal “snorting” of cocaine complained of gradually increasing right sided headache and then fell to the floor with a flaccid left hemiplegia with the head and eyes deviated to the right **Neurological examination:**

1. *Mental status:* The patient denied any illness and could not explain why she was in the hospital.
2. *Cranial nerves:* There was a left homonymous hemianopsia, deviation of head and eyes to the left and a left central facial weakness.
3. *Motor system:* A flaccid left hemiparesis was present.
4. *Reflexes:* deep tendon reflexes were initially depressed on the left side. Plantar responses were extensor bilaterally.
5. *Sensory system* a severe left hemisensory deficit, with a neglect of the left side of space and body was present.

Clinical diagnosis: Total right middle cerebral artery territory infarct.

Laboratory data:

1. *Initial CT Scan* demonstrated hypodensity (infarction in right frontal and parietal areas).
2. *Right carotid angiogram* demonstrated severe stenosis of the supraclinoid segment of the right internal carotid artery with severe stenosis of the M-1 segment of the right middle cerebral artery and multiple areas of narrowing of the remainder of the right MCA. *Left carotid angiogram* indicated only limited cross filling of the distal right middle and anterior cerebral arteries.

Subsequent course: On 6-21-85, 6 days after admission the previously alert patient suddenly developed a decreased level of consciousness and a fixed, dilated right pupil suggesting that tentorial herniation had been produced by severe edema or hemorrhagic transformation of the infarct. CT Scan now demonstrated massive infarction and edema-right anterior and middle cerebral artery territories plus-transtentorial and sub falx herniation (Fig.26-6). With emergency management of the increased intracranial pressure-(monitor and osmotic agents) the patient became more alert and was transferred to a rehabilitation facility.

Comment: This young woman had as a major risk factor, the intranasal snorting of cocaine. The vasospasm induced by this agent was sufficient to produce severe stenosis of the internal carotid and the initial segment of the middle cerebral artery. The multiple areas of narrowing seen in the branches of the MCA may well have represented emboli from these more proximal sources. Whether the severe stenosis of the M1 portion also involved an embolic event from the siphon remains unclear. It is clear that the severe stenosis of the carotid artery produced infarction of both the MCA and ACA territories. In this case there was insufficient cross flow from the left carotid supply to prevent infarction. As we will see in case 26-3 massive infarcts of the MCA territory plus or minus adjacent territories constitute a serious threat to life due to massive edema and or hemorrhagic infarction with the risk of herniation. The use of cocaine and of crack cocaine may be associated coronary or cerebral artery vasospasm. In addition to cerebral infarcts, cerebral hemorrhage may also occur, particularly with crack cocaine.

The following case history concerns a patient with severe stenosis at the carotid bifurcation producing both retinal and hemispheric TIA's.

Case 26-2: This 54-year-old, right-handed, white male had experienced intermittent episodes of blurring and blacking out of vision in the left eye for at least 7 years. Each episode would last 30 to 60 seconds and would occur twice per month. Ten days prior to admission, the patient had the onset of numbness of the right side of the face accompanied by minor weakness of the right face, arm, and leg. There was also a transient difficulty

in speech (possibly dysarthria, possibly difficulty in word finding). Symptoms cleared completely in 45 to 60 minutes with the exception of residual numbness of the right side of the face.

Family history: The patient's mother died of a "stroke" at age 66 years, and his father, of heart disease at age 57.

General physical examination:

- (1) Blood pressure was slightly increased to 160/100 in both arms. Pulse rate and rhythm were normal
- (2) Bruits (murmurs) were present over each carotid artery, but the heart was normal with no murmurs.
- (3) The retinal artery pulsation was easily obliterated by pressure on the globe of the left eye. No significant changes occurred on compression of the right globe.
- (4) Peripheral pulses were poor in the lower extremities.

Neurological examination: Mental status, language function, cranial nerves, motor system, reflexes, and sensory system were all normal except for a minor right central facial weakness.

Clinical diagnosis: Carotid stenosis with retinal and hemispheric TIA's.

Laboratory data:

1. Hemoglobin, serological tests for syphilis, skull and chest x-rays, electroencephalogram, and brain scan were all normal. Cholesterol was elevated to 284 mg%.

2. *Arteriography (aortic arch study)* demonstrated a complete occlusion at the origin of the left internal carotid artery. A right brachial arteriogram demonstrated filling of the left anterior and middle cerebral arteries by cross flow through the anterior communicating artery from the right side. Additional studies also demonstrated filling of the intracranial portion of the left internal carotid artery from the left posterior communicating artery.

Subsequent course: Ten days after that hospital admission, a left carotid endarterectomy was performed by Dr. Allan Callow with a restoration of blood flow following removal of the occlusive lesion (atherosclerosis with recent thrombosis) at the carotid bifurcation.

Comment: The location of disease in the left carotid artery was clearly indicated by the episodes of left eye visual disturbances followed by symptoms on the contralateral side of the body. The development of symptoms in the face, with disturbance of speech is consistent with total occlusion of the carotid artery, with greater involvement of the middle cerebral territory than of the anterior cerebral territory. The fact that this patient, with progressive stenosis of the carotid artery, had symptoms for many years only in the ophthalmic-retinal artery distribution, is explained by the excellent collateral flow into the anterior and middle cerebral arteries from the anterior communicating bypass. In addition collateral flow would enter the common carotid artery from the posterior communicating artery above the take off of the ophthalmic artery.

It should be apparent that the final complex of neurological symptoms and signs, occurring with occlusion of the carotid artery, will depend on the total pattern of cerebral blood flow in the individual patient. In many patients total occlusion of the carotid artery will produce an infarction of that portion of the cerebral hemisphere supplied by the carotid artery (primarily the middle cerebral territory). In others, a benign outcome is the result (Bornstein and Norris, 1989). With the development of imaging techniques such as CT and MRI scan - has come the recognition that small silent infarcts may occur in patients with non symptomatic stenosis of the carotid artery (Norris and Zhu, 1992).

In this case, the occurrence of symptoms in the right side of the face plus the difficulty in speech might raise the question of a possible embolus to a branch of the MCA from the thrombus at the bifurcation. A perfusion deficit would have produced problems primarily in the border zone (the area of the arm).

In this particular case, earlier evaluation of the patient might well have resulted in a demonstration of occlusive disease of the extracranial portion of the carotid artery

prior to total occlusion. For such patients surgical therapy is feasible. To restore blood flow 20 days after occlusion as in this case is unusual.

A question which remains unanswered in this case is whether this patient would have proceeded eventually to a completed lasting hemiparesis. Kase et al (1991) have summarized the various studies. The rate of completion of the stroke over a 40 month period varied from 2% (Marshall, 1964) to 51%.

The following case demonstrates a case in which the patient began with carotid TIA's progressed to a carotid border zone syndrome of infarction and then involved additionally all of the middle cerebral artery territory.

Case 26-3 (Pt. of Dr. Thomas Mullins): This 72-year old right-handed white male was admitted for evaluation of two episodes of right upper extremity weakness, each of two hours duration, beginning 2 days prior to admission. Following the first episode, the patient had persistent left-right disorientation, a deterioration in writing (dysgraphia), could not understand what he had read and had transient slurring of speech.

Neurological examination:

1. *Mental status and language function:* Intact for alertness and orientation. Language was fluent with intact repetition, and object naming; however, reading comprehension, writing, and left-right orientation were all impaired.
2. Cranial nerves: Intact.
3. Motor system, reflexes and sensory system were all entirely intact.
4. *Carotids:* A bruit was present on the left.

Clinical diagnosis: Carotid artery stenosis with TIA's reflecting decreased perfusion in the border zone followed by thrombosis and passage of emboli to the inferior division of the middle cerebral artery.

Laboratory Data:

1. CT scan and EKG were normal
2. An *arteriogram* performed on the day following admission demonstrated the following:
 - (a) The left internal carotid artery was completely occluded just above the bifurcation (Fig. 26-7A).
 - (b) The left external carotid artery did fill the left internal carotid artery at the siphon through anastomosis about the orbit (Fig. 26-7B). However, there was a cutoff just below the siphon suggesting that the thrombus (clot) at the bifurcation had extended to this level. Moreover, the left middle and anterior cerebral arteries failed to fill in this manner.
 - (c) The left posterior cerebral artery did originate from this segment of the otherwise occluded carotid siphon segment but with no retrograde filling into the basilar artery (Fig. 26-7B).
- 4) The right carotid artery filled not only the right middle cerebral and anterior cerebral artery but also was the source of the right posterior cerebral artery (Fig. 26-7C).
- 5) The right carotid system also supplied the left anterior cerebral artery and to a limited extent the left middle cerebral artery (Fig. 26-7D).

Subsequent course: On the day following admission, weakness in the right hand at wrist and finger extensors recurred. During the arteriogram, the patient was noted to have additional problems with speech. Weakness in the right upper extremity increased. Despite subsequent anticoagulation, additional progression occurred with total paralysis of the right upper extremity, aphasia and a right homonymous hemianopsia. A *repeat CT scan*, 72 hours after these events, demonstrated acute infarction with severe edema involving the entire cortical and deep territory of the middle cerebral artery and the cortical territory of the posterior cerebral artery but with relative sparing of the anterior cerebral artery territory and of the thalamic territory of the posterior cerebral artery (Fig. 26-8). Coma developed secondary to the herniation effects on the brainstem and the patient expired 8 days after admission.

Comment: This patient clearly had hemispheric carotid border zone TIA's followed by persistent symptoms that suggested involvement of the inferior division of the middle cerebral artery to the inferior parietal lobule. These latter persistent symptoms may well have been embolic from the thrombus at the level of the carotid bifurcation. There then was progression of the border zone findings

followed by involvement of the entire middle cerebral artery territory and of the cortical territory of the posterior cerebral artery. The end result was a massive cerebral infarct with considerable swelling. Such massive swelling with herniation of temporal lobe through tentorium and secondary brainstem compression is the major cause of acute death in patients dying after acute carotid artery or massive middle cerebral artery infarctions (31%). Other causes of death are pneumonia (29%), cardiac arrest (17%), pulmonary embolus (13%) (Bounds et al 1981).

Not all patients with acute carotid infarcts continue to progress. In the series of Jones and Milliken (1976), 39% of patients remained stable. Thirty-five percent had gradual improvement and 19% had a progressing deficit over 48 hours.

The following case history illustrates such an occlusion with massive infarction of the entire territory of the middle cerebral artery.

Case 26-4: This 61-year-old, right-handed black housewife one week prior to admission, suddenly fell to the floor while taking a bath and lost consciousness. She was picked up off the floor by her son who found that she was unable to move her left arm and leg. She was unable to walk and had regained no function in these extremities. Her speech had been thick, but no aphasia had been present. No headache had been noted.

Past history: Hypertension had been present for three years. Five days prior to admission, she had been switched to a new antihypertensive medication. There was no history of heart disease. Both parents had died of heart disease and hypertension.

General physical examination: Blood pressure was 150/100, pulse was regular at 84. Blood pressure was 150/100, the pulse was 84 and regular.

Neurological examination:

1. *Mental status:* The patient was obtunded and slow to respond. However, she was grossly oriented to time, place, and person.

2. *Cranial nerves:*

- a. The head and eyes were deviated to the right. The patient could not move the eyes to the left on command. However, on vestibular stimulation, the eyes could be moved to the left.
- b. The patient neglected stimuli in the left visual field. The pupils did respond to light.
- c. Papilledema was present bilaterally particularly in the right fundus where a recent hemorrhage was present.
- d. There was a decrease in pain sensation or a neglect of painful stimuli on the left side of the face.
- e. A marked left central facial weakness was present.

3. *Motor system:* A complete flaccid paralysis of the left arm and leg was present. The patient was unable to sit up without support.

4. *Reflexes:* Deep tendon reflexes were increased on the left compared to the right. The left plantar response was extensor.

5. *Sensory system:* All modalities of sensation were decreased on the left side of the body.

Clinical diagnosis: Acute occlusion of the stem of the middle cerebral artery, possibly embolic, although primary occlusions of intracranial arteries may occur in the non-Caucasian population. Hypertensive intracerebral hemorrhage was a less likely possibility.

Laboratory data:

1. *Chest and skull x-rays* were negative but the *electrocardiogram* showed left ventricular hypertrophy.
2. *Electroencephalogram* indicated focal damage throughout the right hemisphere—most prominent in the right frontal area, (focal 3 to 5 Hz slow waves). In addition there was a relative absence of electrical activity in the right temporal area (Fig. 2-23) consistent with a severe degree of destruction of this area.
3. Brain scan 3 days after admission showed a significant but diffuse uptake of isotope (Hg^{197}) in the right hemisphere. A repeat brain scan on 9 days after admission showed a more marked uptake measuring 11x6x6 cm., extending from the right frontal area to the posterior parietal area. Uptake extended from the surface to the deep midline (Fig. 26-14).
4. Cerebrospinal fluid contained no significant cells. Protein was moderately increased to 57 mg./100 ml. Pressure at the lumbar area was 150 mm. of csf.
6. Right brachial arteriogram revealed a complete occlusion of the right middle cerebral artery at its origin (Fig. 26-15).

Hospital course: The patient showed no significant improvement during a four week hospital course.

Comment: The patient had a sudden occlusion of the right middle cerebral artery with massive infarction of the entire area of the right hemisphere supplied by the middle cerebral artery. Such massive infarctions are often, as in this case, associated with a significant degree of cerebral edema with the development of papilledema. At times the degree of swelling of the cerebral hemisphere may be sufficient to displace the pineal or the anterior cerebral artery. It is also possible in this case that the infarct was secondarily hemorrhagic. In many cases of hemorrhagic infarction the spinal fluid does not contain red blood cells.

The equal involvement of arm, arm, and leg was consistent with the involvement of the penetrating branches of the middle cerebral artery with resultant infarction in the posterior limb of the internal capsule. The deviation of head and eyes to the right indicates destruction of area 8 of the right hemisphere or of the fibers descending from this area, through the corona radiata. Involvement of the cortex in addition to this the internal capsule is also indicated by the findings on the brain scan and electroencephalogram and by the neglect of visual and tactile stimuli on the left side. As regards the etiology, an embolus to the middle cerebral artery is the most likely etiology although in a non-Caucasian patient, primary occlusion could not be ruled out. Today this patient would probably have been treated with t-PA presuming that she had arrived at an emergency room capable of administration of this agent within 3 hours of onset of symptoms and did not have contraindications in terms of preexisting conditions or of CT scan findings (hemorrhage or massive infarction -refer to Brott & Boguslavsky, 2000) .

Prognosis for survival during the acute state of the first week depends on the degree of edema patients with massive middle cerebral artery territory infarcts due to MCA occlusion who already had early CT scan evidence of brain swelling within 24 hours of the ictus. Fifty five percent of these patients expired ,overwhelmingly of herniation effects. Patients older than 45 years had a poorer prognosis than younger patients. Infection of the lungs is a serious complication of large infarcts and a major cause of death during the second week. If the patient survives ,prognosis for recovery is related to the size of infarct. Less than 3 cm. infarcts may be associated with a good recovery ; greater than 3 cm. with severe disability (Olson ,1991). This patient had already survived for one week prior to reaching the neurologic center. Although she continued to survive, her prognosis for recovery remained poor.

The following case history illustrates many aspects of ischemia within the cortical distribution of the posterior cerebral artery. This patient demonstrates the general rule that posterior cerebral cortical infarcts are usually embolic.

Case 26-5: This 55 year old ambidextrous married white female research coordinator at approximately 11:30 AM on the day of admission suddenly developed blurring of vision possibly all over her field of vision, possibly in her left visual field, possibly in her left eye. A coworker checked her vision, and found that she had a left visual field defect. Shortly thereafter, she developed tingling paresthesias of the left face arm and leg.

Past history: Hypertension treated with hydrochlorothiazide and Lasix.

Physical examination: Blood pressure was elevated to 160/70. Weight was elevated to 264 pounds .A small ecchymosis was present under the toenail of the left second digit.

Neurological examination,(3hours after onset):

1.Mental status: Intact .

2.*Cranial nerves:* A non-congruous left homonymous hemianopsia was presented greater in the left temporal field than the right nasal field.

3.Motor system: Intact.

4.*Reflexes:* Deep tendon stretch reflexes were decreased in the lower extremities (patella,1+ and Achilles,0). Plantar responses were equivocal ,with the left probably extensor.

5.*Sensory system:* There was decreased pain and errors were made in graphesthesia over the left foot.

6.*Vascular:* There were no bruits over the carotids and subclavian areas and the blood pressures in the two arms were equal.

Clinical diagnosis: Posterior cerebral artery ischemia and possible infarct, probably embolic, involving the right calcarine cortex and thalamus or a lacunar event involving the right thalamus.

Laboratory data:

1. Duplex scans of the carotid and vertebral arteries and CT scan of the head on the day of the event were normal. RPR, ESR, TSH, proteins C, S, antithrombin 3 and all anticardiolipin antibodies were normal.
2. *MRI*, 4 days after onset (Fig.26-18) :small area of increased signal in the right occipital lobe in region of the visual cortex consistent with an infarct in distribution of the calcarine artery.
3. *MRA* (Fig.26-19): decreased flow in the distal right posterior cerebral artery probable embolic occlusion with filling of distal branches by anastomotic flow.
4. *Holter monitoring* demonstrated multiple brief episodes of paroxysmal atrial fibrillation.
5. The routine *transthoracic echocardiogram* demonstrated no clear cut abnormalities. However the *transesophageal echocardiogram* demonstrated a definite patent foramen ovale with right to left shunting.

Subsequent course: Reevaluation of the patient 22 hours after the onset of symptoms demonstrated clearing of all neurologic findings. When seen 2 weeks after the event her only complaint related to some problems in reading. This patient already been receiving aspirin at the time of the event and this was discontinued. She was begun on lifelong systemic anticoagulation with coumadin by the consultant cardiologist Dr. Filiberti since she had two conditions associated with embolization: paroxysmal atrial fibrillation and patent foramen ovale with right to left shunting. The patient did well over the subsequent 5 years.

Comment: When initially evaluated, the posterior cerebral artery location was clear but the pathophysiology was not. The subsequent imaging studies clearly indicated a small infarct involving the calcarine artery territory. Whether the previous sensory findings indicated some involvement of the posterior cerebral penetrating supply to the ventral posterior lateral nucleus of the thalamus remains unclear. The decreased flow in the right posterior cerebral artery was clearly demonstrated. In general as with the middle cerebral artery, cortical infarcts of the posterior cerebral artery territory, in the Caucasian population are almost always embolic. In this case the patient had two possible sources for emboli and was placed on long term anticoagulation.

The following case 26-6 presented at the onset with a transient bilateral posterior cerebral ischemia but with more severe residual symptoms reflecting unilateral posterior cerebral disease.

Case 26-6. This 75-year-old, white, right-handed widow developed sudden headache on the day prior to admission, with nausea, vomiting, and a poorly described bilateral disturbance of vision. She was found by a relative the morning of admission complaining of total blindness and of severe headache. She was noted to be confused and incoherent (believed she was in New Jersey rather than Massachusetts). She was able to walk only with assistance.

Past history: A minor degree of hypertension had been noted several days prior to admission.

Physical examination: The patient was an obese female with blood pressure elevated to 170/100. She was holding her head complaining of headache.

Neurological examination:

1. Mental status:
 - a. The patient was restless and disoriented for time and place.
 - b. There were difficulties in cooperation so that detailed testing of mental status could not be performed.
 - c. Simple calculations were poorly performed.
 - d. Digit span was markedly limited.
 - e. There was no left-right confusion and no evidence of aphasia.
2. Cranial nerves:
 - a. Initially the patient was unable to detect objects (e.g., a face or lights) in either visual field. Within six hours, a change had occurred. Although conjugate extraocular movements were full, the patient tended to keep her eye deviated to the right and failed to follow objects introduced from the periphery of the left visual field. The eyes could be deviated to the left on command.
 - b. The pupils responded to light.
3. Motor system:
 - a. Strength was grossly intact.

- b. A slight unsteadiness (ataxia) of gait was present.
- 4. Reflexes:
 - a. Deep tendon reflexes were grossly symmetrical.
 - b. A Babinski response was present on the left; a probable Babinski sign was also present on the right.
- 5. *Sensory system*: All modalities were intact.

Clinical diagnosis: Ischemia bilateral posterior cerebral arteries, cortical branches, probably embolic.

Laboratory data:

1. *Hematocrit* was normal. *Total cholesterol* was elevated to 312 mg./100 ml. The *glucose tolerance test* was consistent with diabetes mellitus.
2. Chest and skull x-rays and the electrocardiogram were normal.
3. The *electroencephalogram* demonstrated focal 3 to 4 cps slow waves in the right posterior parietal occipital area with rare slow waves in the right posterior temporal area consistent with focal damage in this area.
4. *Lumbar puncture* indicated clear spinal fluid with no cells and a normal protein of 18 mg./ml.

Hospital course: The patient had a significant improvement in headache and a clearing of confusion with a return of mental status to her normal level. Her hospital stay was prolonged by the development of thrombophlebitis of the left femoral vein. At the time of hospital discharge, one month after admission, there was still a residual left field defect (homonymous hemianopsia) with preservation of vision in the macular area (macular sparing). Follow-up evaluation approximately 14 months after discharge indicated no significant neurological findings except for the residual left field defect (homonymous hemianopsia with macular sparing) (Fig. 23-16).

Comment: The initial symptom of total blindness suggested bilateral posterior cerebral ischemia. The development of confusion and disorientation is also consistent with bilateral posterior cerebral ischemia. The nausea, vomiting, and minor ataxia of gait may well have indicated ischemia of the brain stem, suggesting that the basic occlusive process may have originated at a lower point in the basilar artery. The residual and most severe degree of involvement was certainly within the territory of the right calcarine artery.

The occurrence of severe headache is not usually considered in connection with ischemic-occlusive disease. A review of our cases of posterior cerebral occlusion indicates that the occurrence of severe headache is often a prominent symptom. Often in these cases prior to lumbar puncture, the diagnosis of subarachnoid hemorrhage was considered.

At the present time evaluation would include a CT or MRI scan. Other examples of posterior cerebral artery cortical infarcts are presented in the visual system chapter with appropriate CT scans.

The following case 26-7 provides an example of an intracerebral hematoma of unknown etiology in a young patient.

Case History 26-7. This 33-year-old white, right-handed, male linotype operator, at approximately 8:30 p.m. had the sudden onset of numbness of the left side of his mouth. At 10:30 p.m. he developed a severe right frontal headache and noted sudden onset of numbness of the left upper extremity which rapidly spread to involve the entire left side. Marked weakness of the left arm and leg developed. Evaluation that evening at his local community hospital indicated a dense left homonymous hemianopia, a marked left central facial weakness, an absence of any voluntary movement of the left arm and leg and no awareness of painful stimulation of the entire left side. A left Babinski sign was present. Lumbar puncture revealed opening pressure elevated to 235 mm. of water; and 50 fresh red blood cells per cubic mm. The patient was subsequently transferred to the neurosurgical service at New England Center Hospital.

Past history: There were no remarkable features as regards hypertension, renal disease, or diabetes mellitus. No history of drug use was obtained.

Physical examination: The patient was moderately obese with a normal blood pressure of 110/85. Examination of the heart revealed no abnormalities. No rigidity of the neck was present. There were no murmurs over the cranium.

Neurological examination:

1. **Mental status:** Orientation, speech and the ability to provide a coherent history were all intact.
 2. **Cranial nerves:**
 - a. Examination of the fundi showed no hemorrhage or papilledema.
 - b. A dense left homonymous hemianopsia was present.
 - c. Sensation was defective on the left side of the face, as well as the left side of the body.
 - d. A left central facial weakness was present.
 - e. The tongue deviated to the left.
 3. **Motor system:**
 - a. A dense flaccid paralysis of the left arm and leg was present.
 - b. There was no resistance to passive motion in the left arm and leg.
and little in the left lower extremity (that is, a flaccid paralysis was present).
 - c. Cerebellar tests were negative.
 4. **Reflexes:**
 - a. Deep tendon reflexes were absent in the left upper extremity but increased in the left lower extremity
 - b. A Babinski sign was present on the left. The plantar on the right was flexor.
 - c. No grasp reflexes were present.
 5. **Sensation:**
 - a. There was no perception of pinprick or of tactile stimulus on the entire left side of the body.
 - b. Position and vibratory sensation were absent on the on the left.
- Clinical diagnosis:** Intracerebral hematoma right putamen-thalamus or embolus stem of MCA with hemorrhagic transformation.

Laboratory data:

1. Hematocrit, white blood count, and differential were all within normal limits. Sedimentation rate was normal.
2. *Tests of bleeding time, clotting time, and prothrombin time* were all within normal limits.
4. *Skull x-rays* revealed a shift of the pineal, 7 mm. from right to left.
5. *Electroencephalogram* revealed frequent focal 4 to 5 cps slow waves in the right hemisphere most prominent in the frontal and parietal areas consistent with focal damage in these areas.
6. *Arteriograms* (right common carotid) revealed a 12 mm. shift of the pericallosal branch of the anterior cerebral artery. The internal cerebral vein was also shifted 8 mm. from right to left. The middle cerebral branches emerging through the sylvian fissure were depressed. There was no evidence of an abnormal arteriovenous shunt or of an aneurysm. Cortical vessels and veins in the suprasylvian area were stretched over relatively avascular areas. The conclusion was a space-occupying mass in the right posterior frontal parietal area consistent with an intracerebral hematoma.

Subsequent course:

On the day of admission, the patient was taken to the operating room. A right parietal burr hole was made. The underlying cortex was noted by the neurosurgeon, Dr. Robert Yuan, to bulge prominently. A needle was inserted to a depth of 1 cm. into the cortex where 25 cc. of old, dark red blood under pressure was expelled. Free drainage of blood continued through a catheter which remained in place for 2 days.

Return of voluntary movement in the left lower extremity at the hip and knee was noted on the day following surgery. Reevaluation of neurological status 2 weeks after surgery, revealed continued improvement. The left homonymous hemianopsia was no longer present but the patient did have some difficulty in reading (losing the left half of the line of print). A left central facial weakness was present; voluntary hand-foot movements on the left were still not possible. Proximal muscle groups (shoulder, hip, knee) had returned to 60 per cent of normal strength. Deep tendon reflexes were now hyperactive in the upper and lower left extremities with a left Babinski sign. A dense

sensory deficit remained on the left side with no perception of pain, touch, vibration, and position in the upper and lower extremities. Reevaluation 4 weeks after surgery, revealed a return of pain and temperature sensation but continued deficits in proprioception. Reevaluation by Dr. Yuan 4 months after surgery, indicated a return of strength in the left hand with a strong grip. The gait was typical of a spastic hemiplegia. Reflexes were unchanged. Sensory examination revealed a return of primary modalities such as vibration and pain, but marked errors in cortical modalities, such as position sense, were made. Follow-up 7 months after surgery indicated an excellent return of strength on the left side but continued incoordination in the left hand due to deficits in proprioception.

Comment:

This patient from several standpoints presents a number of unusual features not seen in the typical case of intracerebral hemorrhage. The patient was relatively young (33 years old) and had no history of hypertension. He had none of those conditions such as leukemia, bleeding disorders, and the like which predispose to intracerebral hemorrhage. The arteriogram provided no evidence of an intrinsic or a secondary metastatic brain tumor. Moreover, histological examination of the tissue and drainage material obtained at the time of surgery failed to reveal tumor cells. No aneurysm was demonstrated on angiography. Although no arteriovenous malformation was demonstrated at the time of arteriography, such a malformation may have been present previously but destroyed in the process of hemorrhage. The significance of the minor prodromal sensation of numbness of the face remains uncertain. This may have reflected an initial small area of ischemia with secondary hemorrhage.

Where was the initial site of hemorrhage? In this case, the hemorrhage apparently originated in the subcortical white matter of the parietal lobe presenting as a lobar hemorrhage. The pattern of initial evolution of symptoms and the final pattern of sensory deficit is perhaps more consistent with such a parietal lobe location. From the prognostic standpoint, he did not lapse into coma and did not have compromise of brain stem functions as so often occurs when there is tentorial herniation or an extension of the hemorrhage into the ventricular system. That these various events did not occur, may in part relate to the drainage of the hematoma by the neurosurgeon with removal of this supratentorial mass lesion. The management of intracerebral hemorrhages is discussed in greater detail by Ojemann and Heros, (1983).

The following three cases provide examples of subarachnoid hemorrhage from aneurysms at the three major sites: posterior communicating-internal carotid (Case 26-8), middle cerebral bifurcation (Case 26-9) and anterior communicating –anterior cerebral junction (Case 26-10)

Posterior communicating- internal carotid junction.(Figs. 26-24)

Case 26-8: This 66-year-old white housewife, five days prior to admission, had the sudden onset of a severe bicipital bifrontal headache associated with vomiting. The headache was constantly present for 3 days but was increased by coughing. At the same time, she noted an alteration of vision in the right eye. She noted also a drooping of the right eyelid. The headache subsided, only to recur one night prior to admission as a severe occipital headache associated with vomiting. There was no past history of hypertension. The patient was admitted to her community hospital. A lumbar puncture revealed the presence of subarachnoid blood and the patient was transferred to the neurology/neurosurgical services of the New England Medical Center on 10/2/66.

General physical examination: The patient was an obese female with blood pressure of 140/80 and complaints of severe headache. Her temperature was normal.

Neurological examination:

1. *Mental status:* The patient was alert with mental status intact.
2. Cranial nerves:
 - a. Fundus: Blurred discs were present bilaterally, being greater on the right. No venous pulsations were present on the right.
 - b. Nerve III: The right pupil measured 4 mm. and was not reactive to light on direct or consensual stimulation.. The left pupil measured 2mm and was reactive to light. Ptosis of the right eyelid was present. At rest on forward gaze, there was outward deviation of the right eye. The patient was unable to adduct the right eye on left lateral gaze and failed to move this eye on upward or downward gaze. Other extraocular movements were intact.

c. Nerve VII: Minimal flattening of the right nasal labial fold was present.

3. *Motor system*: Strength, coordination, and gait were intact.
4. *Reflexes*: Deep tendon: A minimal relative increase was present on the right. Plantar responses: The left was flexor, the right was equivocal.
5. *Sensation*: All modalities were intact.
6. *Neck*: Mild nuchal rigidity was present (resistant to passive flexion of head onto chest).
Clinical diagnosis: Subarachnoid hemorrhage due to an aneurysm at the posterior communicating–internal carotid junction.

Laboratory data:

1. Skull and chest x-rays were normal.
2. Studies of bleeding time, clotting time, and prothrombin time were all within normal limits.
3. *Arteriograms* revealed an aneurysm of the right internal carotid artery just below its junction with the posterior communicating artery. There was no left-to-right flow through the anterior communicating artery. There was narrowing of the anterior cerebral arteries near their origin bilaterally. This suggested to the radiologist the possibility of vasospasm, secondary to the presence of subarachnoid blood.

Hospital course:

Because the history suggested several episodes of bleeding, surgical therapy was selected. A right temporal craniotomy was performed by Dr. Robert Yuan with clipping of the neck of the aneurysm. The temporal lobe was retracted revealing a 13 mm.-long saccular aneurysm, arising from the internal carotid artery close to the junction with the posterior communicating artery. Distally the aneurysm enlarged into a large sac which was hidden behind the oculomotor nerve. This nerve was bulging at the point where the aneurysm, which was clipped, was well formed. The more distal sac of the aneurysm was thin and showed signs of previous rupture with yellow staining of the adjacent meninges. The sac of the aneurysm was covered with Gelfoam. Postoperatively, significant deficits as compared to the preoperative neurological status were evident. The level of consciousness waxed and waned with periods of alertness alternating with periods of apathy and drowsiness. Twenty days after surgery, she was described as sitting with both eyes closed, continuously grasping and palpating the arm of the chair with the right hand, less frequently with the left. There was a marked bilateral release of an instinctive grasp reflex. There was increased resistance in both upper extremities, at times described as plastic rigidity, at times as the “Gegenhalten,” associated with bilateral frontal lobe disease. No spontaneous voluntary movements of the left leg occurred. Bilateral Babinski signs were present. A bilateral resting tremor of the hands and of the head was also present. At times inappropriate jocularity was present. All of these findings suggested a bilateral front lobe syndrome with infarction in the territory of the anterior cerebral arteries and additional involvement of the basal ganglia. The complete paralysis of the right third nerve remained at preoperative level. At the time of hospital discharge, one month after surgery, the frontal lobe findings and the weakness in the left leg remained prominent.

Comment:

The presence of severe headache in association with a mild degree of nuchal rigidity suggests meningeal irritation. Such irritation could indicate a subarachnoid hemorrhage or a meningitis (inflammation of the meninges due to bacterial or viral infection). The sudden onset of the headache is more consistent with a subarachnoid hemorrhage. The lack of fever and of accompanying or prodromal systemic findings is also against the diagnosis of meningitis. Finally, the clearly focal third nerve findings are more in favor of the diagnosis of subarachnoid hemorrhage (although focal or multifocal neurological findings may develop as complications of a bacterial meningitis).

In this case, the significant findings on neurological examination related to the right third cranial nerve. The third cranial nerve is particularly subject to compression by aneurysms of the posterior communicating artery because having emerged from the midbrain it pursues an anterior course towards the cavernous sinus in a close parallel relationship to the posterior communicating artery. In general, compressive lesions of the third nerve produce initially an alteration in pupillary constrictor functions, then involvement of the levator palpebrae and finally involvement of the superior, medial and inferior

rectus, and inferior oblique muscles. The initial alteration in vision in the right eye and ptosis of the right eyelid at the onset of headache are then consistent with a compressive lesion. The patient at the onset of symptoms did not report a diplopia.

The third nerve as it emerges from the midbrain also passes in close relationship to the posterior cerebral and superior cerebellar arteries, but aneurysms of these vessels are much less common than those which occur in relation to the posterior communicating artery and internal carotid artery.

These findings with extrinsic compressive disease of the third nerve are to be contrasted with the pattern of intrinsic brain stem involvement of the third nerve nucleus where medial rectus or superior rectus function is more likely to be initially compromised.

The patient had minimal findings suggesting involvement of the left corticospinal and corticobulbar tracts: minimal right central facial weakness, minimal increase in deep tendon reflexes on the right side, and an equivocal right plantar response. The findings may have been produced by a slight shift of the brain stem to the left due to the small mass of aneurysm on the right side of brain stem. With such a shift, compression of the left cerebral peduncle against the tentorium might occur. In any case, these findings were minimal. The significant findings in this case clearly related to the third cranial nerve and it is these findings which allowed localization of the lesion prior to arteriography.

As regards the postoperative course, it is evident that this patient had severe involvement of the frontal lobes presumably as a result of bilateral infarction within the territory of the anterior cerebral arteries. In retrospect, the narrowing of the anterior cerebral arteries at their origin, presumed secondary to "spasm" noted at the time of arteriography, may have provided a clue as to the development of the complication. The neurosurgeon, faced with the decision as to the best time to intervene, would prefer as the ideal situation, the moment when arterial spasm has not yet developed or is no longer present but bleeding has not yet recurred. In reality the risk of recurrent hemorrhage is so great that the aneurysm should be clipped as soon as possible for example the day of presentation. Vasospasm can now be treated with calcium channel blockers and after clipping by increasing the blood pressure to increase perfusion. The typical angiographic appearance of aneurysms in this location is demonstrated in Figure 26-24. Occasionally large aneurysms can be demonstrated on the CT scan.

Middle cerebral bifurcation (Fig 26-25).

Case 26-9: This 46-year-old, right-handed, white, married male, was admitted to the neurology/neurosurgical services of the New England Medical Center on 6/10/66. He presented a history that 10 days prior to admission, he had the sudden onset of a severe, throbbing, supraorbital and vertex headache. The headache began while the patient was in bed in the early stages of sexual intercourse. The patient noted no weakness except that his tongue "felt funny" in articulation for approximately one minute. There was a transient difficulty in speech during this period.

Past history: Mild hypertension had been present.

General physical examination: Blood pressure was 160/100.

Neurological examination:

1. *Mental status* was intact.
2. *Cranial nerves* were intact.
3. *Motor system* was intact.
4. *Reflexes* were physiologic
5. *Sensory system* was intact.
6. Headache could be precipitated by *head movement*.
7. With *cervical flexion*, pain occurred in the neck and lumbar area occurred.

Laboratory data:

1. Skull and chest x-rays were normal.
2. *Electroencephalogram* revealed focal damage in the lateral aspect of the left hemisphere (focal 3 to 5 cps slow waves).
3. *Lumbar puncture* on the day following admission revealed opening pressure elevated to 270 mm. of water and closing pressure to 210 mm. of csf. The fluid was xanthochromic (yellow discoloration). In addition 38 fresh red blood cells per cubic mm. were present. Protein was elevated to 80 mg./100 ml. Hinton was negative.

4. *Arteriography* revealed a bilobed aneurysm at the trifurcation of the left middle cerebral artery measuring 8 x 4 mm. Spasm and narrowing of the proximal anterior and middle cerebral arteries were noted.

Hospital course:

On the day following admission, the patient complained of a few-minute episodes of numbness in the right face, tongue, and right upper extremity with thickness of speech. Examination now revealed right central facial weakness and slight slurring of speech. The patient also now complained of additional neck pain on extreme forward flexion. On June 12, 1966, the patient had another short episode beginning with numbness over the right thumb, spreading to the right hand and then to the angle of the mouth.

Because of the several episodes which occurred, following hospital admission, involving the right face, tongue, and hand in association with the finding of fresh red blood cells in the spinal fluid, it was considered likely that bleeding from the aneurysm was continuing to occur. Surgical therapy was therefore considered necessary to prevent additional (and possibly fatal) subarachnoid hemorrhage. On May 20, 1966 a left frontotemporal craniotomy was performed by Dr. Robert Yuan with subsequent plastic coating of the entire aneurysm to reinforce its wall. There was evidence of recent hemorrhage in the subarachnoid space with yellow discoloration of the meninges. In order to expose the aneurysm, it was necessary to remove the anterior tip of the temporal lobe back to a distance of 2.5 cm. There was a small amount (5 to 10 cc.) of intracerebral blood clot in the superior temporal region close to the aneurysm. The aneurysm itself had no actual neck that could be clipped. Several middle cerebral branches appeared to arise from the dome or lateral wall of the aneurysm.

In the postoperative period, the patient initially did well. A minor expressive aphasia was present, but the patient was alert and well oriented. However, fever and jaundice developed. With the development of significant alterations of liver functions approximately 7 days after surgery, the patient became confused and agitated. The prothrombin time fell to 3 per cent of normal and there was evidence of bleeding into the gastrointestinal tract at this time. The prothrombin deficit was corrected by administration of vitamin K. It was unclear, however, as to whether any minor intracranial bleeding occurred during this time. Some improvement in liver functions occurred, and the patient became more alert but continued to manifest inappropriate behavior, emotional lability, and disturbance of memory. He left the hospital against medical advice one month after surgery, on July 20, 1966.

The patient was readmitted to the hospital approximately one month later on August 13, 1966. For two days, the patient had been less active, appeared confused, glassy eyed, and failed to communicate. The degree of obtundation cleared when adequate dosage of the anticonvulsant medication, Dilantin, was administered. This fact taken on conjunction with the electroencephalogram, which demonstrated frequent focal spikes (excessive neuronal discharge) in the left temporal area (Fig. 29-1C) led to the conclusion that the episode which precipitated his readmission might well have represented a prolonged seizure discharge. The electroencephalogram also demonstrated an increase in slow wave activity in the left hemisphere, particularly the left temporal area indicating a possible increase in damage in the left temporal area. This appeared to be correlated with apparent progression of the patient's aphasia which was now receptive as well as expressive in nature. At the time of discharge, a severe expressive aphasia was still present.

Comment:

The sudden onset of severe headache during exercise or exertion (sexual intercourse in this case) is characteristic of subarachnoid hemorrhage. The location of the aneurysm was suggested by the symptoms relevant to the tongue and speech during the initial episode. The episode on June 11, 1966, involving numbness of the right face, tongue, and right upper extremity, could only indicate disease within the territory of the left middle cerebral artery. The lumbar puncture at this time indicated not only evidence of the initial leakage of blood 10 days prior to admission (an elevation of cerebrospinal fluid protein and a xanthochromia), but also fresh red blood cells suggesting that additional leakage of blood had occurred.

The nature of the episodes which occurred on June 11 and 12 is not certain. Most likely these were ischemic in nature related to decrease in blood flow as a result of clot formation within the aneurysm or from spasm of the adjacent portion of the middle cerebral artery. At times, however, symptoms such as rapidly spreading numbness occurring in episodes may suggest focal epileptic discharge. The development of an area of excessive discharge would not be unusual since this aneurysm involves those

middle cerebral artery branches which are supplying the cerebral cortex. In addition hemorrhage within the Sylvian fissure is likely to damage the surrounding cerebral cortex. Blood and iron are epileptogenic.

The patient's course following surgery was complicated by the development of severe liver dysfunction. The etiology of this problem was never clear, the various studies suggesting either a toxic hepatitis related to various drugs and anesthetic agents or a variety of obstructive jaundice. What the patient's eventual recovery would have been had this problem not developed is uncertain. It is clear, however, that during this post-

operative period the patient did develop significant impairment of language functions, possibly related to infarction or oozing of blood in areas supplied by the middle cerebral artery. It is also evident that a seizure focus had developed in this area. Such seizure foci may have developed in relation to the preoperative hematoma noted in the temporal lobe, in relation to the surgical manipulation of the area, or in relation to the postoperative complications.

Today (2002), the history presented by this patient would have prompted an immediate CT scan and a lumbar puncture if the CT scan were negative. An arteriogram would have been performed immediately after these studies. Surgery would have been performed immediately after the evaluation of the angiographic studies to prevent the recurrent episodes of bleeding.

Anterior communicating -anterior cerebral junction(Figs. 24-26, 24-27, 24-28)

Case History 26-10. . (Patient of Dr. John Sullivan). This 49-year-old, right-handed truck driver was transferred from his local community hospital for evaluation of subarachnoid hemorrhage.

The patient had experienced occasional frontal headaches for the previous 5 years. In June, 1965, while changing a tire, he had a severe throbbing frontal headache which cleared after thirty minutes. Since that time he had experienced daily throbbing frontal headaches, usually present on arising in the morning. On September 4, 1965, the patient had the onset of a particularly severe headache which began while he was engaged in heavy work on a boat. There was associated stiffness of the neck, nausea, vomiting, and a general sensation of weakness.

Evaluation at his local community hospital revealed papilledema (blurred optic disk margins on funduscopic examination). Nuchal rigidity was present. The lumbar puncture demonstrated grossly bloody cerebrospinal fluid. He was subsequently transferred to the neurology/neurosurgical services of the New England Medical Center on 9/7/65.

Past history:

1. Hypertension had been noted in June, 1965.
2. The patient's father had died at age 59 of a cerebrovascular accident.

General physical examination:

1. Blood pressure was moderately elevated to 180/100. Pulse was 60.
2. No bruits (murmurs) were present over the skull.
3. A significant degree of nuchal rigidity was present. The neck could not be actively or passively flexed.

Neurological examination:

1. Mental status:
 - a. The patient was somnolent but could be aroused, although attention span was noted to be shortened.
 - b. He was oriented for place and situation but confused as to time.
 - c. Digit span was shortened to 5 forward and 4 in reverse.
 - d. The patient was unable to do calculations.
2. Cranial nerves:
 - a. Sense of smell was decreased on the right side.
 - b. Disk margins were indistinct on examination of the fundus. Arterioles were tortuous and irregular.
3. Motor system:
 - a. Strength and tone were intact.
 - b. Cerebellar tests were normal.
4. Reflexes:
 - a. Deep tendon reflexes were symmetrical.

- b. Plantar responses were flexor.
- 5. Sensory system: All modalities were intact.

Laboratory data:

1. Bleeding, clotting, and prothrombin times were all normal. Platelets were normal on smear.
2. Chest and skull x-rays were normal.
3. *Arteriograms* demonstrated an aneurysm of the anterior communicating artery which extended posteriorly and to the right. The aneurysm filled from the left carotid circulation.

Hospital course: During the evening of September 11, 1965, the patient became lethargic and would not speak or obey commands. Blood pressure rose to 240 mm. systolic. The patient became totally unresponsive with pupils fixed and dilated and with incontinence of urine. Deep tendon reflexes were exaggerated with plantar responses extensor. Within minutes, the patient became responsive again; pupils were reactive, although the right remained sluggish. The patient made purposive movements and obeyed commands. Lumbar puncture subsequently indicated grossly bloody spinal fluid. The patient remained confused and less alert with a tendency to fall asleep.

On September 17, 1965, the patient again suddenly complained of violent headache and lost consciousness for approximately 30 minutes. The right pupil became dilated, and the right eye deviated to the right suggesting a right medial rectus weakness. The blood pressure again rose to 240/140. As previously, the patient regained consciousness. Although confused, he had no clearly lateralizing signs. Subsequent lumbar puncture again revealed the presence of fresh red blood cells.

Because repeated episodes of bleeding had occurred, surgical therapy was undertaken. On September 21, 1965 a left frontal craniotomy was performed by Dr. Robert Yuan. The left frontal pole was resected exposing the left anterior cerebral artery and the aneurysm which arose from the anterior communicating artery. The medial surface of the right frontal lobe was cystic and contained 20 cc. of hematoma. The hematoma was evacuated. The aneurysm was reinforced by spraying with a plastic coating.

Neurological examination approximately 1 week after surgery indicated that the patient was confused and disoriented, with a "rather negative response" refusing to follow directions and to speak to examiners. Blood pressure was noted to be extremely labile with a drop of 50 mm. of mercury systolic when the patient moved from prone to sitting position. Equivocal Babinski signs were present, and the patient was incontinent of urine and feces.

Reevaluation on November 17, 1965, approximately two months after surgery, indicated that although the patient was ambulatory and able to take care of his daily needs, he remained confused for time and place. When the patient was examined 6 months after surgery, confusion was no longer present; intellectual functions were consistent with his education.

Approximately 2 years after surgery, the patient, who had recently been married, reported that he was impotent, unable to obtain an erection.

Comment:

In this case, the history of sudden onset of severe headache and stiffness of the neck, precipitated by exertion, clearly suggested a subarachnoid hemorrhage originating from the rupture of an intracranial aneurysm. It is likely that several episodes of subarachnoid bleeding occurred in June and September of 1965. While the clinical findings of somnolence and confusion with a decrease in olfaction on the right may have suggested the possibility of an anterior communicating-artery location, these were certainly not firm diagnostic clues. The episodes characterized by sudden alteration in blood pressure, while nonspecific, might have raised the question of orbital-frontal, anterior cingulate, or hypothalamic effects (areas within the distribution of the anterior-cerebral arteries).

The negativity of the patient following surgery undoubtedly indicated preoperative and operative damage to the orbital and prefrontal areas. The bilateral Babinski signs and the incontinence of urine and feces in the postoperative period probably reflected damage to the parasagittal motor and premotor areas within the distribution of the anterior cerebral arteries. The impotence may have reflected damage at the frontal or hypothalamic level.

Today, an initial episode such as occurred in June 1965 would have prompted a CT scan and a lumbar puncture if that study had been negative. Of course many exertional headaches are not a result of

subarachnoid hemorrhage. Nevertheless the more serious entity must be ruled out at the emergency room level, since the mortality and morbidity of the frequent recurrent hemorrhage are so high. Again the use of early arteriography and early surgery are to be emphasized.

Case 26-11 illustrates many of the neurologic aspects of bacterial endocarditis.

Case 26-11: This 34-year old right hand married white male hair dresser was admitted with a one month history of night sweats, fever to 102-103° F., generalized aches and pains. Within the previous 3-4 months, the patient had undergone repeated dental procedures for dental infection. He had been reported to have a mild heart murmur 2-3 years prior to admission. His urine had recently become dark. The day prior to admission he had noted a small hemorrhagic lesion on the dorsum of his left hand.

Physical exam:

1) Skin: A small indurated red lesion dorsum left hand and a small red lesion under the nail bed 3rd left toe.

2) Heart: A grade IV/VI high-pitched holosystolic murmur was present at the apex; and a high-pitched II/VI murmur at the base; both not previously noted to this degree.

3) Temperature was elevated to 101° F

Neurological examination: Entirely within normal limits.

Clinical diagnosis: Bacterial endocarditis with systemic emboli but without neurological symptoms at this point.

Laboratory data:

1) **CBC:** Anemia with hematocrit 31 and hemoglobin of 10.1.
White blood count was 9900 with differential of 78% poly-morphonuclears and 9 atypical lymphocytes.

2) Sedimentation rate was elevated to 38 mm.

3) **Urinalysis** indicated 8-10 red blood cells per high power field.

4) All three **blood cultures** drawn on the day of admission produced growth of streptococcus viridans (alpha hemolytic).

5) **Echocardiogram** indicated a prolapsed mitral valve with probable mitral insufficiency. In addition, irregular densities on the mitral leaflets suggested vegetations.

Hospital course: All of these findings were consistent with a diagnosis of subacute bacterial endocarditis with evidence of microemboli to extremities (skin lesions) and to kidneys (hematuria). The patient was begun on high dosage intravenous penicillin (24 million units per day) with an excellent response as regards fever and general symptoms. Thirteen days after admission he again developed a temperature elevation. The following day, at 2 p.m., he abruptly developed difficulty with speech and a right hemiplegia. Over the next 2 hours this rapidly evolved to the following neurological state.

Neurological examination:

1) Mental Status and Language Function

a) The patient was drowsy - holding the left side of his head as though in pain.

b) He was mute.

c) He was unable to carry out any spoken or written commands.

2) Cranial Nerves

a) The patient neglected the right visual field and had no response to threat in the field.

b) The fundoscopic exam indicated blurring of the disc margins on the left.

c) Right central facial weakness was present.

d) Pain sensation was decreased on the right side of the face.

3) **Motor System:** A flaccid right hemiparesis was present although some purposive withdrawal of the right arm and leg occurred on painful stimulation.

4) Reflexes

a) Deep tendon reflexes were increased bilaterally but right were greater than left with clonus of the right ankle.

- b) The right plantar response was extensor, the left flexor.
 - 5) *Sensation*: A right-sided hypalgesia was present. Other modalities could not be tested.
 - 6) Neck and Skin
 - a) No nuchal rigidity was present.
 - b) New splinter hemorrhages were present under the nails of the upper extremities.
- Neurological diagnosis:** Cerebral embolus left middle cerebral artery, with possible mycotic aneurysm and possible hematoma left middle cerebral artery secondary to bacterial endocarditis.

Laboratory data:

An immediate CT Scan (Fig. 26-30) demonstrated a large intracerebral hematoma involving the left basal ganglia and insula with massive shift of the left hemisphere to the right.

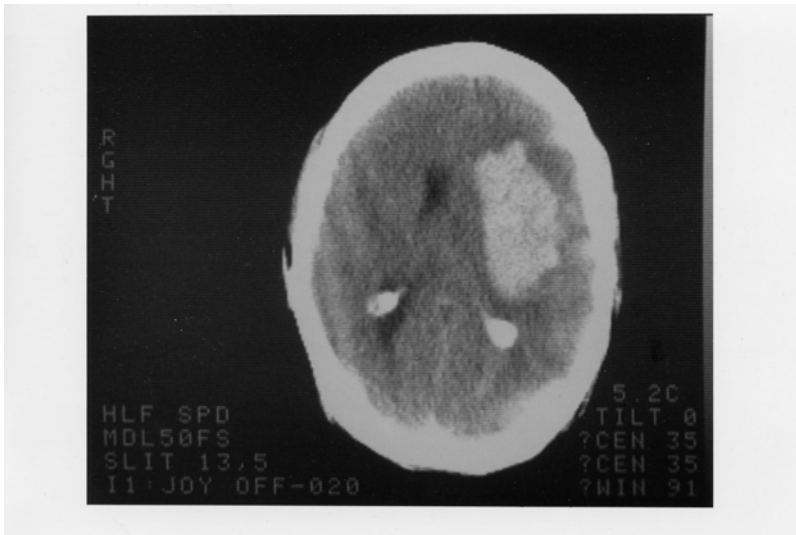


Figure 26-30.

2. An immediate arteriogram: (Fig. 26-31A) demonstrated a small aneurysm (arrow) arising from a small branch of the left middle cerebral artery (MCA) within the Sylvian fissure. A large avascular area surrounded this aneurysm with upward and lateral displacement of anterior cerebral arteries, medial displacement of lenticular striate, branches of the MCA and lateral and downward placement of the cortical MCA branches.



Subsequent course: That evening Dr. Robert Johnson removed a large intracerebral clot. Over the next 2 weeks the patient began to have some improvement in his right hemiparesis and aphasia. However two weeks after surgery, he developed right-sided focal status epilepticus. The patient had been receiving Phenytoin (Dilantin) but the level was low. Intravenous Phenytoin, intravenous Dexamethasone and Mannitol were administered. The CT scan now demonstrated a larger hemorrhage surrounded by edema. The patient was taken to surgery and additional old clot and a small amount of recent clots were removed. The patient failed to respond. He developed fixed dilated pupils and bilateral Babinski signs. The arteriogram (Fig.26-31 B,C) was repeated and now demonstrated a much larger aneurysm (measuring 11 mm vs 4-5 mm in previous films). There was also evidence of additional shifts of the anterior cerebral artery and internal cerebral vein. Anterior-frontal branches of the middle cerebral artery were occluded. Regression occurred and 8 days later patient met brain death criteria with absence of all brainstem reflexes, no spontaneous respirations and an absence of all cerebral electrical activity (silent EEG).

Comment: This patient presents a panorama of almost all of the cerebral complications of bacterial endocarditis including:

- a) Multiple septic emboli to brain, kidney, and small peripheral arteries;
- b) Mycotic aneurysm;
- c) Intracerebral hematoma
- d) Eventual mortality.

The mycotic aneurysm with eventual rupture was not a feature noted on presentation but instead was a late complication. (A silent unruptured aneurysm may well have been present on admission.) This subacute delayed presentation is more common in streptococcal endocarditis as opposed to the more virulent staphylococcal infections where acute intracranial presentations are the rule.

In this case, the aneurysm when initially discovered was small and associated with an intracerebral hemorrhage.

The aneurysm continued to enlarge after evacuation of the initial hematoma and eventually additional hemorrhage occurred. Not all patients with mycotic aneurysm will have intracranial hemorrhage. In the series of Brust et al (1990), 41% were associated with rupture. Of 20 aneurysms followed with angiography or CT scan, ten became smaller or disappeared, 10 remained unchanged or enlarged despite an adequate treatment course with antibiotics. In the present case, initial rupture occurred almost 2 weeks after admission and beginning of antibiotic treatment.

The recommended approach in patients with endocarditis to avoid the fatal complications of mycotic aneurysm rupture is to perform 4 vessel angiography in those patients with endocarditis who develop neurological symptoms. If a mycotic aneurysm is found, prompt surgical treatment (clipping) should be performed. Unfortunately many patients with mycotic aneurysms have no neurological symptoms prior to rupture. To perform angiography in all patients with bacterial endocarditis, would not be practical and would fail to detect aneurysms that developed after the studies. However, when long-term anticoagulation is planned in patients on the completion of antibiotic treatment to prevent additional emboli, angiography should be performed or repeated. The entire role of anticoagulation in bacterial endocarditis remains unclear. (See Salgade et.al 1987 and Hart et.al 1987, 1990). MRI may have an increasing role in non-invasive diagnosis, since MRI angiography should be able to detect aneurysms greater than 2-3 mm in diameter

Figure 26-32. Arteriovenous malformation in the right parietal area demonstrating the abnormal tangle of vessels and infarction of the surrounding cerebral cortex and white matter.

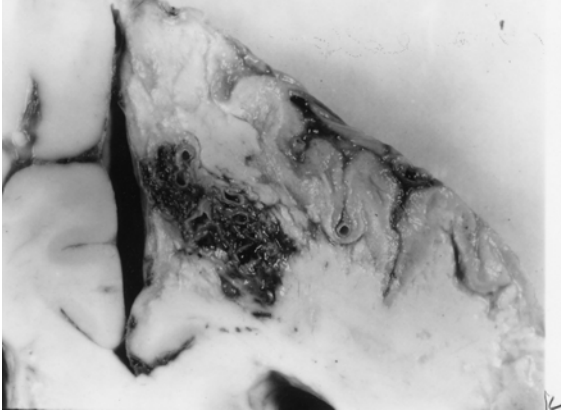


Figure 26-32. In this case, the malformation was fed mainly by the right anterior cerebral artery and drained into the superior sagittal sinus. This 46-year-old woman had, as a primary problem, subarachnoid hemorrhage from an anterior-communicating saccular aneurysm, with other unruptured aneurysms at left posterior communicating, and right superior cerebellar. (Courtesy of Dr. John Hills).

Case history 26-12 provides an example of a long-term unruptured arteriovenous malformation presenting as a seizure disorder.

Case 26-12: This 51-year old right-handed female experienced two nocturnal generalized convulsive seizures 6 years prior to evaluation . Evaluation by Dr. Robert Bazemore at that time revealed a significant 30-year history of minor episodes: “little sensations”. The patient described sudden strange feelings as though moving in slow motion. With other episodes she would feel at a distance from her surroundings with a sense of detachment at times with a strange odd smell. After 2-3 minutes the “spell” would alter, she would feel depressed with a sense of terrible fear. The patient also had a long history of migraine headaches (bilateral throbbing) which were often preceded by visual auras more prominent in the right visual field. The neurological examination was normal. She was treated with anticonvulsant (Phenytoin). When seen by the author for other unrelated neurological problems 6 years later , the interval history indicated no additional generalized seizures but complex partial seizures had continued.

Neurological examination: entirely within normal limits.

Clinical diagnosis : Simple and complex partial seizures of temporal lobe origin .

Laboratory data:

1. The *CT scan without enhancement* now demonstrated a calcified lesion in the anterior-medial right temporal lobe which enhanced with contrast (Fig. 26-32A). Large early draining veins were also noted (Fig. 26-32B).

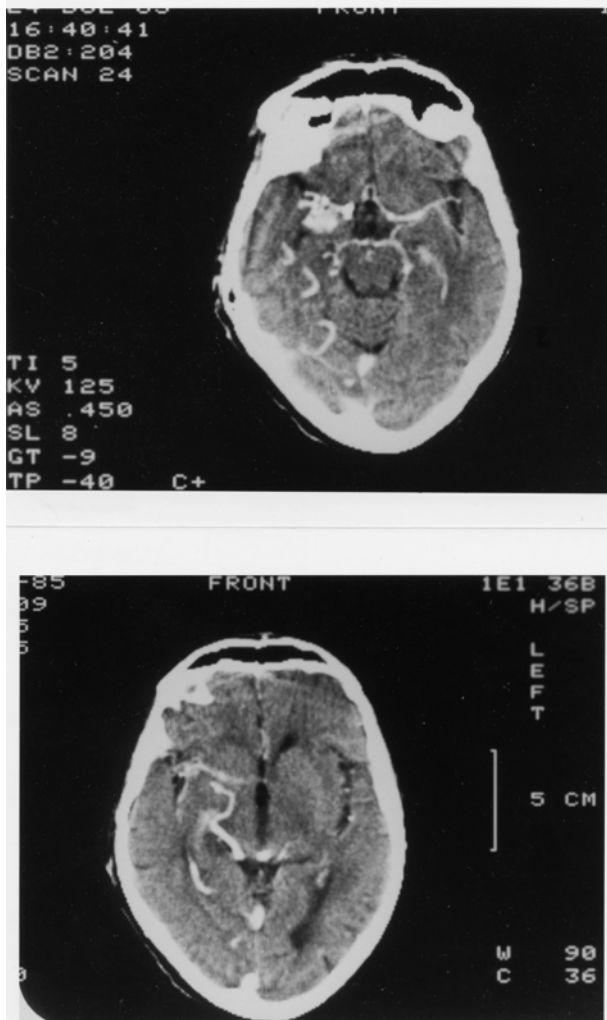


Figure 26-33. Arteriovenous malformation. Right anterior temporal:
Case History 24-12 CT Scan. This 51-year-old right-handed female
was evaluated in 1983. She had generalized seizures in 1977 and 36-
year history of complex partial seizures. She would feel "weird
sensations" and detached with a "strange odd smell", then a sense of
terrible fear. She also had a history of migraine headaches preceded
by visual auras, and a normal neurological examination. was not
remarkable. The CT Scan without contrast demonstrated a calcified
lesion in the right anterior temporal lobe (not shown).
A). With contrast a large enhancing lesion was present in the deep
Sylvian fissure area - involving anterior medial temporal areas, uncus
and adjacent insula.
B) At a higher level of section a large draining vein was visualized (see
also fig 26-35 and text for details).

Subsequent angiographic studies confirmed the anterior venous malformation with supply from right internal carotid, middle cerebral and anterior choroidal arteries (26-33A) and the presence of shunting into a large early draining vein (26-33B).

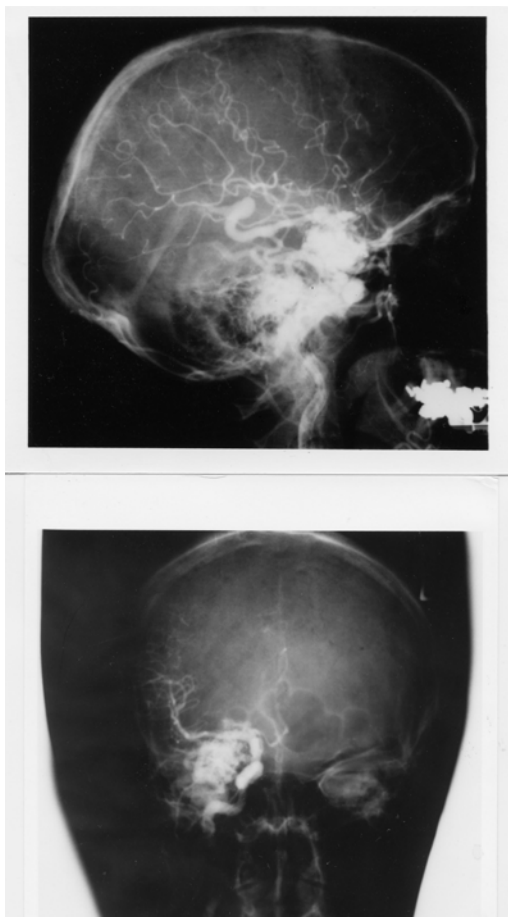


Figure 26-34. Arteriovenous malformation: Right anterior temporal lobe. Right carotid arteriograms. Case History 24-12

- A) Malformation - supplied by right internal carotid, middle cerebral, and anterior choroidal branches.
- B) There is early shunting of arterial blood into a large draining vein. See Text and Fig. 26-34 for details.

Comment: This patient presented with classical complex partial seizures originating in the right temporal lobe. No definite evidence of either subarachnoid or intracerebral hemorrhage was present over 35 years. With the use of CT and MRI scan, more of these lesions are being identified in an unruptured state in patients investigated for seizures and headaches.

Considerable controversy remains as to the appropriate therapy for the unruptured cerebral arteriovenous malformation (compare Aminoff, 1987 and Heros and Yong-Kwang, 1987). Long-term follow-ups - 12-20 years - does suggest a 25-39% risk of hemorrhage with a mortality from that hemorrhage of 10-14%. The risk of recurrent hemorrhage the first year is 6% with the subsequent annual risk for hemorrhage for both ruptured and unruptured 3% per year (see also Crawford et al, 1986, Brown et al 1988, Rigamont, et al 1988).

Surgical therapy involved excision after ligation or embolization of feeding vessels (Stein and Wolpert, 1986, Stein and Mohr, 1988, and Mohr, et al 1986).

CHAPTER 27: NON VASCULAR SYNDROMES : TRAUMA, TUMORS, INFECTIONS, TOXIC METABOLIC AND SYSTEMIC DISORDERS

I TRAUMA

Case 27-1 presents an example of an epidural hematoma seen in 1963 prior to modern neuroimaging.

Case 27-1: This twenty-two-year-old, white airman, during a winter storm, was involved in an auto accident at 11:30 p.m., in which he struck his head against the windshield. He also sustained minor abrasions of the shoulder, hands and chest. The patient apparently was dazed, perhaps unconscious, for a matter of seconds to minutes. He was taken by ambulance to the emergency room of the nearby army hospital where a brief evaluation indicated that the patient was alert, without definite neurological findings, and apparently without significant injuries. Skull X-rays did indicate a linear fracture over the right temporal area which did not, however, definitely cross the major groove of the middle meningeal artery. The patient was, therefore, admitted to the intensive care ward for head injury observation.

The patient was apparently alert upon his arrival on the ward. It should be noted, that the major attention of the physicians in the emergency room and of the nurses on the intensive care ward was given to four other patients from the same accident who sustained very severe and obvious injuries. However, by 5 a.m., the patient was reported by the nurses to be agitated and confused.

Neurological examination: (8 a.m.)

1. *Mental Status:* The patient was agitated and unable to cooperate. He was sitting up in bed, holding his head, moaning and hyperventilating to a marked degree. He answered only occasional questions and then with a yes or no.

2. *Cranial Nerves:* intact except

Fundi: The examination was negative but incomplete.

Pupils: There was a bilateral but sluggish response to light. A minimal asymmetry was present. The right pupil was perhaps slightly larger and slightly more sluggish than the left.

3. *Motor System:* All limbs were moved spontaneously. There was a variable increased resistance to passive motion, but this was apparently due to the patient's inability to cooperate.

4. *Reflexes:* Deep tendon reflexes were increased bilaterally. Plantar responses were bilaterally equivocal.

5. *Sensation:* Pain sensation appeared to be intact.

6. *Neck:* There was variable resistance to attempted flexion.

7. *Head:* The patient moaned when palpated over left or right temporal areas.

Neurological diagnosis : Possible evolving acute bilateral epidural or subdural hematoma

Subsequent course: The patient was to be evaluated by the civilian neurosurgical consultant, whose arrival was delayed by several other emergencies and a snowstorm. In the meantime, progression occurred.

Neurological examination (4 p.m.): The patient was now deeply comatose with little response to stimulation. The pupils were now bilaterally fixed and dilated. The four limbs were extended in a decerebrate posture with significant spasticity on passive motion. The degree of spasticity in the upper limbs could be modified by tonic neck maneuvers. The plantar responses were bilaterally extensor. Spontaneous respirations were now irregular and infrequent, and the patient required the assistance of a mechanical respirator.

Neurological diagnosis: Acute tentorial herniation with brain stem compression secondary to epidural hematoma.

Subsequent course: A general surgeon immediately performed definitive therapy. Bilateral burr holes were placed. An epidural hematoma over the right temporal-parietal area was evacuated and the

bleeding middle meningeal artery branch was coagulated and ligated with a significant rapid improvement in the patient's status. Follow-up examination approximately two months later indicated that the patient had returned to active duty but was experiencing some problems related to changes in recent memory and to changes in motivation and personality. No significant motor or sensory findings were present. Minor and inconsistent asymmetry of deep tendon reflexes was present.

Comment: This patient followed the usual pattern of a short lucid period followed by the rapid progression of confusion, agitation, coma and brain stem deterioration of function. As indicated by Plum and Posner (1980), the development of hyperventilation is often indicative of a midbrain-upper pontine stage of damage from an expanding supratentorial lesion. The early appearance of hyperventilation followed by bilaterally fixed dilated pupils and a decerebrate state may well indicate that the supratentorial lesion was producing a more central downward compression of the midbrain and less of a lateral uncal-type compression. In any case, it is evident that brain stem compromise was progressing rapidly. So rapidly, in fact, that therapy had to be undertaken immediately. In such a case, there was no longer time for the transfer of the patient to a specialized treatment center and no longer any time for specialized laboratory studies. Today, such a patient would have undergone CT scan studies at the time of emergency room evaluation or at the first sign of change in mental status. Similar cases of recovery of function from brain stem compression in patients with acute subdural or epidural hematomas have been reported by Brendler and Selverstone (1970).

The following case provides an example of chronic bilateral subdural hematomas

Case 27-2. (Patient of Dr. Alex Danylevich). This 83-year-old white female was transferred from her local hospital because of increasing confusion. Two months prior to admission, she had been involved in a motor vehicle accident sustaining fractures of her ribs and left clavicle. She also struck her head and had a scalp hematoma in the right frontal area. She was admitted to her local hospital at that time for several days. She was described as having post-traumatic anterograde and retrograde amnesia and obtundation which cleared over her hospital stay. She returned to her usual activities. Two months after the trauma she re-entered her local hospital with a three day history of increasing confusion and lethargy. When she became mute she was transferred to St. Vincent Hospital. Serum sodium at her local hospital had been low at 124 mEq/liter and CSF protein was reported at 62 mg%. EEG was reported as diffusely slow.

Neurological examination:

1. *Mental status:* She was relatively lethargic but could be aroused to an alert state. The patient was mute and did not follow commands even when relatively alert.
2. *Cranial nerves:* Pupils were 2 mm. and reactive. Sudden paroxysmal nystagmoid deviations of the eyes to the right occurred during the exam.
3. *Motor system:* Strength was intact. Tone was increased in the right leg.
4. *Reflexes:* Deep tendon stretch reflexes were symmetrical. Plantar responses were extensor bilaterally.
5. *Sensory system:* Pain responses were intact.

Clinical diagnosis: Chronic subdural hematomas, probably bilateral .

Laboratory data:

1. The CT scan (Fig. 27-3) demonstrated significant bilateral chronic subdural collections much denser on the left where the lateral ventricle was obscured and shifted to the right. The right lateral ventricle and sylvian fissure were enlarged. There was a question of additional recent rebleeding into the subdural collection on the left.
2. Serum sodium was low at 117 mEq/liter. Serum osmolality was 236. Urine sodium was 53 mEq/liter.

Hospital course: Serum sodium was corrected. Then, bilateral subdural hematomas were removed via burr holes on the right and a bone flap on the left where substantial chronic membrane and fluid were found. Neurological examination eight hours after conclusion of the procedure, indicated an alert patient who had no apparent language disorder and no weakness. Follow-up CT scan ,6 days after surgery revealed re-expansion of the cerebral hemispheres. Considerable cortical atrophy was

now evident. This was presumably long-standing predating the subdural hematomas. She was transferred back to her local hospital, 10 days after surgery. At that point she was alert; ambulating with assistance and was able to feed herself. She did develop transient right face and hand focal motor seizures which were treated with anti-convulsants.

Comment: If the history of trauma two months previously had not been present with a prior hospital admission related to the trauma, the confused obtunded mute state in this patient might easily have been attributed to a metabolic encephalopathy (low serum sodium) or to the cortical atrophy of a senile dementia of Alzheimer's type. Many patients with primary cerebral disease will develop a low serum sodium due to inappropriate secretion of anti-diuretic hormone with retention of water and dilution of serum sodium. The mute state in this patient in retrospect probably reflected the severe involvement of the dominant left cerebral hemisphere. The sudden eye movements to the right probably represented focal seizure activity originating in the left frontal eye fields, not far from the cortical area providing the focus for the post operative seizures.

In some patients without a definite history of trauma, the predominant findings may be those of a progressive bilateral frontal lobe involvement with confusion, bilateral grasp reflexes, and a frontal lobe apraxia of gait. In such patients, the nature of the pathological process involving the frontal lobes may be uncertain. The differential diagnostic list may include metastatic disease, frontal parasagittal meningioma or frontal glioma.

There are patients who are at increased risk for subdural hematomas: patients receiving anticoagulant medications, or patients with bleeding disorders, e.g., as in leukemia. The problem is more common in the elderly, in chronic alcoholics, and in patients with Parkinson's disease perhaps because such population groups are more prone to unsteadiness and falls. In the patient with cortical atrophy as in Alzheimer's disease, the bridging veins may be stretched and thus more prone to tear. In addition, the patient is unable to recall minor trauma and is already confused. In addition, because of the atrophy, a large amount of blood may accumulate in the subdural space without producing early symptoms of headache and other symptoms.

The problem also exists in the infant during the first year of life. The picture presented, however, differs significantly from that seen in the adult because in the infant, separation of the sutures may occur, allowing the intracranial cavity to expand. The onset is then often nonspecific and nonfocal: an enlargement of the head, a failure to thrive, a failure to gain weight, a failure to reach developmental landmarks. At times, generalized seizures, vomiting, and papilledema may be noted. The etiology often relates to presumed birth trauma.

A related problem may also be seen in infants following meningitis. This is the problem of subdural effusions usually occurring in relation to *Haemophilus influenzae* meningitis. The diagnosis of both subdural hematoma and subdural effusions may be made in the infant by CT or MRI scan replacing the earlier technique of subdural taps. The cerebrospinal fluid in these cases is often found to be abnormal with the presence of blood or xanthochromia and an elevated protein content.

II TUMORS

The following case history provides an example of the course of a low grade glial tumor.

Case 27-3: This 41 year old right handed white widow was admitted to the hospital because of increasing frequency of seizures. At age 30, eleven years prior to admission, the patient experienced her first generalized convulsive seizures. The neurological examination and the electroencephalogram were normal. Four years prior to admission, the patient had a change in the character of her seizures, she began to experience focal seizures involving the right arm and leg. These would begin with the sensation of a "chill" or stiffening of the right leg and a "numbness" (a tingling) which would then spread to the lower back. At the same time, weakness would occur in the right leg followed by repetitive clonic movements of the right arm. During this time, the patient would be unable to talk distinctly but would be aware of her surroundings. Although the episode continued for several minutes, there was no apparent loss of consciousness. Examination by Dr. John Hills at that time revealed a slowness of response but no definite neurological deficits. The EEG was again normal. Neurological evaluation three years later (one year prior to admission) was again unremarkable although focal seizures were still occurring every 2-4 weeks. Evaluation 2 months prior to admission, now indicated a more increase in deep tendon stretch reflexes in the

right lower extremity and an equivocal plantar response on the right side .Hospital admission finally occurred because the weakness experienced in the right leg during the seizure was becoming more severe.

Neurological examination

1. *Mental status*: The patient was anxious and tremulous with moderate psychomotor retardation and poor attention span. Digit span was limited to 5 digits forward and 4 in reverse .However orientation, memory ,delayed recall , calculations and language function were all intact.
2. *Cranial nerves*: All were intact with no papilledema.
3. *Motor system*: Strength, gait and cerebellar signs were all normal.
4. *Reflexes*: Deep tendon reflexes were slightly increased on the right side. The plantar response on the right was equivocally extensor.
5. *Sensory system*: Intact except for a minimal bilateral decrease in sensation at the toes.

Clinical diagnosis: Left parasagittal tumor most likely a meningioma, low grade glial tumor such as oligodendroglioma or low grade astrocytoma considered possible but very unlikely.

Laboratory data:

1. Chest and skull x rays ,radioactive brain scan(Hg 197) and left carotid arteriogram were all normal.
2. *EEG* was now mildly abnormal because of occasional focal sharp waves ,left parietal parasagittal area.
- 3.*Pneumoencephalogram* demonstrated a slight downward depression left lateral ventricle suggesting a possible left parasagittal mass. The CSF obtained was normal.

Subsequent course: Since the brain scan and arteriogram were normal, a meningioma was considered unlikely and a low grade glioma was considered the most likely diagnosis. The lack of calcification on the skull x rays was considered a point against the diagnosis of an oligodendroglioma and more in favor of a low grade astrocytoma. Since the patient was relatively free of neurological deficit and the dominant hemisphere was involved, neurosurgical intervention was deferred .Her anticonvulsant medications were readjusted. Frequent office evaluations indicated that significant progression was occurring with increasing weakness of the right leg, and an inability to form letters in handwriting. .Four months after hospital discharge ,the patient now had a right central facial weakness ,a mild right hemiparesis, and increased deep tendon stretch reflexes on the right and a right Babinski sign. Speech was dysarthric with a minor degree of misnaming or inability to name objects. A left carotid arteriogram now indicated a deep left posterior frontal mass lesion. There was also a suggestion of abnormal vascularity in the region of the pericallosal and callosal marginal branches of the anterior cerebral artery. Surgical exploration of the left frontal area indicated slight discoloration of and widening of gyri. Probe counting located an area of increased uptake of isotope (P32) at 16X normal in the mid and posterior frontal area. A partial frontal lobectomy was performed from the level of the sphenoid wing laterally and forward but sparing the speech areas. However tumor was still present at the posterior margin of the resection . Histologic examination of the tumor removed indicated a grade I- II astrocytoma. Following surgery ,the right sided weakness progressively improved, speech was unchanged. Following hospital discharge the patient ,received a 3 month course of supervoltage radiation (7,500 roentgens)directed to the left frontal parietal area. When last evaluated 18 months after surgery, there was a moderate disorientation for time , a nominal aphasia a slowness in following commands ,a perseveration of speech and performance, a right central facial weakness and a clumsiness in following commands.

Comment: The onset of seizures at age 30 ,always raises the question of a possible brain tumor. The initial seizures however were generalized convulsive seizures and the neurological examination and the EEG were normal, thus decreasing the risk of a tumor. When focal seizures appeared at age 36,the risk of a tumor was significantly increased but still ,the exam and the EEG remained normal .In retrospect ,the slowness of response might have suggested some frontal lobe involvement. By age 41, it was evident that a focal process was slowly evolving with some involvement of parasagittal motor cortex. Again the psychomotor retardation and the deficit in digit span at a time that delayed recall was normal (possibly consistent with an impairment of working memory) might have suggested some degree of. prefrontal involvement. Certainly, by the time of surgical intervention, 11 years after onset of symptoms, the pace of progression had accelerated. This might have indicated some alteration in the basic biological activity of the tumor.

Finally a note about diagnostic techniques . This patient was initially seen in 1956 and hospitalized in late 1967. At the time CT scan and MRI were not yet available. Today, an adult with onset of seizures at age 30 would have undergone an MRI or at least a CT scan with contrast. The diagnosis would have been made much earlier in time but the eventual treatment and results of treatment would probably not differ significantly from those obtained in 1967. The role of radiotherapy in low grade gliomas remains controversial. There is a role once transformation to a higher grade of malignancy has occurred.

MALIGNANT GLIOMAS

The following case demonstrates the apparent acute (possibly stroke like) onset and rapid progression of a very malignant glioblastoma multiforme.

Case 27-4 (patient of Dr. Tom Mullins): This 68 year old right handed white male was admitted to St Vincent Hospital with an apparent 4 to 5 day history of difficulty in doing calculations and in speaking, “he could think of the word ,but had difficulty getting it out”.

Neurological examination :

1. *Mental status and language function:* Speech was limited to short phrases with loss of connectors and sentence structure. Writing was impaired but, repetition, comprehension, naming and reading were intact.
2. *Cranial nerves:* Intact.
3. *Motor system:* Strength and gait were intact .However fine motor movements of the right hand were impaired .
4. *Reflexes:* Tone was increased on the right. The right patellar reflex was increased. Bilateral Babinski signs were present.
5. *Sensory system:* Intact.

Clinical diagnosis: Diagnosis was uncertain .The abrupt onset suggested a possible vascular event such as an embolus in the middle cerebral artery territory but the overall pattern including bilateral Babinski signs without significant hemiparesis was unusual. Thus other possibilities had to be considered including focal herpes simplex encephalitis, tumor or a small lobar hemorrhage.

Laboratory data :

1. EEG : Focal left hemisphere delta and theta slow wave activity was present.
2. CT scan(Fig.27-7):A. The non enhanced study demonstrated a low density mass in the mass in the left frontal-parietal parasagittal region with areas of hemorrhage. B. The contrast enhanced study demonstrated an irregular rim of enhancement.
3. Angiogram indicated an avascular mass in the left frontal-parietal area.

Subsequent course: Dr. Alex Danylevich performed a subtotal resection of this tumor which was found to contain blood clot and cystic fluid. The histology of the tumor was glioblastoma multiforme (Fig.27-5). The patient subsequently received 4000cGy whole brain radiation and an additional 2000cGy to the tumor site. Three months following surgery ,the patient developed increasing obtundation. CT scan revealed a large left frontal necrotic mass. Fever, hypocalcemia and hypernatremia developed and he expired one month later.

Comment: This patient presented with what appeared to be an abrupt onset of language problems raising the question of a cerebrovascular accident. In retrospect , it was evident on the CT scan and at surgery that the acute onset reflected the hemorrhage and necrosis which had occurred within the tumor. This was a rapidly growing ,extremely malignant tumor which apparently had outstripped its blood supply despite the neovascularity.

III INFECTIONS

FOCAL

Subdural empyema

The following case provides an example of subdural empyema complicating frontal sinusitis.

Case 27-5. This forty-eight year old, right-handed, white male was referred for evaluation because of headaches and papilledema. For 3 weeks prior to admission, the patient had severe bifrontal headaches which were constantly present and interfered with sleep. One week prior to admission, the patient developed a fever of 105° with a white blood count (WBC) of 25,000. X-rays indicated "sinusitis". The patient was hospitalized at his local community hospital. Confusion soon developed. Three days prior to transfer to a neurologic unit, the patient had a series of seizures characterized by turning of the head and eyes to the left. Lumbar puncture had indicated clear cerebrospinal fluid with pressure of 300 mm. and protein increased to 65 mg./100 ml. The patient had chronic right nasal discharge for ten years. Eight weeks prior to admission, the patient, while stooping down, struck his right frontal areas but was not - unconscious. A right periorbital ecchymoses developed, and the patient also had the onset of bilateral frontal headaches.

General physical examination: Temperature was elevated to 101°. There was right periorbital edema. Excoriation of right nasal mucosa was present.

Neurological examination:

1. *Mental status:* The patient was alert but irritable and slightly confused. He was poorly attentive and failed to persist in carrying out motor activities. He was oriented grossly for time, place and person. Calculations were poorly performed. Delayed recall was defective.
2. *Cranial Nerves:* All were intact with the exception of the fundi. Low-grade papilledema was present and venous pulsations were absent.
3. *Motor System:* Strength was intact, but there was a slight drift downward of the outstretched left arm.
4. *Reflexes:* Deep tendon reflexes were somewhat brisker at left arm and leg (3+) as compared to the right (2+). Plantar responses were flexor. A bilateral grasp reflex was present.
5. *Sensory system:* Intact
6. *Skull & Neck:* There were slight tenderness over the right periorbital area. Minimal nuchal rigidity (resistance to passive flexion of the neck) was present.

Clinical diagnosis: Right frontal subdural empyema or brain abscess.

Laboratory data:

1. The *WBC* was increased to 14,350 cells per cubic mm., and the sedimentation rate was increased to 110 mm. in one hour.
2. *Sinus X-rays:* Bilateral maxillary and frontal sinusitis was present with resorption of bone.
3. *Electroencephalogram:* Focal 4 to 7 cps slows wave activity was present in the right parietal area suggesting focal damage. Moreover, focal voltage suppression (reduction of voltage) was present in the right anterior frontal area suggesting a possible subdural collection.
4. *Right carotid arteriogram* showed an apparent slight shift of the anterior cerebral vessels to the left suggesting a right hemisphere space-occupying lesion.

Hospital Course: Following these studies a right frontal trephine (burr) hole was placed by Dr. Robert Yuan. When the dura was incised, 5 cc. of yellow purulent material escaped from the subdural space and additional purulent drainage was aspirated. Additional burr holes were placed in the right occipital area where a few drops of subdural pus were encountered. No pus was obtained from the left subdural area. Subsequent cultures demonstrated *Staphylococcus aureus* as the responsible organism. The dura and cortex otherwise appeared unremarkable although cerebral edema was present. The patient was subsequently treated with appropriate antibiotics. His temperature gradually subsided to normal and his mental

status cleared. Three weeks later, a bilateral frontal sinusotomy was performed by Dr. Thomas Klein with drainage of the sinus. Histological examination of a section of sinus mucosa removed demonstrated intense chronic inflammation. The patient continued to improve. When seen in followup examination four months after admission, papilledema had subsided, no neurological findings were present except for a slight reflex asymmetry (slightly increased on the left).

Comment: This patient presented a definite history of chronic nasal sinus infection with a recent exacerbation. The role of trauma in the exacerbation is uncertain. It is clear, however, that the sinusitis had produced involvement of the adjacent bone with subsequent spread to the adjacent frontal subdural space. The severe headache experienced by the patient reflected not only the process of infection involving the sinus and meninges but presumably also the increase in intracranial pressure. The early involvement of the right frontal area was suggested by the initial symptoms of confusion and by the occurrence of focal seizures characterized by turning of the head and eyes to the left. The findings of the electroencephalogram suggested a subdural collection of fluid or pus in the right frontal area.

These clinical and laboratory impressions were confirmed by the subsequent surgical observations. In the present case the arteriogram suggested only a non-specific space-occupying lesion in the right frontal area. The more specific finding in these cases would involve the displacement of distal branches of the anterior and middle cerebral artery from the inner table of the skull as in a subdural hematoma. Today the CT scan or the MRI/MRA is the study of choice for confirming the diagnosis of a subdural collection. Additional review of subdural empyemas will be found in Miller et al 1987. In the pre-antibiotic era, infections involving the nasal sinuses could produce thrombophlebitis of the cortical veins and superior sagittal sinus. With that complication, infarction of that area of motor cortex representing the leg could occur resulting in unilateral or bilateral leg weakness as well as focal motor seizures. Infection of the nose or face or of the ethmoid or sphenoid sinuses could produce thrombophlebitis of the cavernous sinus resulting in the syndrome discussed in the cranial nerve chapter: unilateral or bilateral involvement of the cranial nerves found in the lateral wall of the cavernous sinus (III, IV, VI and the ophthalmic division of V). The ophthalmic vein may be obstructed producing edema of the eyelid and face. Obstruction of the retinal vein produces papilledema. Infection of the middle ear or mastoid may produce involvement of the transverse or lateral sinus. If this extends to the jugular vein, increased intracranial pressure may also occur. However increased intracranial pressure may follow any involvement of the other venous sinuses. At the present time, dural venous sinus thrombosis is usually more indicative of dehydration and other systemic conditions in the infant and in the adult of immunological disorders or of conditions that produce a state of hypercoagulation such as polycythemia, carcinoma, pregnancy or birth control drugs. (refer to Daif et al, 1995 and DeVeber et al, 2001)

CHAPTER 30 MEMORY

A case of Wernicke-Korsakoff syndrome is presented in case 30-1.

Case 30-1. Patient of Doctor John Sullivan and Doctor John Hills): This 62-year-old, white, right-handed stonecutter had been a known heavy alcoholic spree drinker for many years. The patient would drink large quantities of wine for 6 to 8 weeks at a time. Two years previously, the patient had been admitted to the Boston City Hospital because of delirium tremens (tremor and visual hallucinations). Two months prior to admission shortly following the death of a brother-in-law, the patient began his most recent drinking spree. He unaccountably found himself in Florida, not knowing where he was and

why he was there. Apparently, he had drifted aimlessly for 5 weeks with no definite food intake for a month. The patient was brought back by his family and hospitalized at his local community hospital with diplopia, ataxia and marked impairment of memory. The patient had complaints of numbness of his fingertips and unsteadiness of gait. The patient after beginning treatment was shortly thereafter referred to the Neurology Service at the New England Medical Center.

General physical examination: No abnormalities were present except for an enlarged liver with the edge palpated approximately 2-1/2 finger breadths below the costal margin.

Neurological examination:

1. Mental status:

- a. The patient was markedly disoriented for time and place. At times, the patient thought that he was in New Jersey; at other times, he stated correctly that he was in Boston.
- b. The patient, with suggestion, would recall his apparent travels that day to various other locations within and outside Boston (he was actually in the hospital). Confabulation was also evident when it was suggested that he had recently seen various fictitious persons.
- c. Remote memory; The patient was unable to state his age. The patient was able to provide his birth date correctly. He could not give his address or telephone number. When quizzed as to the President of the United States, he selected on multiple choices the previous president. At times, the patient often indicated to visitors that his mother and father were still alive, though both parents had been dead for over 20 years.
- d. Insight; He appeared to have little insight for his disorientation in time. He had no insight as to his condition or for the reason for his hospitalization.
- e. The patient's digit span was normal at 7 forward and 6 in reverse.
- f. The patient could name various objects correctly when these were presented to him and yet he was unable to retain any memory of which objects had been presented to him five minutes previously. He was unable to retain any information concerning a story that he had been requested to learn.
- g. The patient was able to do 2 and 3 figure additions and multiplications without difficulty. He was able to do the initial subtractions in the serial 7 test but then lost track of the number to be subtracted.
- h. The patient was able to read and to write without difficulty. He showed no constructional apraxia and no left-right confusion.

2. *Cranial nerves:* There was horizontal diplopia on right lateral gaze. The minor degree of separation of images, however, did not allow precise identification of the muscle involved. A minor weakness of the right lateral rectus was suspected.⁶ Horizontal nystagmus was present on lateral gaze, bilaterally and vertical nystagmus on vertical gaze.

3. *Motor system:* Strength was intact except for a minor degree of weakness in the distal portions of the lower extremities evident on ankle dorsiflexion and toe dorsiflexion.

The patient walked on a narrow base with eyes open and showed no evidence of an ataxia of gait. On a narrow base with eyes closed, the patient had a positive Romberg test.

No cerebellar findings were present.

4. *Reflexes:* Deep tendon reflexes were normal at triceps and biceps, decreased at radial periosteal. And absent at patellar and Achilles even with reinforcement.

⁶ The minor nature of the diplopia undoubtedly reflected the improved nutritional status that had occurred during the previous 5 days of hospitalization at his community hospital. We presume that if the patient had been examined prior to hospitalization, more marked lateral rectus palsy probably would have been delineated.

Plantar responses were flexor bilaterally.

No grasp reflex was present.

5. Sensory System: Pain and touch were decreased in the lower extremities below the mid calf. Vibratory sensation was absent at the toes and decreased over the tibia to a marked degree and to a lesser degree over the knees. There was to a lesser extent, a decrease in the upper extremities at the fingertips and wrists.

Position sense was decreased at fingers and toes.

Clinical diagnosis: Wernicke' encephalopathy plus nutritional poly neuropathy

Laboratory data: Complete blood count, liver functions and renal functions, CSF, EEG, and X-rays of the skull and chest were all normal.

Subsequent course: The patient was treated with thiamine, 50 MGS daily. There was a significant improvement in extraocular functions. The patient had no diplopia after the day of admission. There was no significant change in his mental condition or peripheral neuropathy. Evaluation 3 months later, indicated persistent disorientation for time and place and severe selective deficits in memory (delayed recall was still grossly defective).

Comment: This patient presents a relatively typical history of the Wernicke-Korsakoff syndrome. He had been a heavy alcoholic spree drinker. The major symptomatology that was apparent to the patient's family and to his physician, related to his marked confusion, severe impairment of memory and confabulation. The patient himself had no significant complaints and little insight into his disease. In some cases, the severe memory disturbances may be present without any definite evidence of confabulation. Not only the retentive memory for new material was impaired but also the patient's distant memory was also significantly impaired. In such cases with severe impairment of memory the prognosis for a complete recovery of mental status is very poor. The diplopia and nystagmus, as expected, resolved significantly with treatment with thiamine. The ataxia of gait, which had been present early in the case, had apparently resolved by the time of transfer from his local hospital. A significant peripheral neuropathy, mainly distal sensory, was present related to multiple B vitamin nutritional deficiency.

In many cases, the state of confusion in Wernicke's encephalopathy is preceded by or accompanied by a period of delirium tremens indicating alcohol withdrawal. The use of intravenous glucose feedings without supplemental intravenous thiamine during such a withdrawal state may actually increase the requirements for thiamine, thus exacerbating the thiamine deficiency state. For this reason, all patients under treatment for alcohol withdrawal (or admitted to the hospital with a recent past history of alcoholism) should be treated with high dosage vitamin therapy as well, on the presumption that they are candidates for nutritional deficiency.

A case of transient global amnesia is presented in case 30-2 below.

Case 30-2: This 55-year-old, right-handed, white male, college professor, awoke at 3:00 a.m. on the morning of admission in an uneasy and restless state. He asked his wife what day it was but then did not recall what she had told him. He did not know the month, kept repeating himself and asking the same questions. His wife arranged for him to be seen early in the morning by his family physician who lived a short distance away. The patient, who was familiar with the route, was unable to find his way there. When he arrived at the doctor's office, he was unable to explain why he had come. The patient apparently had forgotten about the incidents, which had occurred earlier that morning. He had no recollection that he had a grandchild born three weeks before. He could remember no significant events from this 3-week period prior to the onset of his illness. The patient's more remote recall and other intellectual capacities remained intact. The patient drove into Boston later that day but became lost despite the usually familiar route.

The patient had a past history of gout with an elevated serum uric acid level.

Neurological examination: Findings were essentially limited to the mental status examination.

When examined in the early afternoon, the patient was beginning to regain some of his ability to retain new information. The patient was generally oriented to person and place. However, he was disoriented for the day and month but was oriented for the year. The patient's store of information was quite intact suggesting a highly intelligent person.

The patient had marked difficulty with delayed recall. He could recall none of the 4 objects after 5 minutes. He could not remember any of the three test phrases given to him when asked about these 5

minutes later. He did recall in a vague manner that a memory test had been given him. As regards recent memory, the patient was unable to remember his visit to his family physician earlier in the day. Digit retention, however, was relatively well preserved; 6 forward and 5 backward. The patient had no defects in calculation. There was no evidence of a constructional apraxia. Language function was entirely intact.

Clinical diagnosis: Probable transient global amnesia

Laboratory data:

1. Complete blood count, serology, blood urea nitrogen, total cholesterol, uric acid skull and chest X-rays, EEG and complete CSF were all within normal limits.
2. The *brain scan* demonstrated a small area of increased uptake of radioisotope (Hg197) in the left temporal region.

Subsequent course: Over the several hours following admission, the patient gradually regained his ability to retain new information and to recall the events of the preceding 3 weeks, the more remote events being recalled first. The memory for the events of the day prior to admission was regained last. This pattern is referred to as a shrinking retrograde amnesia. The specific events that occurred on the morning of admission were never recalled. The following morning delayed recall was four-out-of-four objects after 8 minutes. The patient's mental status and neurological examination were otherwise within normal limits. A repeat brain scan, 3 months after the episode demonstrated considerable improvement, and all brain scan findings had resolved at 5 months. No additional episodes occurred during the one-year after the acute episode.

Comment: The patient's main deficit was in learning new information (anterograde amnesia) with the old stored long-term memory information still intact. During the episode there was a retrograde amnesia that initially extended back for three weeks. As recovery occurred, this retrograde amnesia disappeared. These relatively recent past memories were intact but transiently not accessible. The labile stage of long-term memory has been estimated to be a matter of 20-180 minutes. This case suggests that there is not a sharp border between the labile more recent stage and the remote stage of long-term memory or perhaps of the ability to access those memories. The patient could not remember what happened during the episode. That is suggestive of mesial temporal lobe involvement, in this case left hippocampal region in dominant hemisphere. The ability to perform calculations and language functions was otherwise intact. This would suggest that lateral temporal areas were not involved. The electroencephalogram was normal and consistent with such a lack of involvement of the lateral aspects of the cerebral hemispheres. Occasionally, the EEG will demonstrate a minor focal involvement of the temporal lobe. More often, as in this case, the study is normal. CT scan and MRI when performed are usually unremarkable. SPECT scan might well indicate transient focal involvement as indicated above. The brain scan in this case did suggest a transient abnormality, which would be consistent with an area of ischemia/ infarction, which resolved over the succeeding months. Such an episode must be distinguished from episodes of amnesia, which may occur in relation to, and following a temporal lobe seizure.

The effects produced by electrical stimulation of the hippocampus may also occur as relatively selective ictal and postictal phenomena in a complex partial seizure originating in mesial temporal lobe structures as illustrated in case history 30-3 which follows. Focal temporal lobe seizure phenomena were followed by a period of impaired recent memory with an inability to record new memories.

Case 30-3: This 68-year-old, white male one year prior to valuation fell, striking his occiput and transiently losing consciousness. Except for a persistent defect in his sense of smell, the patient had no apparent neurological defects following this injury. Approximately six months later, the patient had the first of a series of recurrent episodes of amnesia. These episodes occurred most often on awakening. On some, but not all, occasions the episodes were preceded by a sensation of gastric upset, a strange odor and a sensation of familiarity (*déjà vu*). The episodes of total amnesia would last 30 to 60

minutes. There would then be an impairment of memory for approximately one to two days. The patient was said during the episode of total amnesia and during the subsequent episode, to behave in an otherwise normal and rational manner. For example, he would be able to converse with his wife and others. During the episodes, he was said to be unable to remember tasks, which his wife had asked him to do during that day. A significant impairment of retentive memory would be apparent to his wife and to others. His memory for more distant and remote events was also impaired to a variable but lesser degree. The patient would then regain memory progressively over the course of the next one to two days. Apparently, memory was not regained in any orderly pattern from recent to remote or vice versa. The patient at no time had any abnormal movements suggestive of a generalized convulsion.

No automatisms had been noted and to others the patient would appear fully conscious during the episodes.

Neurological examination:

1. *Mental Status*: The patient was oriented for time, place, and person. Delayed recall was intact. The patient could remember 4-out-of-5 objects in 5 minutes. Remote memory was intact. Digit span was slightly impaired at 6 numbers forward and 4 in reverse.

2. *Cranial Nerves*: All areas were intact with the exception of cranial nerve I where olfaction was decreased for the odor of coffee grounds, bilaterally.

3. *Motor system, reflexes and sensory system*: *Intact*.

Clinical diagnosis: 1) Complex partial seizures (most likely post traumatic) with episodes of amnesia as an ictal and or post ictal phenomena. 2) Post traumatic anosmia.

Laboratory data: 1. *Skull X-rays, routine EEG, radioactive brain scan, fasting blood sugar and glucose tolerance tests, pneumoencephalogram and spinal fluid examination were normal..*

2. *The EEG obtained after a period of sleep deprivation revealed occasional multifocal spikes during sleep in the right anterior temporal area and to a lesser degree the left frontal-anterior temporal area.*

Subsequent course: The patient was treated with anticonvulsant medication. The episodes continued to occur once per month but were now of shorter duration, lasting only 15 to 20 minutes. The impairment of memory was less marked and involved only the ability to learn new material without prolonged periods of retrograde amnesia. After 8 months no additional episodes occurred. When seen three years after initial evaluation his neurological examination was unremarkable except for the defect in olfaction suggesting that more serious progressive disorder was not present.

Comment: In this case the episodes experienced by the patient could have posed a diagnostic problem if the occasional warning symptoms of olfactory aura, déjà vu and epigastric sensation had not been present. Most of the episodes experienced by the patient were not preceded by these clear symptoms of temporal lobe seizure, but were instead simply episodes of amnesia. Though the actual temporal lobe seizures apparently lasted only a matter of 30 to 60 minutes, some degree of impairment of memory was present for one to two days following the episode.

The etiology of the seizures in this case must relate to the patient's preceding head trauma. The loss of olfactory sensation following the trauma suggested that this trauma was of sufficient nature to tear the nerve filaments passing through the cribriform plate to the olfactory bulb on the orbital surface of the frontal lobe. Such trauma does produce contusions of the orbital frontal cortex and epileptogenic foci may result. We may also assume that this trauma may have been sufficient to produce some minor contusion of the anterior poles, inferior and medial surfaces of the temporal lobes against the bony walls of the middle fossa with a resultant scar and epileptogenic focus. The fact that olfactory hallucinations and the experience of déjà vu preceded some of the amnesic episodes

would make the temporal origin more likely. The routine electroencephalogram is not reliable in the detection of seizure discharges in either the mesial temporal or the orbital frontal areas. The electroencephalogram showed significant areas of discharge in the temporal lobe only under conditions of sleep deprivation which acts to precipitate seizure discharges in individuals who have an underlying predisposition for seizure discharges. For additional discussion, see Gallassie, et al (1988), Hughlings-Jackson (1889), Tassinari, et al (1991).

The following case history presents an example of presenile dementia.

Case 30-4: This 64 year old right handed white male formerly an administrative assistant for the veteran's administration and newspaper distributor was initially evaluated for impairment of recent memory. Initially, the wife indicated this had been progressive over 4 years, but she was subsequently able to date this back to age 54 years, 10 years previously. A review of his record indicated that another neurologist of our department had seen him 4 years previously with similar memory complaints. The neurological examination at that time demonstrated no focal features, but his mental status examination indicated an inability to recall any of four objects. There were minor changes in time orientation: his date was off by one month and the day of the week was incorrectly stated. In the interim, the memory problems had progressed. In addition there were now personality changes. He no longer participated in those activities which had previously been of great interest. He was also having some problems in finding words. There were no problems in the activities of daily living and he was not getting lost in his familiar environments.

Family history: There was no history of neurological disease in his siblings or father. His mother had died at the relatively young age of 48 of cancer.

Neurological examination:

1. *Mental status:* The mini mental status exam indicated a total score of 19 out of 30. He had particular problems in time orientation. He was able to do the immediate recitation of three objects and of a test phrase but could remember none of these on a delayed recall test. He also had difficulty copying a test figure. The patient was often tangential in his answers and demonstrated inappropriate joking.

2. *Cranial nerves:* intact

3. *Motor system* was intact as regards strength, gait and cerebellar functions. However premotor /frontal lobe functions were abnormal. He had a release of the instinctive grasp reflex. He had difficulties performing the Luria three stage motor sequences demonstrated by the examiner (slap thigh with palmar surface, then with ulnar edge of hand and then with ulnar surface of closed fist.).

4. *Reflexes:* deep tendon stretch reflexes, and plantar responses were physiologic.

5. *Sensory system:* intact

Clinical diagnosis: Alzheimer's disease

Laboratory data:

1. All screening studies such as *complete blood count, sedimentation rate, B -12, folate, thyroid functions and serological test for syphilis* were normal.

2. *CT scan* demonstrated significant dilatation of the temporal horns. (This change in the size of the temporal horns suggested hippocampal atrophy.) In addition there was a general increase in lateral ventricular size. There was also blunting of the angles of the frontal horns.

3. *SPECT scan* was within normal limits except for a slight decrease in perfusion in the left parietal region.

Subsequent course: The patient was begun on treatment with 5mg per day of donepezil (Aricept) a centrally acting acetylcholinesterase inhibitor and high dosage of vitamin E (a possible antioxidant). . When re-evaluated at one month, his family reported improvement in memory; the mini mental status exam score was now 21 out of 30. At 10 weeks into treatment, the score had increased to 25 out of 30. There was particular improvement in the delayed recall section of the exam. There was however no change in personality. He still showed inappropriate jocularity when he could not answer a question and at times was tangential in his answers. Administration of the acetylcholinesterase inhibitor temporarily improved memory function for approximately 18 months. However by age 67, behavioral disturbance (agitation, aggression nocturnal wandering and sexual disinhibition) and urinary incontinence were becoming major problems. He could no longer be managed in his home and day care setting despite the

use of haloperidol. This resulted in his placement in a nursing home. At age 69, he was now described as relatively nonfluent, and very confused. He recognized his own name and occasionally recognized relatives but showed no other response to questions. He was usually restricted to a wheel chair, could walk with assistance. He was “stiff and afraid” when requested to walk.

Comment: This patient presents a typical example of the slowly progressive course of Alzheimer’s disease. Memory problems had begun insidiously at approximately age 54. Initially these problems in the older adult may be attributed to a benign age related process in which there is minor difficulty in accessing information such as names although the ability to incorporate new information is still intact (“wait a minute, the name or word will come to me eventually”). When evaluated by a neurologist at age 60, the major finding was a severe deficit in delayed recall suggesting a process at the level of the hippocampus. The patient failed to return for follow up at that time and when he did reappear at age 64, he was now beginning to show changes in personality and frontal release signs suggesting involvement of the prefrontal and premotor areas. The use of a cholinesterase inhibitor produced some improvement in memory for about 18 months but had little effect on the changes in personality and behavior. The use of this agent has been estimated to postpone nursing home placement by approximately 15 months. Eventually by age 69, fifteen years after disease onset, gait and other motor functions were seriously affected.

The rationale for the use of cholinesterase inhibitors is based on the demonstration by Drachman and Leavitt (1974) that administration of scopolamine, an anticholinergic drug that crosses the blood brain barrier, would produce a transient syndrome similar in many respects to memory and cognitive changes of Alzheimer’s disease. Subsequent studies demonstrated a marked loss of neurons in the basal forebrain nucleus of Meynert, a major source of cholinergic fibers to the cerebral cortex. (Whitehouse et al 1981 Rogers et al, 1985 editorial of Growden 1992). However, a simplistic cholinergic hypothesis is insufficient to explain all of the features of Alzheimer’s disease. Administration of acetylcholine esterase inhibitors in mild cases (mini mental status score of 10-25) has only a limited value as in the present case. Other neuronal systems are involved (noradrenergic synapses are also involved. hippocampal system is severely involved).

The following case 30-5 provides an example of general paresis producing severe changes in cognitive function and personality.

Case 30-5 : This 59-year-old right-handed white male, cleaning establishment owner, five years prior to evaluation, manifested a personality change - increased rigidity and irritability. He would become enraged over trivial matters many times per day. During the last 1.5 years, this process accelerated. He became more antisocial, unable to interact with employees and customers. His level of comprehension declined. He became more aggressive towards his wife and children. He often manifested frank paranoia and suspiciousness, accusing his wife of unreal, sexual infidelity. During the last 1.5 years, a significant gait disturbance had also developed, with impairment of balance. A slowing in speech and a tremor of hands had developed over the previous year.

The patient had been born in Poland. All significant infections were denied. He had received injections of “liver” and B12 after the war “for anemia” but had received no recent B12 injections.

Neurological examination:

1. *Mental status:* The patient was oriented for time, place and person.

Delayed recall was markedly impaired none of five in five minutes without assistance, one of five with assistance. Repetitions and naming of objects were intact. Distant (remote) memory was good. The patient could list all major world leaders during World War II and all assassination attempts.

The patient was often tangential in his responses and often initiated irrelevant conversations.

Serial 7 subtractions could not be done but the patient could reverse 12 months of the year.

Abstract reasoning for similarities was poor.

He often got up from the bed and looked outside the curtain, checking the activities of his roommate.

2. *Cranial nerves:* Pupils were small, 2 mm., and irregular but did respond to light.

Twitching and grimacing of face, eyelids and tongue occurred. He also had a lid lag.

3. *Motor system*: Strength was intact. Gait was wide-based, with a positive Romberg test. The patient was quite tremulous with occasional myoclonic jerks. He could not do rapid alternating movements.

4. *Reflexes*: Deep tendon reflexes were normal (2+) in the upper extremities, trace at patellar and absent at Achilles. Plantar responses were flexor, bilaterally. There was no release of the grasp reflex. Other frontal release signs were absent.

5. *Sensory system*: Pain, touch and position sense intact. Vibration was markedly decreased at toes, and ankle with minor preservation at knees.

Clinical diagnosis: Progressive dementia and personality change. Multiple entities to be considered including (1) the combination general paresis and tabes dorsalis, (2) B12 deficiency, (3) frontal lobe tumor, (4) frontal dementia and (5) Lewy body dementia

Laboratory data: The abnormal findings included:

1. *Vitamin B12 level* was borderline low at 209 picograms/ml., *Schilling test*, however, demonstrated normal absorption (25.4% excretion of radioactive B12 in urine).

2. Serum serological test for syphilis (RPR) was reactive with the more specific FTA markedly reactive.

3. *Cerebrospinal fluid*: 98 white cells were present - all lymphocytes. CSF protein was elevated to 116 mgs.% (normal <45 mgs.%). Sugar was low at 44 mgs.% with a simultaneous blood sugar of 90. Spinal fluid serological test for syphilis (VDRL) was positive.

4. *CT scan* showed mild frontal and temporal atrophy

Subsequent course: The patient was hospitalized for two weeks and received high dosage intravenous penicillin therapy, three million units every four hours for 10 days (18 million units per day).

When seen again 2 months later, the patient and his family reported that gait and coordination had significantly improved. Memory and personality had not improved. He still had episodes of agitation and irritability. Reflex and sensory findings were unchanged. The patient had been inconsistent in taking any medication such as haloperidol, aimed at altering his agitation.

He failed to return again for 18 months. Paranoid ideation had become more prominent. He could no longer manage his fiscal affairs. Orientation and delayed recall were intact. There was minor tremor of the hands and an unsteadiness of gait. Romberg was positive although position and vibratory sensation were intact. Serum serology was now negative. Lumbar puncture now indicated no significant cells, a normal protein.

Subsequently he did require hospitalization for renal failure secondary to enlarged prostate and a neurogenic bladder. Spinal fluid VDRL and serum RPR serological tests for syphilis, were both nonreactive. Serum FTA ABS - a much more specific and more sensitive test for previous syphilis was still 3+ reactive.

Telephone follow-up 11 years after the initial episode indicated that personality and cognitive changes had essentially leveled off, irritability and hostility were less. He had no urinary problems. He was unsteady in walking, but was still able to drive small distances and was living at home. Additional information approximately 20 years after the initial evaluation indicated that he spoke very little, he no longer demonstrated agitation. His mobility was more limited. Of interest, one pupil no longer responded to light but did respond to accommodation. CT scan demonstrated greater atrophy.

Comment: This patient had clinical manifestations predominantly related to general paresis. Both the history and the examination also provided evidence of tabes dorsalis. Penicillin therapy resulted in a non-active state, as regards serum serology and any cellular activity in the spinal fluid. However, the damage to cerebral cortex was not reversed and continued to provide a significant problem, as regards personality function. Thus, once cognitive function has been altered, due to damage to and loss of neurons, the changes in memory and personality may be persistent. Disturbances of frontal lobe and limbic system function once initiated may continue to evolve.

Moreover once the patient reaches the late 60's and the 70's, apparent progression of neurological changes in memory and other cognitive functions may occur related to the combined effects of the previous acquired lesions of general paresis and the effects of even mild Alzheimer's disease. A double hit has occurred.

The following case provides an example of a patient whose initial symptoms related primarily to a severe alteration in personality function and social interactions. Features of Parkinson's disease were apparent on her examination. Diagnosis was uncertain but diffuse Lewy body dementia should be considered.

Case 30-6: This 60-year old, right handed separated white housewife, residing in a nursing home, was referred for evaluation of problems in walking, progressive behavioral change and memory disturbance. Six years previously at age 54, a change in behavior was first noted by her family. She began to accumulate papers about the house. She would leave the shades down all day, and expressed fears that people would break into her house. As a result, she became isolated from her neighbors and friends. Shortly there after, she made repeated phone calls to the local police and it was apparent that she was confused. After investigation, the police had to break into the house and take her to an emergency room. In the emergency room she was described as confused and frightened. Paranoid ideation was prominent with considerable self-referral ideation. Thought process was described as tangential, with considerable perseveration. There was poor insight and judgment was impaired. She was confused as to time and place and she could recall two of three objects in 5 minutes. She had great difficulty with serial sevens, often losing track of the number to be subtracted. Judgment and insight were poor. She would read a book by rapidly turning the pages, but then had little recall of what she had read. With treatment with haloperidol, lability of mood and paranoia decreased. A CT Scan demonstrated "mild cortical atrophy". The patient was then transferred to a nursing home with a diagnosis of Alzheimer's Disease. In retrospect, a gait problem had also been present in January 1984, about the time that her symptoms had begun, and prior to the use of haloperidol.. The patient was walking flexed with small steps. These gait problems progressed so that she was unable to stand up from a chair and was unable to walk. She had become fearful of walking.

Family History - Indicated parents died at ages 70-80 years, without neurological disease. A sibling was age 79 without neurological disease.

Neurological examination:

1.*General:* A thin female appearing older than her stated age. She sat in a wheelchair with little facial expression and with little body movement. She was passive in the interview situation -allowing her husband to provide many answers.

2.*Mental Status:* She was oriented to the year but when requested to provide the month and day, she answered "it is the beginning of school time". As regards the location, she gave the name of the town where she formerly lived but could not name the town where the nursing home was located. She did name the nursing home and then said "its a jazzy place with more facilities, most of the people there are nice, some just sit around".

Asked to describe herself, she said, "I am nothing, I can't even take care of my child". She was, however, able to provide the name of her only daughter, now grown, and was able to indicate that the daughter had been born in 1945 in Philadelphia (all of which the husband verified as correct).

Asked to indicate her own birthplace and birth date, she indicated she herself had been born at home in Fitchburg in 1925 and then added, "I imagine everything has been tossed out there". When I asked "what had been tossed out?", she provided a tangential answer, "I do not know you" and then rambled on to a conversation topic about her husband's trip to Turkey on a "Fulbright" - some time in 1960 or 1970.

Delayed recall even with multiple choice assistance was zero out of five in five minutes. For serial seven subtractions, 100 - 7 "might equal 86 or might equal 55". She could name 3 out of 5 objects, could do repetitions, could write her name but not her address and refused to draw a house (? unwilling, ? unable).

3. *Cranial Nerves:* Intact except for a tremor of the closed eyelids and a positive glabellar sign. There was a lack of facial expression.

4. *Motor System*: Strength was difficult to assess, but appeared intact when maximal effort was made. Significant akinesia and bradykinesia were present. There was cogwheel rigidity of minor degree at wrist and elbow. There was variable resistance at hip and knee, which had primarily the character of frontal lobe type "Gegenhalten".
The patient had to be assisted to the standing position from her wheelchair. In the standing position, initially, her feet appeared to be stuck to the floor, as in a magnetic foot syndrome. Eventually, she was able to take small shuffling steps, as assistance was provided by holding her outstretched hands lightly. If unsupported, she tended to fall backwards - whether standing or walking.
 5. *Reflexes*: Deep tendon reflexes were physiologic at 2+ except for Achilles - 1+. Plantar responses were equivocal. There was marked release of the grasp reflex.
 5. *Sensory system*: Pain and vibration were intact. Position sense could not be tested.
- Clinical diagnosis:** Lewy body dementia , or a variant of frontal dementia.

Laboratory data:

1. *Metabolic surveys* were not remarkable in terms of electrolytes, BUN, creatinine, glucose, hepatic functions, vitamin B12, folate levels and thyroid functions.
2. Routine serum serological test and FTA absorption for syphilis were negative.
3. *Sedimentation rate* was moderately increased to 53 mm/hr. *Alkaline phosphatase* was elevated to 272 and bone scan suggested possible Paget's Disease.
4. *EEG* demonstrated a slow dominant awake activity of 6-7 Hz (compared to normal alpha rhythm of 8-13 Hz). In addition, rhythmic bilateral delta slow wave were present, most prominent in the frontal recording areas.
5. *CT Scan*, demonstrated marked cortical atrophy with enlargement of sulci, ventricular system and cisternal spaces.

Subsequent course:

The patient continue a slowly progressive course to the present time. According to her primary physician, she is essentially restricted to bed. She remains, from a medical standpoint, relatively clear of other medical problems and complications - at age 67, 13 years after onset of the disease.

Comment: The diagnosis in this case is uncertain . The patient at age 54 had the onset of a significant change in behavior which resulted in major problems in interpersonal relationships. Initially, she had been able to live by herself in her small seaside community. Eventually, however, the frequent night calls to friend, neighbors, and the police, resulted in her coming to medical attention. Even at that point, the patient's separated husband, who visited her frequently and supported her, appeared unaware of the patient's confusion and memory deficit. The husband had considerable difficulty appreciating the degree of disability. Such a pattern is not unusual.

In contrast to the previous case histories of this chapter, the memory problems were far beyond the selective involvement of recent memory seen in Wernicke's or hippocampal lesions. Moreover, a more diffuse involvement of other cognitive functions was present. As the disease progresses, motor aspects become prominent, indicating the effects of involvement of frontal and premotor areas. Mild "Parkinsonian" features may appear, due to either the medications employed (neuroleptic agents such as pheno thiazides, haloperidol, etc.) or to alterations in the frontal premotor basal, nuclei circuits or to loss of neurons, at the level of S. nigra or basal nuclei. Note however that the gait problems occurred prior to the use of haloperidol. The CT scan did not demonstrate the focal atrophy seen in frontotemporal dementia .Therefore the most likely diagnosis might be diffuse Lewy body dementia since personality changes were most prominent at onset, and Parkinsonian features developed early in the disease course. Contrast this case to the Alzheimer disease patient of case 30-4 in which the initial problems were restricted to changes in memory.

When seen at age 60 this patient was clearly late in her disease course. As indicated, remedial causes of the syndrome of progressive dementia must be ruled out. The effects of medication must be considered. Moreover, however, any masking depression should be treated. At this point in time, no specific therapy to reverse the progressive course of the disease is known.

Case 30-7: This 74-year-old right-handed widow presented to the emergency room at St Vincent hospital on 2-19-02 with an 8-10 week history of worsening memory problems. In December 2001, accompanied by her boyfriend she made her annual trip to Florida. Although she had been in her usual state of independent living prior to her departure, she was found to have serious problems with

memory on arrival. She was unaware as to where she was. In a telephone conversation with her daughter, “she was talking nonsense”. During the next 2 months, memory and word finding continued to deteriorate. She was taken to the emergency room of the local hospital in Florida where a CT scan without contrast on 02/07/02 demonstrated mild cortical atrophy but no acute process. Her son drove to Florida and found that her memory was poor and her conversation did not make sense. “My husband is in the service: my mother died last year.” However she could play cards with her grand daughter. Her gait was slow and stooped. She had urinary incontinence on her way to the bathroom.

She had no history of alcoholism and took various vitamins and herbs.

Family history: her brother had died of a brain tumor of unknown type.

Neurologic examination: The positive findings were the following:

1. *Mental status:* The patient was awake and alert. Overall Mini-Mental Status Score was 19/30. The major problems were in orientation and in delayed recall. She was able to indicate that she was in a hospital in Massachusetts. And the date was February. She registered 3 objects but could recall any in 3 minutes. She was however able to read, name objects, follow instructions, spell “world” backwards and copy a figure. She was unable to draw a clock with the hands set at 11:10.

2. *Cranial nerves:* intact

3. *Motor system:* Although strength and tone were normal, her gait was broad-based and shuffling.

4. *Reflexes:* Patellar and Achilles reflexes were absent but plantar responses were flexor.

5. *Sensory system:* Intact.

Clinical diagnosis: 1) Subacute dementia: etiology uncertain possibly of Alzheimer’s or Lewy body type. Various entities such as chronic subdurals, tumor etc to be ruled out 2) Peripheral neuropathy, most likely etiology at this age diabetes mellitus.

Laboratory data:

1. *Basic CBC and chemistries:* Normal except for an elevated fasting glucose.

2. *CT scan (Fig 30-10):* An enhancing 2.75 cm tumor with a necrotic center was present in the thalamus at the level of the upper third ventricle. There was bilateral involvement of the anterior and medial thalamus but with no involvement of the posterior thalamus or hypothalamus. The study suggested a lymphoma or glioblastoma

Subsequent course *Stereotaxic biopsy of the right thalamus:* Frozen section raised the question of a lymphoma or glioblastoma but special immunological stains were consistent with a glioblastoma. Necrosis and endothelial hyperplasia were present. The patient was treated with dexamethasone and radiotherapy with improvement in gait.

Comment: This patient presents an unusual cause of a progressive alteration in memory. As indicated earlier in this chapter those patients with Wernicke’s encephalopathy who progress to the Korsakoff syndrome had persistent pathology in the medial and anterior thalamus with sparing of the posterior thalamus. In this case the pathology was a rapidly progressive glioblastoma multiforme. As discussed above, an occasional patients, glioblastomas may also produce dementia and a change in personality by infiltrating the prefrontal areas and corpus callosum. Occasionally a patient with a more diffuse neoplasm gliomatosis cerebri may also present with a similar syndrome of dementia which may mimic Alzheimer’s disease. These are however rare causes compared to the more frequent degenerative disorders.

COMPLETE CASE HISTORIES FROM TEXTBOOK: *INTEGRATED NEUROSCIENCES*
PART IV. CASES; CEREBRUM VISION, DISEASES, MEMORY

CHAPTER 23: VISUAL SYSTEM

The following case is an example of a lesion involving the optic nerve, anterior to the optic chiasm.

Case History 23-1 (Fig 23-8).

This 53-year-old white right-handed housewife was referred for evaluation of progressive right-sided supraorbital headache of 23 years duration and decreasing acuity in the right eye. The loss of acuity had progressed to the point of almost total unilateral blindness. During the 3 years before admission, intermittent tingling paresthesia had been noted in the left face, arm, or leg. About 1 year before admission the patient had a sudden loss of consciousness and was amnesic for the events of the next 48 hours. She was hospitalized, but no explanation for the episode was clearly established, although cerebrospinal fluid protein was reported to be elevated (230 mg/dl).

The patient and her family reported some personality changes over a period of several years, including a loss of spontaneity and increasing apathy.

General Physical Examination: Unremarkable except for a minor degree of proptosis (downward protrusion of the right eye).

Neurologic Examination:

1. *Mental Status*: The patient was, in general, alert but at times would become lethargic. Her affect was flat. At times, she would laugh or joke in an inappropriate manner.
2. *Cranial Nerves*: There was anosmia for odors, such as cloves, on the right and a reduced sensitivity on the left.

Marked papilledema (increased intracranial pressure with protrusion of the optic disk and venous engorgement due to obstruction of the normal flow of CSF) was present in the left eye.

Pallor of the right optic disc was present, indicating optic atrophy. Visual acuity in the right eye was markedly reduced. The patient had only a small crescent of vision in the temporal field of the right eye, where only vague outlines of objects could be seen. A slight left central facial weakness was present.

3. *Motor Systems*: Intact although movements on the left side were slow.

4. *Reflexes*: A release of grasp reflex was present on the left side.

5. *Sensory system*: Intact

Clinical diagnosis: Subfrontal meningioma arising from olfactory groove or inner third sphenoid wing.

Laboratory data:

1. *Skull x-rays* demonstrated erosion of the dorsum sellae. Special lamniograms demonstrated hyperostosis of the sphenoid bone (planum sphenoidale) suggesting a meningioma originating from the sphenoid bone.

2. *EEG* demonstrated focal 2-4 Hz slow waves in the right anterior temporal and anterior lateral frontal area.

3. *Brain scan (H_g 197)* revealed a heavy uptake of isotope in the right posterior subfrontal area.

4. *Arteriograms* indicated that the anterior cerebral arteries were shifted backwards, posteriorly and the left. A tumor blush was present on the venous phase in the right subfrontal area extending back to the optic nerve groove (Fig 23-8). These findings were felt to be most consistent with an olfactory groove meningioma.

Hospital course: Dr. Samuel Brendler performed a bifrontal craniotomy which exposed a well-encapsulated smooth tumor attached to the medial third of the sphenoid wing. After intracapsular removal of 90 to 95% of the tumor, the right optic nerve could be visualized. The small portion of the tumor attached to the bone could not be removed because of considerable bleeding from the bone. Examination 4 months after surgery, indicated right anosmia and right optic atrophy were present.

Comment

If one considered only the patient's primary complaint, decreasing vision in the right eye, and the findings of right optic atrophy and left-sided papilledema (Foster-Kennedy syndrome), then the most probable diagnosis was inner-third sphenoid meningioma. The preservation of a small crescent of vision in the temporal field is consistent with compression of the optic nerve on its lateral surface. By the time of hospitalization, the lesion was quite large and had extended into the subfrontal area, producing anosmia on the right and some changes in personality. At this point, the various diagnostic studies suggested only a subfrontal mass and did not clearly differentiate between an olfactory-groove meningioma and a sphenoid-wing meningioma. One might suggest, in retrospect, that the degree of involvement of the right optic nerve was much more pronounced than the changes in prefrontal functions, and therefore, the inner-third sphenoid-wing location was more likely.

The surgical approach in any case was the same. The eventual recovery of vision in such cases is uncertain because the effects of compression often are not reversible.

The following case 23-2 provides an example of a macroadenoma of the pituitary producing a bitemporal adenoma..

Case 23-2. Patient of Dr. Martha Fehr. This 45-year-old man had an 18-month history of a progressive alteration in vision. He was unable to see objects in the right or left periphery of vision. He was concerned that in the process of driving he might hit pedestrians stepping off the sidewalks in the periphery of vision. He had also experienced over 6-8 months, progressive headaches, loss of energy and libido.

Neurological examination: Normal except for a bitemporal hemianopia.

Clinical diagnosis: Pituitary adenoma compressing the optic chiasm.

Laboratory data:

1. *Endocrine studies:* all were normal including prolactin, am cortisol, and thyroid functions.

2. *MRI:* A large macroadenoma measuring 3 cm in diameter extended outside of the sella turcica to compress the optic chiasm (fig. 23-11).

Subsequent course: Dr. Gerald McGuillicuddy performed a gross total trans sphenoidal resection of the tumor, with a significant improvement in vision. Three years later, the patient again had visual symptoms and eye pain. MRI scans indicated regrowth of tumor with possible impression on the right optic nerve. He was treated with radiotherapy.

Comment: Note that males are more likely to present with large pituitary adenoma compressing the optic chiasm. Women are more likely to present with microadenomas or small macroadenomas since they are more likely to be seen at an earlier stage due to an initial complaint of amenorrhea. Thus complaints of decreased libido in men are likely to be mentioned only in retrospect and not as an early presenting complaint.

The following case illustrates the effects of a space-occupying lesion in the occipital lobe. One should compare these findings to those reported earlier in Case 23-1, in which there was a lesion in the visual system anterior to the optic chiasm.

Case 23-3: This 47-year-old white, right-handed, real estate salesman was referred for evaluation of headache and visual disturbance. One month before admission the patient had a cough with some blood present in the sputum (hemoptysis). Five days before admission the patient developed a generalized headache, which was

precipitated by coughing or straining and which awakened him or prevented him from sleeping.

Two days before admission, the patient noted blurring in the left inferior quadrant of his field of vision.

The day before admission, he noted complete loss of vision in this quadrant. On the day of admission, the headache increased, and the patient was unable to see anything in the left visual field.

He had experienced no weakness, no disturbance of memory, and no language disturbance.

Past history was significant. The patient had multiple pulmonary infections, treated with antibiotics.

Neurologic examination:

1. Mental status: Intact

2. *Cranial nerves* were intact, except that blurring of disc margins was present bilaterally, with venous engorgement, indicating early papilledema.

A left non congruous homonymous hemianopia was present (Fig. 23-14A).

3. Motor system: Intact

4. Reflexes: *Deep tendon reflexes were slightly more active on the left. The plantar response on the left was extensor that on the right was flexor*

Laboratory data:

1. *Electroencephalogram* was abnormal because of frequent focal 3 to 4 cps, slow waves in the right occipital area and to a lesser degree, in the right posterior parietal area, consistent with focal damage in the right occipital area.

2. *Cerebrospinal fluid* pressure was elevated to 210 mm H₂O. The number of white blood cells was increased to 97 lymphocytes (upper normal limit is 5 to 7 lymphocytes). Protein was increased to 75 mg/dl (upper normal limit is 45 mg/dl). Glucose was 75 mg/dl (normal when compared to blood sugar of 95 mg/dl).

3. *Imaging* (radioactive brain scan Hg 197) demonstrated an enhanced region in the posterior and medial aspect of the right hemisphere (occipital and adjacent parietal lobes).

Subsequent course: The patient was treated with antibiotics (cephalothin sodium, penicillin, and streptomycin). Visual fields, EEG, and spinal fluid findings improved. Within 3 weeks the field defect had resolved to a non congruous left inferior quadrantanopia (Fig. 23-14B).

Ten days later the patient was readmitted to the hospital with a three-day history of right eye pain, sweats, and chills. Neurologic examination now revealed a recurrence of blurred optic-disc margins, a left homonymous hemianopia and a slight increase in deep tendon reflexes on the left. Imaging studies now revealed a large space-occupying lesion in the right parietal/occipital region, displacing the right lateral ventricle forward and downward.

After 10 days treatment with antibiotics (penicillin and streptomycin), a craniotomy was performed by Dr. Bertram Selverstone. A mass could be palpated medially in the right occipital and adjacent posterior parietal area. The abscess and a large surrounding area of hard granulomatous cortex and white matter were removed. (The etiologic organism was subsequently found to be a *microaerophilic streptococcus*.)

Postoperatively, the patient continued on treatment with penicillin. Follow-up examination 6 months after surgery was normal, except for the left homonymous hemianopia (Fig. 23-14C).

Comment: The rapid evolution of neurologic signs and symptoms in this case; the early development of papilledema, and the progressive changes in the electroencephalogram and brain scan; is consistent with the diagnosis of brain abscess. The primary infection in this case was probably in the lung.

The initial visual symptoms of inferior field involvement (quadrantanopia) suggested that the abscess, in its early stages, involved predominantly the superior portion of the optic radiation in the posterior parietal/occipital area or the superior bank of the calcarine fissure. With progression of the lesion, the entire optic radiation or the entire calcarine cortex was involved. The lesion found at surgery had destroyed or damaged both these areas.

The treatment of a brain abscess requires appropriate pre- and postoperative use of antibiotics. Many of these patients develop focal seizures at some time after successful surgical treatment of the abscess. Although prophylactic anticonvulsant medication, such as diphenylhydantoin (Dilantin), has been routinely administered, the value of such treatment remains unclear.

Note an important negative finding in this case: at no time did the patient experience any language disturbance. Reading and writing remained intact, as did the capacity for to construct drawings. This case involving the right occipital lobe should be compared with Case History 21-2, in which a focal lesion of the left occipital lobe was present.

The following is another example of the effects of a lesion in the occipital lobe with very different consequences than those seen in the previous case. The lesion clearly involved the cerebral cortex producing focal seizure activity.

Case 23-4. (Fig 23-15): This 18-year-old left-handed single white female restaurant employee was referred for reevaluation of a seizure disorder. While living in the south western United States, the patient had the onset of her seizures at age 14 when she had a sequence of five seizures in less than 12 hours. Each began with flashing lights, "like Christmas tree lights," all over her visual field, plus the sensation that peoples' faces were moving. She then would have an apparent grand mal seizure.

She was hospitalized. The neurological examination was reported as normal. An electroencephalogram report noted occasional focal sharp and slow waves in the left hemisphere. The CT scan was interpreted as essentially within normal limits. In retrospect, there was a question of some mottled hypodensity in the left occipital area, not clearly distinguished from artifact. The patient was treated with carbamazepine (Tegretol), 400 mg in the morning, and 230 mg at hour of sleep. In the interim, she apparently had done quite well with no additional grand mal seizures. She had rare episodes of "fear attacks," which would last 23 to 25 minutes. The last attack had occurred 2 years ago, but as recently as two months ago, she had had one episode of flashing lights. A recent EEG was normal.

Past history was negative, except her birth weight was ten pounds, three ounces, and there was a problem of breathing at birth. She had always done poorly in school. Her family history did not suggest possible causes for a seizure disorder.

Neurologic examination: Normal.

Clinical diagnosis: Seizures of focal origin occipital cortex, (flashing lights and movement of the lights) probably left hemisphere based on the reports received of the EEG. There was subsequent spread of discharge into the temporal lobe based on the report of "fear attacks"

Subsequent course

The patient did well for 3 years then had a recurrence of a generalized convulsive seizure possibly related to omission of medication. Six weeks later, she reported two additional episodes characterized by flashing lights, then movement of the lights away from a center circle, then dizziness, then a

sensation of unreality. She also had other episodes of feeling unreal accompanied by fear. There were no olfactory hallucinations and no other visual or auditory hallucinations. The neurologic examination now demonstrated a minor right central facial weakness not present previously.

Laboratory data:

1. *EEG*: remained normal.
2. *MRI scan*: now revealed a small tumor at the left occipital pole with surrounding edema (Fig. 23-15). On CT scan, this tumor appeared partially calcified but did show enhancement. Angiograms suggested tumor vascularity of a type seen with meningiomas.

Subsequent course: Dr. Bernard Stone removed a discrete encapsulated tumor that appeared to be a meningioma. Subsequent microscopic examination, however, indicated a rare type of indolent follicular adenocarcinoma of the thyroid, which sometimes spreads as a single lesion to brain and remains quiescent for many years. In the postoperative period, a non-congruous right-inferior-field defect was present (partial quadrantanopia). The blood level of thyroid-stimulating hormone (TSH) was elevated. A thyroid nodule was found. A thyroidectomy was performed, and thyroid replacement medication was prescribed. No additional seizures were observed over the next 18 months. A metastatic lesion in the lumbar vertebral body subsequently appeared.

Comment: This patient presented many of the features of focal seizures arising in the occipital cortex: flashing lights, movement of objects and secondary generalization. Some of the seizure phenomenology such as “fear attacks,” dizziness, and “feeling unreal” suggested that spread into the temporal lobe was sometimes occurring. The student should now compare and contrast the cases presented in the previous chapter on the limbic system to this case to be able to note the differences seen after lesions in these adjoining cortical regions.

CHAPTER 24: SPEECH, LANGUAGE FUNCTION, APHASIAS, AGNOSIAS, APRAXIA

The following case, 24-1 presents an example of a selective non fluent aphasia of aphasia. An embolus to the superior division of the left middle cerebral artery produced marked weakness of the face tongue and distal right upper extremity and a severe selective nonfluent aphasia. The

hand weakness rapidly disappeared, the right central facial weakness, an apraxia of tongue movements and some expressive difficulties persisted.

Case 24-1: This 55-year-old, right-handed white housewife while working in her garden at 10:00 a.m. on 04-15-69, the day of admission suddenly developed a weakness of her right side and was unable to speak. Apparently, the right-sided weakness affected predominantly the face and arm since the patient was able to walk. The past history was significant. In 1960, nine years previously, the patient had been admitted to the hospital with a three-year history of progressive congestive heart failure secondary to rheumatic heart disease (mitral stenosis with atrial fibrillation). An open cardiectomy was performed with a mitral valvuloplasty (the valve opening was enlarged). A thrombus found in the left atrial appendage was also removed. Postoperatively, the patient was given an anticoagulant, bishydroxycoumarin (Dicumarol). Although atrial fibrillation continued, she did well until the day of admission. Prothrombin time at the time of admission was close to normal; that is, the patient was not in a therapeutic range for anticoagulation.

General physical examination: Blood pressure was moderately elevated to 170/80. Pulse was 110 and irregular (atrial fibrillation). Examination of the heart revealed the findings of mitral stenosis: a loud first sound, a diastolic rumble and an opening snap at the apex as well as the atrial fibrillation.

Neurological examination:

1. Mental status and language function:
 - a. The patient was alert.
 - b. She had no spontaneous speech and could not use speech to answer questions and could not even use yes or no to provide answers. She could not repeat words.
 - c. The patient was, however, able to indicate answers to questions by nodding (yes) or shaking her head (no), if questions were posed in a multiple choice situation. In this manner it was possible to determine that she was grossly oriented for time, place and person.
 - d. The patient was able to carry out spoken commands and simple written commands, such as, "hold up your hand, close your eyes." However, she had significant difficulty in performing voluntary tongue movements (such as "wiggle your tongue"; "stick out your tongue") on command.
2. Cranial nerves:
 - a. The patient tended to neglect stimuli in the right visual field.
 - b. She was unable to look to the right on command although the head and eyes were not grossly deviated to the left at rest.
 - c. A marked right supranuclear (central) type facial weakness was present.
 - d. The patient had difficulty in tongue protrusion. When the tongue was protruded it deviated to the right. The patient was unable to wiggle the tongue.
3. *Motor system:* Strength: there was a marked weakness without spasticity in the right upper extremity, most prominent distally. Some shoulder movements were possible; no hand or finger movements could be made. There was a minor degree of weakness involving the right lower extremity (75 percent of normal).
4. Reflexes:
 - a. Deep tendon stretch reflexes were increased on the right in the arm and leg.
 - b. Plantar responses were both extensors; more prominent on the right.
 - c. The abdominal reflex was absent on the right; present on the left.
5. Sensory:
 - a. Pain, touch and vibration were intact.
 - b. It was difficult to test other modalities but tactile localization appeared to be intact.

Clinical diagnosis: Embolus from heart to left middle cerebral artery

Laboratory data:

1. *Skull X-rays* were normal.
2. *EEG* was normal (48 hours after admission).
3. Cerebrospinal fluid was normal.
4. *Electrocardiogram* revealed atrial fibrillation

Hospital course: Within 24 hours a significant return of strength in the right hand had occurred; independent finger movements could be made. Within 48 hours after admission the patient was able to

repeat single words but still had almost no spontaneous speech. She appeared aware of her speech disability and would manifest some frustration. She was able to carry out two- or three-stage commands although tongue movements and perseveration remained a problem. Within 6 days of admission the patient used words, phrases and occasional short sentences spontaneously. She was better able to repeat short sentences. At this time strength in the right arm had returned to normal, but a right central facial weakness was still present. More detailed language evaluation two weeks after admission indicated the persistence of expressive disabilities consisting of word-finding and apraxic components. The apraxic components were evident on tongue placement and alternating tongue movements. Although complete sentences were used, sentence formulation in spontaneous speech was slow and labored with word finding difficulties. Repetition was better performed. In reading sentences aloud, substitutions or word omissions were made. The patient did well in naming common pictures and in matching printed words to spoken words or printed words to pictures. She could write from dictation and would often respond preferentially in writing when difficulty in speaking was encountered. No left-right confusion was present. Minor difficulties with simple arithmetic were reported. A right central facial weakness was still present.

Comment: There would appear little doubt that this patient had the sudden passage of an embolus (presumably from the left atrial appendage) into the left middle cerebral artery. In view of the selective face and arm weakness with a predominant expressive aphasia, the involved vessels must have been cortical branches such as the prerolandic and rolandic originating from the superior division of the middle cerebral artery. From the onset, it was clear that although some receptive components might be present, these were minor. The major problem was a severe nonfluent aphasia. As the hand weakness disappeared, the only other residual neurological findings were those of a right central facial weakness and an apraxia of tongue movements. Such findings would, of course, be consistent with a relatively selective involvement of Broca's area in the inferior frontal gyrus.

Why did such a rapid improvement occur in motor function and of the visual field? Most likely, the embolus fragmented and passed into the cortical branches supplying Broca's area.

With the passage of time, this type of patient would continue to show some degree of improvement (Mohr, 1973). Improvement could continue to occur over a two-year period. Although lesions of Broca's area may produce the acute onset of a nonfluent aphasia, rapid amelioration of the deficit occurs even when the acute lesion involves underlying white matter, as well as the superficial cortex.

In the following case 24-2, a more persistent anterior aphasia is demonstrated.

Case 24-2: On May 30, 1985, at midday, this 37-year-old right-handed woman with a past history of rheumatic fever, rheumatic heart disease and "an irregular pulse"(atrial fibrillation) had the sudden onset of loss of speech, central weakness of right face, an inability to protrude the tongue and a right hemiparesis. Although hemiparesis, face and tongue problems disappeared within a week, recovery of speech was slower and limited. At one week, she could produce some two syllable words.

Neurological examination at 17 months revealed the following residual findings:

1. *Language function:* Spontaneous speech was slow and relatively scanty. She could name objects slowly without difficulty, could do some simple repetitions and could write from dictation. She could carry out two and three stage commands. She could read slowly aloud but had little comprehension of what she read.
2. *Reflexes:* A residual right Babinski sign and right-sided hyperreflexia were present.

Clinical diagnosis: Anterior aphasia: embolic infarct of superior division of middle cerebral artery.

Laboratory data:

Although initial CT scans in May 1985 had been reported as negative; the MRIs in November 1986 and June 1990 demonstrated the infarct which included Broca's area, as well as adjacent frontal areas with predominant involvement of frontal operculum (inferior frontal gyrus) and adjacent middle frontal gyrus. In addition, a minor independent infarct was present in right occipital area (presumably embolic to the calcarine artery).

Subsequent course: Similar findings were present at 5 years, June 1990).

A brain section from a patient (Case 24-3) with a persistent nonfluent aphasia (is presented in Figure 24-4.

Case 24-3: This 69-year-old, right-handed male expired in 1965. In 1961 and 1963, The patient, had experienced transient episodes of right hemiparesis and aphasia, both followed by complete recovery. In 1964, a more persistent right hemiparesis and aphasia had developed.

General physical examination: No left carotid pulsation was present.

Neurologic examination(1965):

1. **Language functions:** Speech was nonfluent with only a small verbal output. A significant nominal aphasia with paraphasias was present. Reading was limited. Comprehension of spoken language was good. A marked apraxia was present for movements of tongue, lips and hands.
2. **Motor system:** Right hemiparesis with associated reflex findings.
Post mortem findings: Left carotid occlusion with old infarction, predominantly of left middle cerebral territory with lesser involvement of anterior cerebral territory. Note that minor cortical infarcts are also present involving cortex of right hemisphere.
(Courtesy of Dr. John Hills,; and Dr. Jose Segarra.)

Case 24-4 provides an example of a patient with a Wernicke's type aphasia

Case 24-4: This 40-year-old, right-handed white male had experienced a series of myocardial infarctions beginning 10 months prior to consultation. Angiographic studies indicated occlusion of the right coronary artery and the left anterior descending coronary artery with stenosis of the circumflex artery. The patient was subsequently admitted and a coronary artery bypass procedure was performed using extracorporeal circulation. Although the patient was stated to have tolerated the procedure well, the anesthetist noted that the patient was nonreactive 15minutes after the last administration of halothane anesthesia. When the patient did wake up, he was quite agitated requiring the use of agents to reduce agitation. Throughout the postoperative period, the patient continued in a disoriented and combative manner. Because of the patient's acutely psychotic state, transfer to the psychiatry service was actively planned. Because there were certain organic features to the patient's illness, a neurological consultation was obtained. The neurology resident in reviewing the progress notes discovered a notation that shortly after surgery the patient had transient difficulty in using his right arm.

Neurological examination:

1. **Mental status:**
 - a. The patient was an alert but agitated white male. Additional inquiries indicated that his agitation related to his inability to write a letter to his mother.
 - b. The patient's speech was fluent and usually grammatical. He made use of many paraphasias and neologisms (nonsense words). He often appeared unaware of his errors.
 - c. The patient was unable to name single objects such as pencil, cup, and spoon though he could recognize and demonstrate their use.
 - d. The patient could read occasional individual words; for example, cat, house. He could not comprehend or carry out, either spoken or written commands.
 - e. His attempts at spontaneous writing produced only a few letters. He was unable to write words or phrases from dictation. He did significantly better when asked to copy a printed sentence or phrase.
- f. Repetition of spoken phrases or sentences was poor.
- g. Calculations of even a simple nature were poorly performed.
2. **Cranial nerves:** II-XII was intact.
3. **Motor system:** No actual weakness was present. Gait was intact.
4. **Reflexes:**
 - a. A minor increase in deep tendon stretch reflexes was present on the right side.
 - b. The plantar response on the right was equivocal. The left was flexor.
5. **Sensation:** Pain, touch and vibration were intact.

Clinical diagnosis: Wernicke's type of fluent aphasia probably secondary to an embolus to the inferior division of the middle cerebral artery.

Comment: This patient who was seen before the era of modern neuroimaging provides an example of the clinical picture described by Wernicke. The use of the heart pump for open-heart surgery was associated with a high incidence of cerebral

emboli. The incidence of this complication has decreased as technical advances have been made and as “time on the pump” has decreased. As we have stressed, for solving neurological problems, the details of the history are important if the appropriate diagnosis is to be made. In the patient who is unable to provide a history, the careful review of progress notes and of nurses notes will often provide the clue that allows diagnosis.

The following case history 24-5 demonstrates such a sequence of involvement in a tumor infiltrating the posterior temporal inferior parietal area starting with a conduction aphasia.

Case 24-5: This 42-year-old right handed truck driver noted fatigue and irritability 6-8 weeks prior to admission. Three to four weeks prior to admission, he noted he was using words which he did not mean to use and certain words would not come to him. He had two generalized convulsive seizures; each proceeded by a ringing sensation in the ears, during the week prior to admission.

Neurological examination:

1. Mental status and language function

- a. The patient was alert and oriented to time, place and person.
 - b. He was cooperative and able to carry out the four-step command: “stick out your tongue, close your eyes, hold up your hand and touch the thumb to your ear”. There was however evidence of a significant left-right confusion when laterality was introduced e.g. “left hand to right ear”.
 - c. The ability to do even simple calculations was markedly impaired with or without paper e.g. $100-9=99$.
 - d. Memory was impaired; with immediate recall object recall limited to 2/5 objects and delayed recall in 5 minutes limited to 0/5. Digit span was limited to 2 forward and 0 in reverse. (normal would be 7 forward and 6 in reverse).
 - e. There was little evidence of an expressive aphasia. Flow of speech was slow with only minor mispronunciations. Reading was slow but with few errors. The patient’s did have minor difficulty in naming objects-a mild nominal aphasia. The patient’s greatest difficulty was in repetition of simple test phrases. There were moderate defects in drawings of a house and a clock but few errors in copying simple figures. There was a significant dysgraphia with marked difficulty in writing a simple sentence spontaneously or in writing from dictation. On the other hand, the patient was much better able to copy a simple sentence. Significant errors were made in spelling.
2. **Cranial nerves:** All were intact except for a mild right central facial weakness.
 3. **Motor system:** Strength, gait and cerebellar functions were all intact.
 4. **Sensory system:** Pain, touch, vibration, stereognosis, simultaneous stimulation, graphesthesia, and position sense were all intact, but point localization was impaired on the right side.

Clinical Diagnosis: Fluent posterior aphasia, disconnection syndrome plus elements of Gerstmann’s syndrome (left right confusion, dyscalculia, dysgraphia) plus seizures of focal origin (Heschl’s gyrus posterior temporal lobe) with secondary generalization. All suggested a lesion in the left posterior temporal-posterior parietal area.

Etiology was uncertain but tumor (glioma) or embolus to inferior division of left middle cerebral artery possible.

Laboratory data:

1. Skull and chest x-rays were normal.
2. **EEG:** Focal 4-5 Hz slow wave activity was present in the left parietal and posterior temporal areas.
3. **Brain scan (radioactive Hg 197):** Increased up take of isotope in the left posterior temporal –parietal area measuring 4x5 cm.
4. **Left carotid arteriogram:** Vascular mass in the region of the angular gyrus with tumor stain in the area.

Subsequent course: Papilledema soon developed and Dr. Robert Yuan performed a craniotomy. Although the cortex appeared externally normal, a firm mass could be palpated

slightly above and posterior to the angular gyrus. At 2 cm below the surface, firm yellow tumor tissue was encountered. All visible tumor and adjacent cortex of the angular and supramarginal gyri were removed and a partial left temporal lobectomy was performed. Histologic examination indicated a highly malignant glial tumor with active mitosis and necrosis (a glioblastoma multiforme). Post operatively, the patient had a marked expressive and receptive aphasia. By 30 days after surgery, the patient had a significant improvement in fluency, he continued to have a severe posterior type of aphasia. He was unable to carry out simple commands. His speech was incoherent, with nonsense words and neologisms. He appeared unaware of his errors and did not appear frustrated by his failure to follow commands. In addition to this Wernicke's type aphasia, the patient was unable to repeat words of two syllables. He could do no calculations, had severe difficulties in copying drawings and was unable to even write his name. The patient received radiotherapy but his condition continued to worsen with the development of a progressive expressive and receptive aphasia and hemiparesis all suggesting the spread of a rapidly growing glioblastoma. Coma, pupillary changes and respiratory changes then intervened suggesting the effects of herniation of the residual temporal lobe. Death occurred 7 months after onset of symptoms, and 5 months following surgery.

Comment: The early language and mental status disturbances in this patient were most severe in those tasks requiring repetition. Thus the patient could repeat no more than two digits, was unable to repeat any of the test phrases and was unable to write from dictation at a time when he could copy a sentence. Any expressive aphasia was minor, and he was fluent. He had no evidence of Wernicke type aphasia, since he could carry out a four-stage command without difficulty. Reading was relatively well preserved compared to writing, calculations and drawing construction. All of these findings suggest (1) the speech reception Wernicke's area was disconnected from the motor association areas for speech and writing Broca's areas 44,45 and the related areas of the premotor cortex and (2) the inferior parietal areas associated with writing, calculations, drawing, and the ability to distinguish left and right were damaged. The lesion found at surgery was deep to the angular and supramarginal gyri, the location of the arcuate sulcus. The seizures that finally brought the patient to neurological attention were originating in Heschl's gyrus of the temporal lobe, which would be adjacent to the area of the tumor.

The clinical state at 30 days following surgery reflected the additional effects of ablation of the Wernicke's area as well as the accentuation of the preoperative state. There had been the transient appearance of an expressive aphasia probably reflecting minor effects of the procedure on Broca's area.

The neurosurgical approach to the management of a glioblastoma particularly those involving the speech areas of the dominant hemisphere have changed in 35 years since this patient was seen. A limited stereotaxic biopsy under CT scan guidance would be undertaken and the patient would then be treated with dexamethasone and radiotherapy. The end results would have been similar and actually may even have occurred earlier. The postoperative quality of language function may have been transiently better. Unfortunately this patient had a very malignant and aggressive tumor. The median survival of glioblastomas with surgery alone is 26 weeks, with the addition of radiotherapy; 52-60 weeks. Median means that 50% of patients are going to survive less than these median figures.

The following case (24-6) provides a case of posterior aphasia with the lesion documented with CT scan.

Case 24-6: This 57-year-old female, with a long history of hypertension in the summer of 1985, had a brief episode of difficulty in word finding and a more prolonged episode in December 1985 with confusion, "visual problems", "inappropriate speech and difficulty finding the appropriate words". Following an additional episode in March 1986, she had persistent problems in reading and apraxia of the right hand.

Neurological examination (May 1986): The following abnormalities were present:

1. *Language function:* Spontaneous speech was usually quite fluent. She described the room, the environment and her friend. In contrast, capacity for repetition was very poor both as regards spoken and written speech. Spontaneous writing was very poor except for name and address

Reading to herself aloud was poor with little comprehension. She was able, however, to follow single one stage spoken or written commands but unable to do a sequence of commands. Naming of objects was well performed.

2. *Cranial nerves*: Extinction occurred in the right visual field for bilateral simultaneous stimuli.
3. *Motor system*: No hemiparesis was present.
4. *Reflexes*: Right-sided hyperreflexia and a right Babinski sign were present.

Clinical diagnosis: Posterior aphasia, infarction left posterior temporal and parietal areas, probably due to embolic occlusion of inferior division of the left middle cerebral artery.

Laboratory data:

1. *CT scan*: Infarct left posterior temporal and parietal areas (Fig. 24-6).
2. *Angiograms*: Occlusion of the left internal carotid artery. All anterior and middle cerebral artery branches filled from the right carotid. An artery to artery embolus was presumed.

The following case 24-7 would suggest this type of unilateral lesion producing a transient and partial but selective type of dyslexia.

Case 24-7: Seven days prior to admission, following a period of athletic activity, this 15-year-old, right-handed white male high school student had the onset of a 48-hour period of sharp pain in the left jaw and the supraorbital area. The next day the patient began to complain of blurring of vision and the following day had the onset of vomiting. Four days prior to admission, the patient noted that he was unable to read and to translate his Latin lessons. No definite aphasia was apparent. Two days prior to admission, the patient had the sudden onset of severe left facial pain, accompanied by tingling paresthesias of the right leg. The patient became stuporous and then unresponsive for approximately 90 minutes. An examination of spinal fluid at that time revealed pressure elevated to 290 mm of csf with 250 fresh blood cells.

Neurological examination:

1. *Mental status*: All aspects, including language function were intact.
2. *Cranial nerves*:
 - a. Examination of the fundus showed several small flame shaped hemorrhages. Visual fields were intact.
 - b. A slight, right, supranuclear-type (central) facial weakness was present.
3. *Motor system*: Intact
4. *Reflexes*: Deep tendon reflexes and superficial reflexes were symmetrical and physiologic.
5. *Sensory system*: Primary and cortical modalities were intact.
6. *Neck*: A slight degree of resistance was present on flexion of the neck (nuchal rigidity) consistent with the presence of blood in the subarachnoid space.

Clinical diagnosis: Subarachnoid hemorrhage of uncertain etiology. In view of age and the transient dyslexia, and the transient paresthesias of the right leg, an arteriovenous malformation in the left parasagittal parietal-occipital area might be suspected.

Laboratory data:

Arteriograms: An arteriovenous malformation was present in the left occipital region. The main arterial supply was the posterior temporal branch of the left posterior cerebral artery. The malformation drained into the lateral sinus. The posterior portion of the anterior cerebral artery was shifted across the midline, indicating a hematoma as well as the malformation.

Subsequent course: On that evening after his admission, the patient had the sudden onset of a bifrontal headache. For a 2- to 3-minute period, the patient was unconscious with deviation (repetitive driving) of both eyes to the right, and with sweating and slowing of the pulse rate. Over the next two days an increase in blurring of the optic disc margins was noted (early papilledema). Four days after admission, the patient suddenly complained of being unable to see from his right eye. He became restless and agitated. Additional headache and neck pain with numbness of right arm and leg were reported. Examination now disclosed a dense right visual field defect (homonymous hemianopsia). The deep tendon reflexes were now slightly more active on the right. Funduscopy examination suggested that

recent additional subarachnoid bleeding had occurred since new retinal hemorrhages were present. The next day (five days after admission), the patient was noted to have a significant reading disability (dyslexia), although other language functions were intact.

Because of the progressive evolution of neurological findings due to an expanding intracerebral hematoma, Doctor Robert Yuan performed a craniotomy. Blood was present in the subarachnoid space. The left lateral occipital cortical surface had numerous areas of bluish discoloration indicating an intracerebral clot. The main arterial vessel was a lateral and inferior branch of the posterior cerebral artery, bearing no relationship to the calcarine region. The draining vein was located in the occipital-temporal area, close to the tentorium. At a depth of 1 cm, a hematoma of 50 cc of clot was found. The clot extended down to the occipital horn of the lateral ventricle but did not enter the ventricle. The malformation, hematoma and related cerebral tissue of the lateral occipital area were removed. The calcarine area remained intact at the end of the procedure. Over a period of several days, the visual field deficits disappeared.

Detailed language and psychological testing approximately two weeks after surgery indicated that language function was intact except for reading. Oral reading was very slow (4 times slower than normal for a test paragraph), halting and stumbling. Comprehension of the material read was good. Minor errors were made in the visual recognition of letters. This was reflected in occasional errors in spelling. Visual recognition and naming of objects was intact. Auditory and tactile recognition of sounds, words, letters, sentences, questions, commands and so forth was intact. Calculations were intact. No right-left confusion or finger agnosia was present. Writing and drawing were intact but slow. Repetition of speech and spontaneous speech were intact.

Follow-up evaluation at 20 and 30 months indicated that, although the patient was doing well in school, receiving A's and B's with excellent grades in mathematics, he still was described as slow in reading compared to his level prior to illness. No actual errors were made in reading when this was tested.

Comment: The arteriovenous malformation in this case had involved and eventually required surgical removal of the lateral occipital area of the dominant hemisphere. The hematoma in the occipital lobe extending in from the lateral surface to the occipital horn was so located as to compress the optic radiation passing to the calcarine cortex or perhaps even to indirectly compress the calcarine cortex. Such a hematoma would also interfere with association fibers passing from left occipital areas to temporal parietal areas and with callosal radiation fibers passing from the occipital region (area 18) of the right hemisphere to the occipital and parietal areas of the dominant hemisphere. Following surgery, the patient had a relatively good recovery with the minor difficulties in reading; (a selective dyslexia) as perhaps the only indication of any damage to these fiber systems.

The complaint of the patient at the time that the right homonymous hemianopsia appeared was of blindness in the right eye. It is not uncommon for patients to localize field defects in this manner to the eye of the same side. The same may sometimes be true of patients with discharging lesions in the occipital area; the flashing lights and lines may be localized to the contralateral eye rather than to the contralateral visual field.

The episode on the night of admission is of interest because it suggests a focal adverse seizure, in this case presumably originating from areas 18 and 19 of the left hemisphere.

Geschwind (1965) has reviewed many of the previously reported cases of selective dyslexia. It is uncertain whether the information from area 18 of the non-dominant hemisphere passes to the non-dominant angular gyrus and then crosses to the dominant temporal parietal areas or whether these fibers pass instead directly to area 18 of the dominant hemisphere with information then conveyed to the dominant temporal parietal areas. He finally concludes that both pathways are probably operative. The relatively minor nature of the final residual deficit in the present case would be consistent with such multiple pathways. In addition, non-fatal hemorrhages always produce less damage than infarcts of comparable size. Finally, Coslett (2000) has reviewed various recovered pure cases of dyslexia where the right hemisphere may have played a role in reading. Such patients do better with concrete nouns than abstract nouns, verbs and functors (pronouns, prepositions, conjunctions and interrogatives). It should be noted that a relatively selective dyslexia in the absence of a severe general visual agnosia might occur. Geschwind has suggested that whether a general visual agnosia or dyslexia occurs may depend on the degree of disconnection of the dominant speech areas from the parietal and occipital areas of the non-dominant hemisphere. In the patient who already has left occipital cortex damage, dyslexia may require only damage to the splenium of the corpus callosum, whereas visual agnosia may require more extensive damage to the posterior body of the corpus callosum as well. As noted bilateral

visual association lesions (areas 18 and 19) would also produce a visual agnosia. (See also Coslett and Saffran 1989 and Friedman and Albert 1985).

In addition there are patients who have acquired dyslexia which is unrelated to the processing of the visual information input. These patients have a central (rather than the peripheral dyslexia of the pure alexia syndrome discussed above). The central dyslexic patient has an impairment of the “deeper” or “higher” reading functions by which visual word forms mediate access to meaning or speech production mechanisms. This problem is reviewed in detail by Coslett (2000).

Feinberg and Farah (2000) review the general topic of agnosias.

CHAPTER 26: VASCULAR SYNDROMES OF THE CEREBRAL HEMISPHERES

The following case history presents a young adult with severe carotid stenosis and infarction of the territories of both the anterior and middle cerebral arteries.

Case 26-1: This 23 year old right handed female on birth control pills, smoking one pack of cigarettes per day, on June 15, 1985 shortly after intranasal “snorting” of cocaine complained of gradually increasing right sided headache and then fell to the floor with a flaccid left hemiplegia with the head and eyes deviated to the right **Neurological examination:**

1. *Mental status:* The patient denied any illness and could not explain why she was in the hospital.
2. *Cranial nerves:* There was a left homonymous hemianopsia, deviation of head and eyes to the left and a left central facial weakness.
3. *Motor system:* A flaccid left hemiparesis was present.
4. *Reflexes:* deep tendon reflexes were initially depressed on the left side. Plantar responses were extensor bilaterally.
5. *Sensory system* a severe left hemisensory deficit, with a neglect of the left side of space and body was present.

Clinical diagnosis: Total right middle cerebral artery territory infarct.

Laboratory data:

1. *Initial CT Scan* demonstrated hypodensity (infarction in right frontal and parietal areas).
2. *Right carotid angiogram* demonstrated severe stenosis of the supraclinoid segment of the right internal carotid artery with severe stenosis of the M-1 segment of the right middle cerebral artery and multiple areas of narrowing of the remainder of the right MCA. *Left carotid angiogram* indicated only limited cross filling of the distal right middle and anterior cerebral arteries.

Subsequent course: On 6-21-85, 6 days after admission the previously alert patient suddenly developed a decreased level of consciousness and a fixed, dilated right pupil suggesting that tentorial herniation had been produced by severe edema or hemorrhagic transformation of the infarct. CT Scan now demonstrated massive infarction and edema-right anterior and middle cerebral artery territories plus-transtentorial and sub falx herniation (Fig.26-6). With emergency management of the increased intracranial pressure-(monitor and osmotic agents) the patient became more alert and was transferred to a rehabilitation facility.

Comment: This young woman had as a major risk factor, the intranasal snorting of cocaine. The vasospasm induced by this agent was sufficient to produce severe stenosis of the internal carotid and the initial segment of the middle cerebral artery. The multiple areas of narrowing seen in the branches of the MCA may well have represented emboli from these more proximal sources. Whether the severe stenosis of the M1 portion also involved an embolic event from the siphon remains unclear. It is clear that the severe stenosis of the carotid artery produced infarction of both the MCA and ACA territories. In this case there was insufficient cross flow from the left carotid supply to prevent infarction. As we will see in case 26-3 massive infarcts of the MCA territory plus or minus adjacent territories constitute a serious threat to life due to massive edema and or hemorrhagic infarction with the risk of herniation. The use of cocaine and of crack cocaine may be associated coronary or cerebral artery vasospasm. In addition to cerebral infarcts, cerebral hemorrhage may also occur, particularly with crack cocaine.

The following case history concerns a patient with severe stenosis at the carotid bifurcation producing both retinal and hemispheric TIA's.

Case 26-2: This 54-year-old, right-handed, white male had experienced intermittent episodes of blurring and blacking out of vision in the left eye for at least 7 years. Each episode would last 30 to 60 seconds and would occur twice per month. Ten days prior to admission, the patient had the onset of numbness of the right side of the face accompanied by minor weakness of the right face, arm, and leg. There was also a transient difficulty

in speech (possibly dysarthria, possibly difficulty in word finding). Symptoms cleared completely in 45 to 60 minutes with the exception of residual numbness of the right side of the face.

Family history: The patient's mother died of a "stroke" at age 66 years, and his father, of heart disease at age 57.

General physical examination:

- (1) Blood pressure was slightly increased to 160/100 in both arms. Pulse rate and rhythm were normal
- (2) Bruits (murmurs) were present over each carotid artery, but the heart was normal with no murmurs.
- (3) The retinal artery pulsation was easily obliterated by pressure on the globe of the left eye. No significant changes occurred on compression of the right globe.
- (4) Peripheral pulses were poor in the lower extremities.

Neurological examination: Mental status, language function, cranial nerves, motor system, reflexes, and sensory system were all normal except for a minor right central facial weakness.

Clinical diagnosis: Carotid stenosis with retinal and hemispheric TIA's.

Laboratory data:

1. Hemoglobin, serological tests for syphilis, skull and chest x-rays, electroencephalogram, and brain scan were all normal. Cholesterol was elevated to 284 mg%.

2. *Arteriography (aortic arch study)* demonstrated a complete occlusion at the origin of the left internal carotid artery. A right brachial arteriogram demonstrated filling of the left anterior and middle cerebral arteries by cross flow through the anterior communicating artery from the right side. Additional studies also demonstrated filling of the intracranial portion of the left internal carotid artery from the left posterior communicating artery.

Subsequent course: Ten days after that hospital admission, a left carotid endarterectomy was performed by Dr. Allan Callow with a restoration of blood flow following removal of the occlusive lesion (atherosclerosis with recent thrombosis) at the carotid bifurcation.

Comment: The location of disease in the left carotid artery was clearly indicated by the episodes of left eye visual disturbances followed by symptoms on the contralateral side of the body. The development of symptoms in the face, with disturbance of speech is consistent with total occlusion of the carotid artery, with greater involvement of the middle cerebral territory than of the anterior cerebral territory. The fact that this patient, with progressive stenosis of the carotid artery, had symptoms for many years only in the ophthalmic-retinal artery distribution, is explained by the excellent collateral flow into the anterior and middle cerebral arteries from the anterior communicating bypass. In addition collateral flow would enter the common carotid artery from the posterior communicating artery above the take off of the ophthalmic artery.

It should be apparent that the final complex of neurological symptoms and signs, occurring with occlusion of the carotid artery, will depend on the total pattern of cerebral blood flow in the individual patient. In many patients total occlusion of the carotid artery will produce an infarction of that portion of the cerebral hemisphere supplied by the carotid artery (primarily the middle cerebral territory). In others, a benign outcome is the result (Bornstein and Norris, 1989). With the development of imaging techniques such as CT and MRI scan - has come the recognition that small silent infarcts may occur in patients with non symptomatic stenosis of the carotid artery (Norris and Zhu, 1992).

In this case, the occurrence of symptoms in the right side of the face plus the difficulty in speech might raise the question of a possible embolus to a branch of the MCA from the thrombus at the bifurcation. A perfusion deficit would have produced problems primarily in the border zone (the area of the arm).

In this particular case, earlier evaluation of the patient might well have resulted in a demonstration of occlusive disease of the extracranial portion of the carotid artery

prior to total occlusion. For such patients surgical therapy is feasible. To restore blood flow 20 days after occlusion as in this case is unusual.

A question which remains unanswered in this case is whether this patient would have proceeded eventually to a completed lasting hemiparesis. Kase et al (1991) have summarized the various studies. The rate of completion of the stroke over a 40 month period varied from 2% (Marshall, 1964) to 51%.

The following case demonstrates a case in which the patient began with carotid TIA's progressed to a carotid border zone syndrome of infarction and then involved additionally all of the middle cerebral artery territory.

Case 26-3 (Pt. of Dr. Thomas Mullins): This 72-year old right-handed white male was admitted for evaluation of two episodes of right upper extremity weakness, each of two hours duration, beginning 2 days prior to admission. Following the first episode, the patient had persistent left-right disorientation, a deterioration in writing (dysgraphia), could not understand what he had read and had transient slurring of speech.

Neurological examination:

1. *Mental status and language function:* Intact for alertness and orientation. Language was fluent with intact repetition, and object naming; however, reading comprehension, writing, and left-right orientation were all impaired.
2. Cranial nerves: Intact.
3. Motor system, reflexes and sensory system were all entirely intact.
4. *Carotids:* A bruit was present on the left.

Clinical diagnosis: Carotid artery stenosis with TIA's reflecting decreased perfusion in the border zone followed by thrombosis and passage of emboli to the inferior division of the middle cerebral artery.

Laboratory Data:

1. CT scan and EKG were normal
2. An *arteriogram* performed on the day following admission demonstrated the following:
 - (a) The left internal carotid artery was completely occluded just above the bifurcation (Fig. 26-7A).
 - (b) The left external carotid artery did fill the left internal carotid artery at the siphon through anastomosis about the orbit (Fig. 26-7B). However, there was a cutoff just below the siphon suggesting that the thrombus (clot) at the bifurcation had extended to this level. Moreover, the left middle and anterior cerebral arteries failed to fill in this manner.
 - (c) The left posterior cerebral artery did originate from this segment of the otherwise occluded carotid siphon segment but with no retrograde filling into the basilar artery (Fig. 26-7B).
- 4) The right carotid artery filled not only the right middle cerebral and anterior cerebral artery but also was the source of the right posterior cerebral artery (Fig. 26-7C).
- 5) The right carotid system also supplied the left anterior cerebral artery and to a limited extent the left middle cerebral artery (Fig. 26-7D).

Subsequent course: On the day following admission, weakness in the right hand at wrist and finger extensors recurred. During the arteriogram, the patient was noted to have additional problems with speech. Weakness in the right upper extremity increased. Despite subsequent anticoagulation, additional progression occurred with total paralysis of the right upper extremity, aphasia and a right homonymous hemianopsia. A *repeat CT scan*, 72 hours after these events, demonstrated acute infarction with severe edema involving the entire cortical and deep territory of the middle cerebral artery and the cortical territory of the posterior cerebral artery but with relative sparing of the anterior cerebral artery territory and of the thalamic territory of the posterior cerebral artery (Fig. 26-8). Coma developed secondary to the herniation effects on the brainstem and the patient expired 8 days after admission.

Comment: This patient clearly had hemispheric carotid border zone TIA's followed by persistent symptoms that suggested involvement of the inferior division of the middle cerebral artery to the inferior parietal lobule. These latter persistent symptoms may well have been embolic from the thrombus at the level of the carotid bifurcation. There then was progression of the border zone findings

followed by involvement of the entire middle cerebral artery territory and of the cortical territory of the posterior cerebral artery. The end result was a massive cerebral infarct with considerable swelling. Such massive swelling with herniation of temporal lobe through tentorium and secondary brainstem compression is the major cause of acute death in patients dying after acute carotid artery or massive middle cerebral artery infarctions (31%). Other causes of death are pneumonia (29%), cardiac arrest (17%), pulmonary embolus (13%) (Bounds et al 1981).

Not all patients with acute carotid infarcts continue to progress. In the series of Jones and Milliken (1976), 39% of patients remained stable. Thirty-five percent had gradual improvement and 19% had a progressing deficit over 48 hours.

The following case history illustrates such an occlusion with massive infarction of the entire territory of the middle cerebral artery.

Case 26-4: This 61-year-old, right-handed black housewife one week prior to admission, suddenly fell to the floor while taking a bath and lost consciousness. She was picked up off the floor by her son who found that she was unable to move her left arm and leg. She was unable to walk and had regained no function in these extremities. Her speech had been thick, but no aphasia had been present. No headache had been noted.

Past history: Hypertension had been present for three years. Five days prior to admission, she had been switched to a new antihypertensive medication. There was no history of heart disease. Both parents had died of heart disease and hypertension.

General physical examination: Blood pressure was 150/100, pulse was regular at 84. Blood pressure was 150/100, the pulse was 84 and regular.

Neurological examination:

1. *Mental status:* The patient was obtunded and slow to respond. However, she was grossly oriented to time, place, and person.

2. *Cranial nerves:*

- a. The head and eyes were deviated to the right. The patient could not move the eyes to the left on command. However, on vestibular stimulation, the eyes could be moved to the left.
 - b. The patient neglected stimuli in the left visual field. The pupils did respond to light.
 - c. Papilledema was present bilaterally particularly in the right fundus where a recent hemorrhage was present.
 - d. There was a decrease in pain sensation or a neglect of painful stimuli on the left side of the face.
 - e. A marked left central facial weakness was present.
3. *Motor system:* A complete flaccid paralysis of the left arm and leg was present. The patient was unable to sit up without support.
4. *Reflexes:* Deep tendon reflexes were increased on the left compared to the right. The left plantar response was extensor.
5. *Sensory system:* All modalities of sensation were decreased on the left side of the body.

Clinical diagnosis: Acute occlusion of the stem of the middle cerebral artery, possibly embolic, although primary occlusions of intracranial arteries may occur in the non-Caucasian population. Hypertensive intracerebral hemorrhage was a less likely possibility.

Laboratory data:

1. *Chest and skull x-rays* were negative but the *electrocardiogram* showed left ventricular hypertrophy.
2. *Electroencephalogram* indicated focal damage throughout the right hemisphere—most prominent in the right frontal area, (focal 3 to 5 Hz slow waves). In addition there was a relative absence of electrical activity in the right temporal area (Fig. 2-23) consistent with a severe degree of destruction of this area.
3. Brain scan 3 days after admission showed a significant but diffuse uptake of isotope (Hg^{197}) in the right hemisphere. A repeat brain scan on 9 days after admission showed a more marked uptake measuring 11x6x6 cm., extending from the right frontal area to the posterior parietal area. Uptake extended from the surface to the deep midline (Fig. 26-14).
4. Cerebrospinal fluid contained no significant cells. Protein was moderately increased to 57 mg./100 ml. Pressure at the lumbar area was 150 mm. of csf.
6. Right brachial arteriogram revealed a complete occlusion of the right middle cerebral artery at its origin (Fig. 26-15).

Hospital course: The patient showed no significant improvement during a four week hospital course.

Comment: The patient had a sudden occlusion of the right middle cerebral artery with massive infarction of the entire area of the right hemisphere supplied by the middle cerebral artery. Such massive infarctions are often, as in this case, associated with a significant degree of cerebral edema with the development of papilledema. At times the degree of swelling of the cerebral hemisphere may be sufficient to displace the pineal or the anterior cerebral artery. It is also possible in this case that the infarct was secondarily hemorrhagic. In many cases of hemorrhagic infarction the spinal fluid does not contain red blood cells.

The equal involvement of arm, leg, and face was consistent with the involvement of the penetrating branches of the middle cerebral artery with resultant infarction in the posterior limb of the internal capsule. The deviation of head and eyes to the right indicates destruction of area 8 of the right hemisphere or of the fibers descending from this area, through the corona radiata. Involvement of the cortex in addition to this the internal capsule is also indicated by the findings on the brain scan and electroencephalogram and by the neglect of visual and tactile stimuli on the left side. As regards the etiology, an embolus to the middle cerebral artery is the most likely etiology although in a non-Caucasian patient, primary occlusion could not be ruled out. Today this patient would probably have been treated with t-PA presuming that she had arrived at an emergency room capable of administration of this agent within 3 hours of onset of symptoms and did not have contraindications in terms of preexisting conditions or of CT scan findings (hemorrhage or massive infarction -refer to Brott & Boguslavsky, 2000).

Prognosis for survival during the acute state of the first week depends on the degree of edema patients with massive middle cerebral artery territory infarcts due to MCA occlusion who already had early CT scan evidence of brain swelling within 24 hours of the ictus. Fifty five percent of these patients expired, overwhelmingly of herniation effects. Patients older than 45 years had a poorer prognosis than younger patients. Infection of the lungs is a serious complication of large infarcts and a major cause of death during the second week. If the patient survives, prognosis for recovery is related to the size of infarct. Less than 3 cm. infarcts may be associated with a good recovery; greater than 3 cm. with severe disability (Olson, 1991). This patient had already survived for one week prior to reaching the neurologic center. Although she continued to survive, her prognosis for recovery remained poor.

The following case history illustrates many aspects of ischemia within the cortical distribution of the posterior cerebral artery. This patient demonstrates the general rule that posterior cerebral cortical infarcts are usually embolic.

Case 26-5: This 55 year old ambidextrous married white female research coordinator at approximately 11:30 AM on the day of admission suddenly developed blurring of vision possibly all over her field of vision, possibly in her left visual field, possibly in her left eye. A coworker checked her vision, and found that she had a left visual field defect. Shortly thereafter, she developed tingling paresthesias of the left face arm and leg.

Past history: Hypertension treated with hydrochlorothiazide and Lasix.

Physical examination: Blood pressure was elevated to 160/70. Weight was elevated to 264 pounds. A small ecchymosis was present under the toenail of the left second digit.

Neurological examination, (3 hours after onset):

1. Mental status: Intact.

2. *Cranial nerves:* A non-congruous left homonymous hemianopsia was presented greater in the left temporal field than the right nasal field.

3. Motor system: Intact.

4. *Reflexes:* Deep tendon stretch reflexes were decreased in the lower extremities (patella, 1+ and Achilles, 0). Plantar responses were equivocal, with the left probably extensor.

5. *Sensory system:* There was decreased pain and errors were made in graphesthesia over the left foot.

6. *Vascular:* There were no bruits over the carotids and subclavian areas and the blood pressures in the two arms were equal.

Clinical diagnosis: Posterior cerebral artery ischemia and possible infarct, probably embolic, involving the right calcarine cortex and thalamus or a lacunar event involving the right thalamus.

Laboratory data:

1. Duplex scans of the carotid and vertebral arteries and CT scan of the head on the day of the event were normal. RPR, ESR, TSH, proteins C, S, antithrombin 3 and all anticardiolipin antibodies were normal.
2. *MRI*, 4 days after onset (Fig.26-18) :small area of increased signal in the right occipital lobe in region of the visual cortex consistent with an infarct in distribution of the calcarine artery.
3. *MRA* (Fig.26-19): decreased flow in the distal right posterior cerebral artery probable embolic occlusion with filling of distal branches by anastomotic flow.
4. *Holter monitoring* demonstrated multiple brief episodes of paroxysmal atrial fibrillation.
5. The routine *transthoracic echocardiogram* demonstrated no clear cut abnormalities. However the *transesophageal echocardiogram* demonstrated a definite patent foramen ovale with right to left shunting.

Subsequent course: Reevaluation of the patient 22 hours after the onset of symptoms demonstrated clearing of all neurologic findings. When seen 2 weeks after the event her only complaint related to some problems in reading. This patient already been receiving aspirin at the time of the event and this was discontinued. She was begun on lifelong systemic anticoagulation with coumadin by the consultant cardiologist Dr. Filiberti since she had two conditions associated with embolization: paroxysmal atrial fibrillation and patent foramen ovale with right to left shunting. The patient did well over the subsequent 5 years.

Comment: When initially evaluated, the posterior cerebral artery location was clear but the pathophysiology was not. The subsequent imaging studies clearly indicated a small infarct involving the calcarine artery territory. Whether the previous sensory findings indicated some involvement of the posterior cerebral penetrating supply to the ventral posterior lateral nucleus of the thalamus remains unclear. The decreased flow in the right posterior cerebral artery was clearly demonstrated. In general as with the middle cerebral artery, cortical infarcts of the posterior cerebral artery territory, in the Caucasian population are almost always embolic. In this case the patient had two possible sources for emboli and was placed on long term anticoagulation.

The following case 26-6 presented at the onset with a transient bilateral posterior cerebral ischemia but with more severe residual symptoms reflecting unilateral posterior cerebral disease.

Case 26-6. This 75-year-old, white, right-handed widow developed sudden headache on the day prior to admission, with nausea, vomiting, and a poorly described bilateral disturbance of vision. She was found by a relative the morning of admission complaining of total blindness and of severe headache. She was noted to be confused and incoherent (believed she was in New Jersey rather than Massachusetts). She was able to walk only with assistance.

Past history: A minor degree of hypertension had been noted several days prior to admission.

Physical examination: The patient was an obese female with blood pressure elevated to 170/100. She was holding her head complaining of headache.

Neurological examination:

1. Mental status:
 - a. The patient was restless and disoriented for time and place.
 - b. There were difficulties in cooperation so that detailed testing of mental status could not be performed.
 - c. Simple calculations were poorly performed.
 - d. Digit span was markedly limited.
 - e. There was no left-right confusion and no evidence of aphasia.
2. Cranial nerves:
 - a. Initially the patient was unable to detect objects (e.g., a face or lights) in either visual field. Within six hours, a change had occurred. Although conjugate extraocular movements were full, the patient tended to keep her eye deviated to the right and failed to follow objects introduced from the periphery of the left visual field. The eyes could be deviated to the left on command.
 - b. The pupils responded to light.
3. Motor system:
 - a. Strength was grossly intact.

- b. A slight unsteadiness (ataxia) of gait was present.
- 4. Reflexes:
 - a. Deep tendon reflexes were grossly symmetrical.
 - b. A Babinski response was present on the left; a probable Babinski sign was also present on the right.
- 5. *Sensory system*: All modalities were intact.

Clinical diagnosis: Ischemia bilateral posterior cerebral arteries, cortical branches, probably embolic.

Laboratory data:

1. *Hematocrit* was normal. *Total cholesterol* was elevated to 312 mg./100 ml. The *glucose tolerance test* was consistent with diabetes mellitus.
2. Chest and skull x-rays and the electrocardiogram were normal.
3. The *electroencephalogram* demonstrated focal 3 to 4 cps slow waves in the right posterior parietal occipital area with rare slow waves in the right posterior temporal area consistent with focal damage in this area.
4. *Lumbar puncture* indicated clear spinal fluid with no cells and a normal protein of 18 mg./ml.

Hospital course: The patient had a significant improvement in headache and a clearing of confusion with a return of mental status to her normal level. Her hospital stay was prolonged by the development of thrombophlebitis of the left femoral vein. At the time of hospital discharge, one month after admission, there was still a residual left field defect (homonymous hemianopsia) with preservation of vision in the macular area (macular sparing). Follow-up evaluation approximately 14 months after discharge indicated no significant neurological findings except for the residual left field defect (homonymous hemianopsia with macular sparing) (Fig. 23-16).

Comment: The initial symptom of total blindness suggested bilateral posterior cerebral ischemia. The development of confusion and disorientation is also consistent with bilateral posterior cerebral ischemia. The nausea, vomiting, and minor ataxia of gait may well have indicated ischemia of the brain stem, suggesting that the basic occlusive process may have originated at a lower point in the basilar artery. The residual and most severe degree of involvement was certainly within the territory of the right calcarine artery.

The occurrence of severe headache is not usually considered in connection with ischemic-occlusive disease. A review of our cases of posterior cerebral occlusion indicates that the occurrence of severe headache is often a prominent symptom. Often in these cases prior to lumbar puncture, the diagnosis of subarachnoid hemorrhage was considered.

At the present time evaluation would include a CT or MRI scan. Other examples of posterior cerebral artery cortical infarcts are presented in the visual system chapter with appropriate CT scans.

The following case 26-7 provides an example of an intracerebral hematoma of unknown etiology in a young patient.

Case History 26-7. This 33-year-old white, right-handed, male linotype operator, at approximately 8:30 p.m. had the sudden onset of numbness of the left side of his mouth. At 10:30 p.m. he developed a severe right frontal headache and noted sudden onset of numbness of the left upper extremity which rapidly spread to involve the entire left side. Marked weakness of the left arm and leg developed. Evaluation that evening at his local community hospital indicated a dense left homonymous hemianopia, a marked left central facial weakness, an absence of any voluntary movement of the left arm and leg and no awareness of painful stimulation of the entire left side. A left Babinski sign was present. Lumbar puncture revealed opening pressure elevated to 235 mm. of water; and 50 fresh red blood cells per cubic mm. The patient was subsequently transferred to the neurosurgical service at New England Center Hospital.

Past history: There were no remarkable features as regards hypertension, renal disease, or diabetes mellitus. No history of drug use was obtained.

Physical examination: The patient was moderately obese with a normal blood pressure of 110/85. Examination of the heart revealed no abnormalities. No rigidity of the neck was present. There were no murmurs over the cranium.

Neurological examination:

1. **Mental status:** Orientation, speech and the ability to provide a coherent history were all intact.
 2. **Cranial nerves:**
 - a. Examination of the fundi showed no hemorrhage or papilledema.
 - b. A dense left homonymous hemianopsia was present.
 - c. Sensation was defective on the left side of the face, as well as the left side of the body.
 - d. A left central facial weakness was present.
 - e. The tongue deviated to the left.
 3. **Motor system:**
 - a. A dense flaccid paralysis of the left arm and leg was present.
 - b. There was no resistance to passive motion in the left arm and leg.
and little in the left lower extremity (that is, a flaccid paralysis was present).
 - c. Cerebellar tests were negative.
 4. **Reflexes:**
 - a. Deep tendon reflexes were absent in the left upper extremity but increased in the left lower extremity
 - b. A Babinski sign was present on the left. The plantar on the right was flexor.
 - c. No grasp reflexes were present.
 5. **Sensation:**
 - a. There was no perception of pinprick or of tactile stimulus on the entire left side of the body.
 - b. Position and vibratory sensation were absent on the on the left.
- Clinical diagnosis:** Intracerebral hematoma right putamen-thalamus or embolus stem of MCA with hemorrhagic transformation.

Laboratory data:

1. Hematocrit, white blood count, and differential were all within normal limits. Sedimentation rate was normal.
2. *Tests of bleeding time, clotting time, and prothrombin time* were all within normal limits.
4. *Skull x-rays* revealed a shift of the pineal, 7 mm. from right to left.
5. *Electroencephalogram* revealed frequent focal 4 to 5 cps slow waves in the right hemisphere most prominent in the frontal and parietal areas consistent with focal damage in these areas.
6. *Arteriograms* (right common carotid) revealed a 12 mm. shift of the pericallosal branch of the anterior cerebral artery. The internal cerebral vein was also shifted 8 mm. from right to left. The middle cerebral branches emerging through the sylvian fissure were depressed. There was no evidence of an abnormal arteriovenous shunt or of an aneurysm. Cortical vessels and veins in the suprasylvian area were stretched over relatively avascular areas. The conclusion was a space-occupying mass in the right posterior frontal parietal area consistent with an intracerebral hematoma.

Subsequent course:

On the day of admission, the patient was taken to the operating room. A right parietal burr hole was made. The underlying cortex was noted by the neurosurgeon, Dr. Robert Yuan, to bulge prominently. A needle was inserted to a depth of 1 cm. into the cortex where 25 cc. of old, dark red blood under pressure was expelled. Free drainage of blood continued through a catheter which remained in place for 2 days.

Return of voluntary movement in the left lower extremity at the hip and knee was noted on the day following surgery. Reevaluation of neurological status 2 weeks after surgery, revealed continued improvement. The left homonymous hemianopsia was no longer present but the patient did have some difficulty in reading (losing the left half of the line of print). A left central facial weakness was present; voluntary hand-foot movements on the left were still not possible. Proximal muscle groups (shoulder, hip, knee) had returned to 60 per cent of normal strength. Deep tendon reflexes were now hyperactive in the upper and lower left extremities with a left Babinski sign. A dense

sensory deficit remained on the left side with no perception of pain, touch, vibration, and position in the upper and lower extremities. Reevaluation 4 weeks after surgery, revealed a return of pain and temperature sensation but continued deficits in proprioception. Reevaluation by Dr. Yuan 4 months after surgery, indicated a return of strength in the left hand with a strong grip. The gait was typical of a spastic hemiplegia. Reflexes were unchanged. Sensory examination revealed a return of primary modalities such as vibration and pain, but marked errors in cortical modalities, such as position sense, were made. Follow-up 7 months after surgery indicated an excellent return of strength on the left side but continued incoordination in the left hand due to deficits in proprioception.

Comment:

This patient from several standpoints presents a number of unusual features not seen in the typical case of intracerebral hemorrhage. The patient was relatively young (33 years old) and had no history of hypertension. He had none of those conditions such as leukemia, bleeding disorders, and the like which predispose to intracerebral hemorrhage. The arteriogram provided no evidence of an intrinsic or a secondary metastatic brain tumor. Moreover, histological examination of the tissue and drainage material obtained at the time of surgery failed to reveal tumor cells. No aneurysm was demonstrated on angiography. Although no arteriovenous malformation was demonstrated at the time of arteriography, such a malformation may have been present previously but destroyed in the process of hemorrhage. The significance of the minor prodromal sensation of numbness of the face remains uncertain. This may have reflected an initial small area of ischemia with secondary hemorrhage.

Where was the initial site of hemorrhage? In this case, the hemorrhage apparently originated in the subcortical white matter of the parietal lobe presenting as a lobar hemorrhage. The pattern of initial evolution of symptoms and the final pattern of sensory deficit is perhaps more consistent with such a parietal lobe location. From the prognostic standpoint, he did not lapse into coma and did not have compromise of brain stem functions as so often occurs when there is tentorial herniation or an extension of the hemorrhage into the ventricular system. That these various events did not occur, may in part relate to the drainage of the hematoma by the neurosurgeon with removal of this supratentorial mass lesion. The management of intracerebral hemorrhages is discussed in greater detail by Ojemann and Heros, (1983).

The following three cases provide examples of subarachnoid hemorrhage from aneurysms at the three major sites: posterior communicating-internal carotid (Case 26-8), middle cerebral bifurcation (Case 26-9) and anterior communicating –anterior cerebral junction (Case 26-10)

Posterior communicating- internal carotid junction.(Figs. 26-24)

Case 26-8: This 66-year-old white housewife, five days prior to admission, had the sudden onset of a severe bicipital bifrontal headache associated with vomiting. The headache was constantly present for 3 days but was increased by coughing. At the same time, she noted an alteration of vision in the right eye. She noted also a drooping of the right eyelid. The headache subsided, only to recur one night prior to admission as a severe occipital headache associated with vomiting. There was no past history of hypertension. The patient was admitted to her community hospital. A lumbar puncture revealed the presence of subarachnoid blood and the patient was transferred to the neurology/neurosurgical services of the New England Medical Center on 10/2/66.

General physical examination: The patient was an obese female with blood pressure of 140/80 and complaints of severe headache. Her temperature was normal.

Neurological examination:

1. *Mental status:* The patient was alert with mental status intact.
2. Cranial nerves:
 - a. Fundus: Blurred discs were present bilaterally, being greater on the right. No venous pulsations were present on the right.
 - b. Nerve III: The right pupil measured 4 mm. and was not reactive to light on direct or consensual stimulation.. The left pupil measured 2mm and was reactive to light. Ptosis of the right eyelid was present. At rest on forward gaze, there was outward deviation of the right eye. The patient was unable to adduct the right eye on left lateral gaze and failed to move this eye on upward or downward gaze. Other extraocular movements were intact.

c. Nerve VII: Minimal flattening of the right nasal labial fold was present.

3. *Motor system*: Strength, coordination, and gait were intact.
4. *Reflexes*: Deep tendon: A minimal relative increase was present on the right. Plantar responses: The left was flexor, the right was equivocal.
5. *Sensation*: All modalities were intact.
6. *Neck*: Mild nuchal rigidity was present (resistant to passive flexion of head onto chest).
Clinical diagnosis: Subarachnoid hemorrhage due to an aneurysm at the posterior communicating–internal carotid junction.

Laboratory data:

1. Skull and chest x-rays were normal.
2. Studies of bleeding time, clotting time, and prothrombin time were all within normal limits.
3. *Arteriograms* revealed an aneurysm of the right internal carotid artery just below its junction with the posterior communicating artery. There was no left-to-right flow through the anterior communicating artery. There was narrowing of the anterior cerebral arteries near their origin bilaterally. This suggested to the radiologist the possibility of vasospasm, secondary to the presence of subarachnoid blood.

Hospital course:

Because the history suggested several episodes of bleeding, surgical therapy was selected. A right temporal craniotomy was performed by Dr. Robert Yuan with clipping of the neck of the aneurysm. The temporal lobe was retracted revealing a 13 mm.-long saccular aneurysm, arising from the internal carotid artery close to the junction with the posterior communicating artery. Distally the aneurysm enlarged into a large sac which was hidden behind the oculomotor nerve. This nerve was bulging at the point where the aneurysm, which was clipped, was well formed. The more distal sac of the aneurysm was thin and showed signs of previous rupture with yellow staining of the adjacent meninges. The sac of the aneurysm was covered with Gelfoam. Postoperatively, significant deficits as compared to the preoperative neurological status were evident. The level of consciousness waxed and waned with periods of alertness alternating with periods of apathy and drowsiness. Twenty days after surgery, she was described as sitting with both eyes closed, continuously grasping and palpating the arm of the chair with the right hand, less frequently with the left. There was a marked bilateral release of an instinctive grasp reflex. There was increased resistance in both upper extremities, at times described as plastic rigidity, at times as the “Gegenhalten,” associated with bilateral frontal lobe disease. No spontaneous voluntary movements of the left leg occurred. Bilateral Babinski signs were present. A bilateral resting tremor of the hands and of the head was also present. At times inappropriate jocularity was present. All of these findings suggested a bilateral front lobe syndrome with infarction in the territory of the anterior cerebral arteries and additional involvement of the basal ganglia. The complete paralysis of the right third nerve remained at preoperative level. At the time of hospital discharge, one month after surgery, the frontal lobe findings and the weakness in the left leg remained prominent.

Comment:

The presence of severe headache in association with a mild degree of nuchal rigidity suggests meningeal irritation. Such irritation could indicate a subarachnoid hemorrhage or a meningitis (inflammation of the meninges due to bacterial or viral infection). The sudden onset of the headache is more consistent with a subarachnoid hemorrhage. The lack of fever and of accompanying or prodromal systemic findings is also against the diagnosis of meningitis. Finally, the clearly focal third nerve findings are more in favor of the diagnosis of subarachnoid hemorrhage (although focal or multifocal neurological findings may develop as complications of a bacterial meningitis).

In this case, the significant findings on neurological examination related to the right third cranial nerve. The third cranial nerve is particularly subject to compression by aneurysms of the posterior communicating artery because having emerged from the midbrain it pursues an anterior course towards the cavernous sinus in a close parallel relationship to the posterior communicating artery. In general, compressive lesions of the third nerve produce initially an alteration in pupillary constrictor functions, then involvement of the levator palpebrae and finally involvement of the superior, medial and inferior

rectus, and inferior oblique muscles. The initial alteration in vision in the right eye and ptosis of the right eyelid at the onset of headache are then consistent with a compressive lesion. The patient at the onset of symptoms did not report a diplopia.

The third nerve as it emerges from the midbrain also passes in close relationship to the posterior cerebral and superior cerebellar arteries, but aneurysms of these vessels are much less common than those which occur in relation to the posterior communicating artery and internal carotid artery.

These findings with extrinsic compressive disease of the third nerve are to be contrasted with the pattern of intrinsic brain stem involvement of the third nerve nucleus where medial rectus or superior rectus function is more likely to be initially compromised.

The patient had minimal findings suggesting involvement of the left corticospinal and corticobulbar tracts: minimal right central facial weakness, minimal increase in deep tendon reflexes on the right side, and an equivocal right plantar response. The findings may have been produced by a slight shift of the brain stem to the left due to the small mass of aneurysm on the right side of brain stem. With such a shift, compression of the left cerebral peduncle against the tentorium might occur. In any case, these findings were minimal. The significant findings in this case clearly related to the third cranial nerve and it is these findings which allowed localization of the lesion prior to arteriography.

As regards the postoperative course, it is evident that this patient had severe involvement of the frontal lobes presumably as a result of bilateral infarction within the territory of the anterior cerebral arteries. In retrospect, the narrowing of the anterior cerebral arteries at their origin, presumed secondary to "spasm" noted at the time of arteriography, may have provided a clue as to the development of the complication. The neurosurgeon, faced with the decision as to the best time to intervene, would prefer as the ideal situation, the moment when arterial spasm has not yet developed or is no longer present but bleeding has not yet recurred. In reality the risk of recurrent hemorrhage is so great that the aneurysm should be clipped as soon as possible for example the day of presentation. Vasospasm can now be treated with calcium channel blockers and after clipping by increasing the blood pressure to increase perfusion. The typical angiographic appearance of aneurysms in this location is demonstrated in Figure 26-24. Occasionally large aneurysms can be demonstrated on the CT scan.

Middle cerebral bifurcation (Fig 26-25).

Case 26-9: This 46-year-old, right-handed, white, married male, was admitted to the neurology/neurosurgical services of the New England Medical Center on 6/10/66. He presented a history that 10 days prior to admission, he had the sudden onset of a severe, throbbing, supraorbital and vertex headache. The headache began while the patient was in bed in the early stages of sexual intercourse. The patient noted no weakness except that his tongue "felt funny" in articulation for approximately one minute. There was a transient difficulty in speech during this period.

Past history: Mild hypertension had been present.

General physical examination: Blood pressure was 160/100.

Neurological examination:

1. *Mental status* was intact.
2. *Cranial nerves* were intact.
3. *Motor system* was intact.
4. *Reflexes* were physiologic
5. *Sensory system* was intact.
6. Headache could be precipitated by *head movement*.
7. With *cervical flexion*, pain occurred in the neck and lumbar area occurred.

Laboratory data:

1. Skull and chest x-rays were normal.
2. *Electroencephalogram* revealed focal damage in the lateral aspect of the left hemisphere (focal 3 to 5 cps slow waves).
3. *Lumbar puncture* on the day following admission revealed opening pressure elevated to 270 mm. of water and closing pressure to 210 mm. of csf. The fluid was xanthochromic (yellow discoloration). In addition 38 fresh red blood cells per cubic mm. were present. Protein was elevated to 80 mg./100 ml. Hinton was negative.

4. *Arteriography* revealed a bilobed aneurysm at the trifurcation of the left middle cerebral artery measuring 8 x 4 mm. Spasm and narrowing of the proximal anterior and middle cerebral arteries were noted.

Hospital course:

On the day following admission, the patient complained of a few-minute episodes of numbness in the right face, tongue, and right upper extremity with thickness of speech. Examination now revealed right central facial weakness and slight slurring of speech. The patient also now complained of additional neck pain on extreme forward flexion. On June 12, 1966, the patient had another short episode beginning with numbness over the right thumb, spreading to the right hand and then to the angle of the mouth.

Because of the several episodes which occurred, following hospital admission, involving the right face, tongue, and hand in association with the finding of fresh red blood cells in the spinal fluid, it was considered likely that bleeding from the aneurysm was continuing to occur. Surgical therapy was therefore considered necessary to prevent additional (and possibly fatal) subarachnoid hemorrhage. On May 20, 1966 a left frontotemporal craniotomy was performed by Dr. Robert Yuan with subsequent plastic coating of the entire aneurysm to reinforce its wall. There was evidence of recent hemorrhage in the subarachnoid space with yellow discoloration of the meninges. In order to expose the aneurysm, it was necessary to remove the anterior tip of the temporal lobe back to a distance of 2.5 cm. There was a small amount (5 to 10 cc.) of intracerebral blood clot in the superior temporal region close to the aneurysm. The aneurysm itself had no actual neck that could be clipped. Several middle cerebral branches appeared to arise from the dome or lateral wall of the aneurysm.

In the postoperative period, the patient initially did well. A minor expressive aphasia was present, but the patient was alert and well oriented. However, fever and jaundice developed. With the development of significant alterations of liver functions approximately 7 days after surgery, the patient became confused and agitated. The prothrombin time fell to 3 per cent of normal and there was evidence of bleeding into the gastrointestinal tract at this time. The prothrombin deficit was corrected by administration of vitamin K. It was unclear, however, as to whether any minor intracranial bleeding occurred during this time. Some improvement in liver functions occurred, and the patient became more alert but continued to manifest inappropriate behavior, emotional lability, and disturbance of memory. He left the hospital against medical advice one month after surgery, on July 20, 1966.

The patient was readmitted to the hospital approximately one month later on August 13, 1966. For two days, the patient had been less active, appeared confused, glassy eyed, and failed to communicate. The degree of obtundation cleared when adequate dosage of the anticonvulsant medication, Dilantin, was administered. This fact taken on conjunction with the electroencephalogram, which demonstrated frequent focal spikes (excessive neuronal discharge) in the left temporal area (Fig. 29-1C) led to the conclusion that the episode which precipitated his readmission might well have represented a prolonged seizure discharge. The electroencephalogram also demonstrated an increase in slow wave activity in the left hemisphere, particularly the left temporal area indicating a possible increase in damage in the left temporal area. This appeared to be correlated with apparent progression of the patient's aphasia which was now receptive as well as expressive in nature. At the time of discharge, a severe expressive aphasia was still present.

Comment:

The sudden onset of severe headache during exercise or exertion (sexual intercourse in this case) is characteristic of subarachnoid hemorrhage. The location of the aneurysm was suggested by the symptoms relevant to the tongue and speech during the initial episode. The episode on June 11, 1966, involving numbness of the right face, tongue, and right upper extremity, could only indicate disease within the territory of the left middle cerebral artery. The lumbar puncture at this time indicated not only evidence of the initial leakage of blood 10 days prior to admission (an elevation of cerebrospinal fluid protein and a xanthochromia), but also fresh red blood cells suggesting that additional leakage of blood had occurred.

The nature of the episodes which occurred on June 11 and 12 is not certain. Most likely these were ischemic in nature related to decrease in blood flow as a result of clot formation within the aneurysm or from spasm of the adjacent portion of the middle cerebral artery. At times, however, symptoms such as rapidly spreading numbness occurring in episodes may suggest focal epileptic discharge. The development of an area of excessive discharge would not be unusual since this aneurysm involves those

middle cerebral artery branches which are supplying the cerebral cortex. In addition hemorrhage within the Sylvian fissure is likely to damage the surrounding cerebral cortex. Blood and iron are epileptogenic.

The patient's course following surgery was complicated by the development of severe liver dysfunction. The etiology of this problem was never clear, the various studies suggesting either a toxic hepatitis related to various drugs and anesthetic agents or a variety of obstructive jaundice. What the patient's eventual recovery would have been had this problem not developed is uncertain. It is clear, however, that during this post-

operative period the patient did develop significant impairment of language functions, possibly related to infarction or oozing of blood in areas supplied by the middle cerebral artery. It is also evident that a seizure focus had developed in this area. Such seizure foci may have developed in relation to the preoperative hematoma noted in the temporal lobe, in relation to the surgical manipulation of the area, or in relation to the postoperative complications.

Today (2002), the history presented by this patient would have prompted an immediate CT scan and a lumbar puncture if the CT scan were negative. An arteriogram would have been performed immediately after these studies. Surgery would have been performed immediately after the evaluation of the angiographic studies to prevent the recurrent episodes of bleeding.

Anterior communicating -anterior cerebral junction(Figs. 24-26, 24-27, 24-28)

Case History 26-10. . (Patient of Dr. John Sullivan). This 49-year-old, right-handed truck driver was transferred from his local community hospital for evaluation of subarachnoid hemorrhage.

The patient had experienced occasional frontal headaches for the previous 5 years. In June, 1965, while changing a tire, he had a severe throbbing frontal headache which cleared after thirty minutes. Since that time he had experienced daily throbbing frontal headaches, usually present on arising in the morning. On September 4, 1965, the patient had the onset of a particularly severe headache which began while he was engaged in heavy work on a boat. There was associated stiffness of the neck, nausea, vomiting, and a general sensation of weakness.

Evaluation at his local community hospital revealed papilledema (blurred optic disk margins on funduscopic examination). Nuchal rigidity was present. The lumbar puncture demonstrated grossly bloody cerebrospinal fluid. He was subsequently transferred to the neurology/neurosurgical services of the New England Medical Center on 9/7/65.

Past history:

1. Hypertension had been noted in June, 1965.
2. The patient's father had died at age 59 of a cerebrovascular accident.

General physical examination:

1. Blood pressure was moderately elevated to 180/100. Pulse was 60.
2. No bruits (murmurs) were present over the skull.
3. A significant degree of nuchal rigidity was present. The neck could not be actively or passively flexed.

Neurological examination:

1. Mental status:
 - a. The patient was somnolent but could be aroused, although attention span was noted to be shortened.
 - b. He was oriented for place and situation but confused as to time.
 - c. Digit span was shortened to 5 forward and 4 in reverse.
 - d. The patient was unable to do calculations.
2. Cranial nerves:
 - a. Sense of smell was decreased on the right side.
 - b. Disk margins were indistinct on examination of the fundus. Arterioles were tortuous and irregular.
3. Motor system:
 - a. Strength and tone were intact.
 - b. Cerebellar tests were normal.
4. Reflexes:
 - a. Deep tendon reflexes were symmetrical.

- b. Plantar responses were flexor.
- 5. Sensory system: All modalities were intact.

Laboratory data:

1. Bleeding, clotting, and prothrombin times were all normal. Platelets were normal on smear.
2. Chest and skull x-rays were normal.
3. *Arteriograms* demonstrated an aneurysm of the anterior communicating artery which extended posteriorly and to the right. The aneurysm filled from the left carotid circulation.

Hospital course: During the evening of September 11, 1965, the patient became lethargic and would not speak or obey commands. Blood pressure rose to 240 mm. systolic. The patient became totally unresponsive with pupils fixed and dilated and with incontinence of urine. Deep tendon reflexes were exaggerated with plantar responses extensor. Within minutes, the patient became responsive again; pupils were reactive, although the right remained sluggish. The patient made purposive movements and obeyed commands. Lumbar puncture subsequently indicated grossly bloody spinal fluid. The patient remained confused and less alert with a tendency to fall asleep.

On September 17, 1965, the patient again suddenly complained of violent headache and lost consciousness for approximately 30 minutes. The right pupil became dilated, and the right eye deviated to the right suggesting a right medial rectus weakness. The blood pressure again rose to 240/140. As previously, the patient regained consciousness. Although confused, he had no clearly lateralizing signs. Subsequent lumbar puncture again revealed the presence of fresh red blood cells.

Because repeated episodes of bleeding had occurred, surgical therapy was undertaken. On September 21, 1965 a left frontal craniotomy was performed by Dr. Robert Yuan. The left frontal pole was resected exposing the left anterior cerebral artery and the aneurysm which arose from the anterior communicating artery. The medial surface of the right frontal lobe was cystic and contained 20 cc. of hematoma. The hematoma was evacuated. The aneurysm was reinforced by spraying with a plastic coating.

Neurological examination approximately 1 week after surgery indicated that the patient was confused and disoriented, with a "rather negative response" refusing to follow directions and to speak to examiners. Blood pressure was noted to be extremely labile with a drop of 50 mm. of mercury systolic when the patient moved from prone to sitting position. Equivocal Babinski signs were present, and the patient was incontinent of urine and feces.

Reevaluation on November 17, 1965, approximately two months after surgery, indicated that although the patient was ambulatory and able to take care of his daily needs, he remained confused for time and place. When the patient was examined 6 months after surgery, confusion was no longer present; intellectual functions were consistent with his education.

Approximately 2 years after surgery, the patient, who had recently been married, reported that he was impotent, unable to obtain an erection.

Comment:

In this case, the history of sudden onset of severe headache and stiffness of the neck, precipitated by exertion, clearly suggested a subarachnoid hemorrhage originating from the rupture of an intracranial aneurysm. It is likely that several episodes of subarachnoid bleeding occurred in June and September of 1965. While the clinical findings of somnolence and confusion with a decrease in olfaction on the right may have suggested the possibility of an anterior communicating-artery location, these were certainly not firm diagnostic clues. The episodes characterized by sudden alteration in blood pressure, while nonspecific, might have raised the question of orbital-frontal, anterior cingulate, or hypothalamic effects (areas within the distribution of the anterior-cerebral arteries).

The negativity of the patient following surgery undoubtedly indicated preoperative and operative damage to the orbital and prefrontal areas. The bilateral Babinski signs and the incontinence of urine and feces in the postoperative period probably reflected damage to the parasagittal motor and premotor areas within the distribution of the anterior cerebral arteries. The impotence may have reflected damage at the frontal or hypothalamic level.

Today, an initial episode such as occurred in June 1965 would have prompted a CT scan and a lumbar puncture if that study had been negative. Of course many exertional headaches are not a result of

subarachnoid hemorrhage. Nevertheless the more serious entity must be ruled out at the emergency room level, since the mortality and morbidity of the frequent recurrent hemorrhage are so high. Again the use of early arteriography and early surgery are to be emphasized.

Case 26-11 illustrates many of the neurologic aspects of bacterial endocarditis.

Case 26-11: This 34-year old right hand married white male hair dresser was admitted with a one month history of night sweats, fever to 102-103° F., generalized aches and pains. Within the previous 3-4 months, the patient had undergone repeated dental procedures for dental infection. He had been reported to have a mild heart murmur 2-3 years prior to admission. His urine had recently become dark. The day prior to admission he had noted a small hemorrhagic lesion on the dorsum of his left hand.

Physical exam:

1) Skin: A small indurated red lesion dorsum left hand and a small red lesion under the nail bed 3rd left toe.

2) Heart: A grade IV/VI high-pitched holosystolic murmur was present at the apex; and a high-pitched II/VI murmur at the base; both not previously noted to this degree.

3) Temperature was elevated to 101° F

Neurological examination: Entirely within normal limits.

Clinical diagnosis: Bacterial endocarditis with systemic emboli but without neurological symptoms at this point.

Laboratory data:

1) **CBC:** Anemia with hematocrit 31 and hemoglobin of 10.1.
White blood count was 9900 with differential of 78% poly-morphonuclears and 9 atypical lymphocytes.

2) Sedimentation rate was elevated to 38 mm.

3) **Urinalysis** indicated 8-10 red blood cells per high power field.

4) All three **blood cultures** drawn on the day of admission produced growth of streptococcus viridans (alpha hemolytic).

5) **Echocardiogram** indicated a prolapsed mitral valve with probable mitral insufficiency. In addition, irregular densities on the mitral leaflets suggested vegetations.

Hospital course: All of these findings were consistent with a diagnosis of subacute bacterial endocarditis with evidence of microemboli to extremities (skin lesions) and to kidneys (hematuria). The patient was begun on high dosage intravenous penicillin (24 million units per day) with an excellent response as regards fever and general symptoms. Thirteen days after admission he again developed a temperature elevation. The following day, at 2 p.m., he abruptly developed difficulty with speech and a right hemiplegia. Over the next 2 hours this rapidly evolved to the following neurological state.

Neurological examination:

1) Mental Status and Language Function

a) The patient was drowsy - holding the left side of his head as though in pain.

b) He was mute.

c) He was unable to carry out any spoken or written commands.

2) Cranial Nerves

a) The patient neglected the right visual field and had no response to threat in the field.

b) The fundusoscopic exam indicated blurring of the disc margins on the left.

c) Right central facial weakness was present.

d) Pain sensation was decreased on the right side of the face.

3) **Motor System:** A flaccid right hemiparesis was present although some purposive withdrawal of the right arm and leg occurred on painful stimulation.

4) Reflexes

a) Deep tendon reflexes were increased bilaterally but right were greater than left with clonus of the right ankle.

- b) The right plantar response was extensor, the left flexor.
 - 5) *Sensation*: A right-sided hypalgesia was present. Other modalities could not be tested.
 - 6) Neck and Skin
 - a) No nuchal rigidity was present.
 - b) New splinter hemorrhages were present under the nails of the upper extremities.
- Neurological diagnosis:** Cerebral embolus left middle cerebral artery, with possible mycotic aneurysm and possible hematoma left middle cerebral artery secondary to bacterial endocarditis.

Laboratory data:

An immediate CT Scan (Fig. 26-30) demonstrated a large intracerebral hematoma involving the left basal ganglia and insula with massive shift of the left hemisphere to the right.

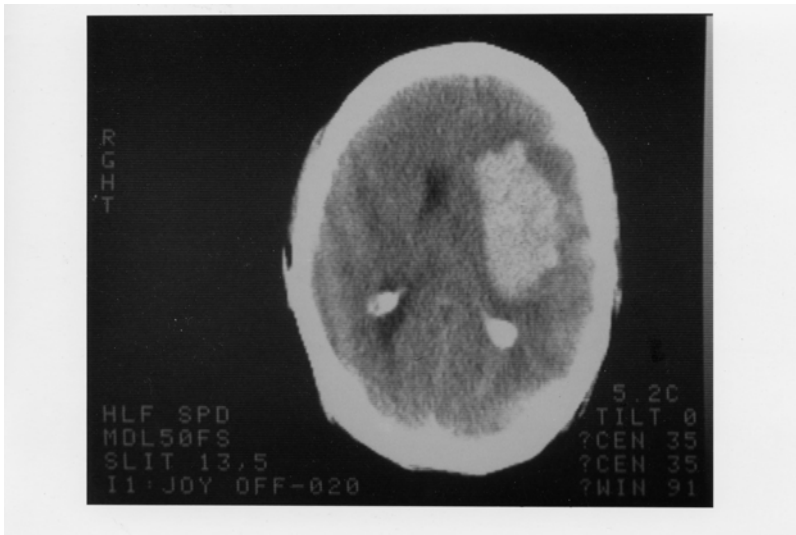
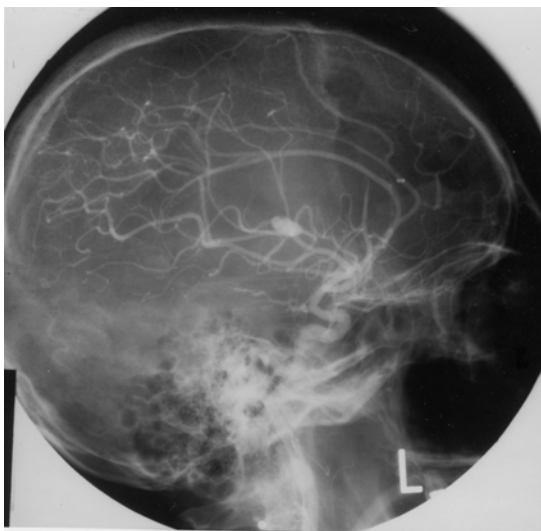


Figure 26-30.

2. An immediate arteriogram: (Fig. 26-31A) demonstrated a small aneurysm (arrow) arising from a small branch of the left middle cerebral artery (MCA) within the Sylvian fissure. A large avascular area surrounded this aneurysm with upward and lateral displacement of anterior cerebral arteries, medial displacement of lenticular striate, branches of the MCA and lateral and downward placement of the cortical MCA branches.



Subsequent course: That evening Dr. Robert Johnson removed a large intracerebral clot. Over the next 2 weeks the patient began to have some improvement in his right hemiparesis and aphasia. However two weeks after surgery, he developed right-sided focal status epilepticus. The patient had been receiving Phenytoin (Dilantin) but the level was low. Intravenous Phenytoin, intravenous Dexamethasone and Mannitol were administered. The CT scan now demonstrated a larger hemorrhage surrounded by edema. The patient was taken to surgery and additional old clot and a small amount of recent clots were removed. The patient failed to respond. He developed fixed dilated pupils and bilateral Babinski signs. The arteriogram (Fig.26-31 B,C) was repeated and now demonstrated a much larger aneurysm (measuring 11 mm vs 4-5 mm in previous films). There was also evidence of additional shifts of the anterior cerebral artery and internal cerebral vein. Anterior-frontal branches of the middle cerebral artery were occluded. Regression occurred and 8 days later patient met brain death criteria with absence of all brainstem reflexes, no spontaneous respirations and an absence of all cerebral electrical activity (silent EEG).

Comment: This patient presents a panorama of almost all of the cerebral complications of bacterial endocarditis including:

- a) Multiple septic emboli to brain, kidney, and small peripheral arteries;
- b) Mycotic aneurysm;
- c) Intracerebral hematoma
- d) Eventual mortality.

The mycotic aneurysm with eventual rupture was not a feature noted on presentation but instead was a late complication. (A silent unruptured aneurysm may well have been present on admission.) This subacute delayed presentation is more common in streptococcal endocarditis as opposed to the more virulent staphylococcal infections where acute intracranial presentations are the rule.

In this case, the aneurysm when initially discovered was small and associated with an intracerebral hemorrhage.

The aneurysm continued to enlarge after evacuation of the initial hematoma and eventually additional hemorrhage occurred. Not all patients with mycotic aneurysm will have intracranial hemorrhage. In the series of Brust et al (1990), 41% were associated with rupture. Of 20 aneurysms followed with angiography or CT scan, ten became smaller or disappeared, 10 remained unchanged or enlarged despite an adequate treatment course with antibiotics. In the present case, initial rupture occurred almost 2 weeks after admission and beginning of antibiotic treatment.

The recommended approach in patients with endocarditis to avoid the fatal complications of mycotic aneurysm rupture is to perform 4 vessel angiography in those patients with endocarditis who develop neurological symptoms. If a mycotic aneurysm is found, prompt surgical treatment (clipping) should be performed. Unfortunately many patients with mycotic aneurysms have no neurological symptoms prior to rupture. To perform angiography in all patients with bacterial endocarditis, would not be practical and would fail to detect aneurysms that developed after the studies. However, when long-term anticoagulation is planned in patients on the completion of antibiotic treatment to prevent additional emboli, angiography should be performed or repeated. The entire role of anticoagulation in bacterial endocarditis remains unclear. (See Salgade et.al 1987 and Hart et.al 1987, 1990). MRI may have an increasing role in non-invasive diagnosis, since MRI angiography should be able to detect aneurysms greater than 2-3 mm in diameter

Figure 26-32. Arteriovenous malformation in the right parietal area demonstrating the abnormal tangle of vessels and infarction of the surrounding cerebral cortex and white matter.

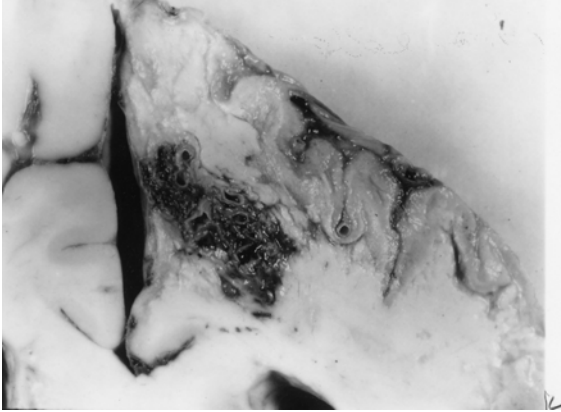


Figure 26-32. In this case, the malformation was fed mainly by the right anterior cerebral artery and drained into the superior sagittal sinus. This 46-year-old woman had, as a primary problem, subarachnoid hemorrhage from an anterior-communicating saccular aneurysm, with other unruptured aneurysms at left posterior communicating, and right superior cerebellar. (Courtesy of Dr. John Hills).

Case history 26-12 provides an example of a long-term unruptured arteriovenous malformation presenting as a seizure disorder.

Case 26-12: This 51-year old right-handed female experienced two nocturnal generalized convulsive seizures 6 years prior to evaluation . Evaluation by Dr. Robert Bazemore at that time revealed a significant 30-year history of minor episodes: “little sensations”. The patient described sudden strange feelings as though moving in slow motion. With other episodes she would feel at a distance from her surroundings with a sense of detachment at times with a strange odd smell. After 2-3 minutes the “spell” would alter, she would feel depressed with a sense of terrible fear. The patient also had a long history of migraine headaches (bilateral throbbing) which were often preceded by visual auras more prominent in the right visual field. The neurological examination was normal. She was treated with anticonvulsant (Phenytoin). When seen by the author for other unrelated neurological problems 6 years later , the interval history indicated no additional generalized seizures but complex partial seizures had continued.

Neurological examination: entirely within normal limits.

Clinical diagnosis : Simple and complex partial seizures of temporal lobe origin .

Laboratory data:

1. The *CT scan without enhancement* now demonstrated a calcified lesion in the anterior-medial right temporal lobe which enhanced with contrast (Fig. 26-32A). Large early draining veins were also noted (Fig. 26-32B).

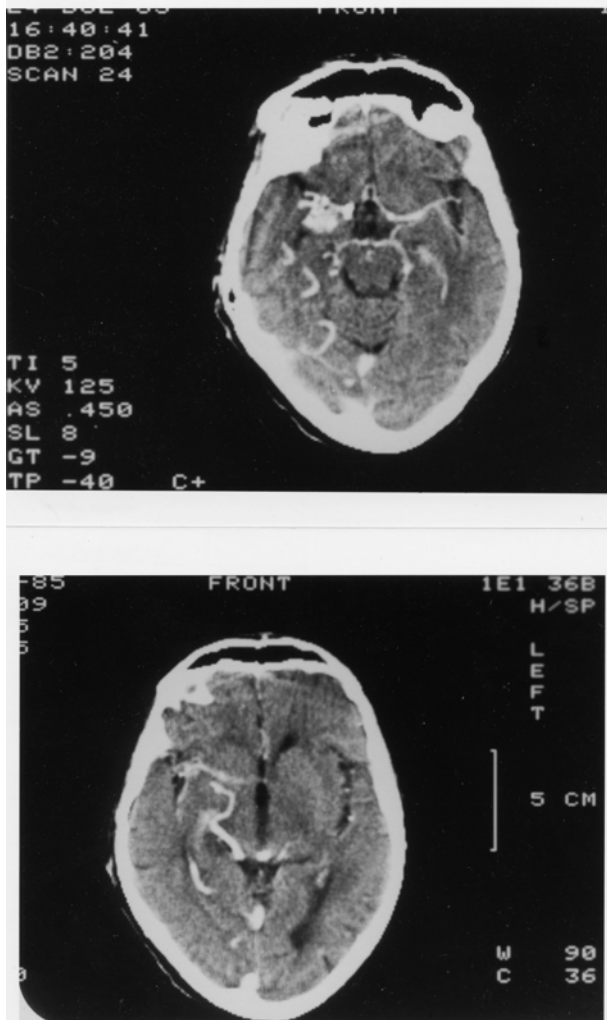


Figure 26-33. Arteriovenous malformation. Right anterior temporal:
 Case History 24-12 CT Scan. This 51-year-old right-handed female
 was evaluated in 1983. She had generalized seizures in 1977 and 36-
 year history of complex partial seizures. She would feel "weird
 sensations" and detached with a "strange odd smell", then a sense of
 terrible fear. She also had a history of migraine headaches preceded
 by visual auras, and a normal neurological examination. was not
 remarkable. The CT Scan without contrast demonstrated a calcified
 lesion in the right anterior temporal lobe (not shown).
 A). With contrast a large enhancing lesion was present in the deep
 Sylvian fissure area - involving anterior medial temporal areas, uncus
 and adjacent insula.
 B) At a higher level of section a large draining vein was visualized (see
 also fig 26-35 and text for details).

Subsequent angiographic studies confirmed the anterior venous malformation with supply from right internal carotid, middle cerebral and anterior choroidal arteries (26-33A) and the presence of shunting into a large early draining vein (26-33B).

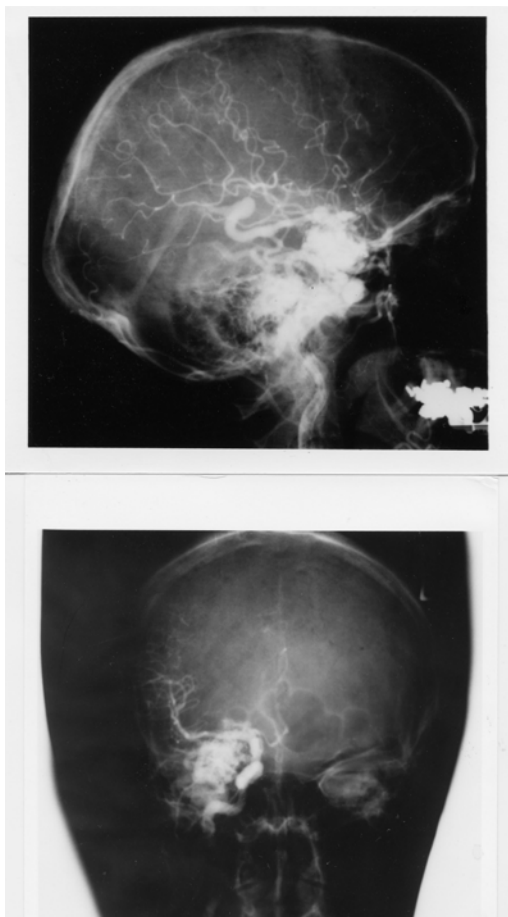


Figure 26-34. Arteriovenous malformation: Right anterior temporal lobe. Right carotid arteriograms. Case History 24-12

- A) Malformation - supplied by right internal carotid, middle cerebral, and anterior choroidal branches.
- B) There is early shunting of arterial blood into a large draining vein. See Text and Fig. 26-34 for details.

Comment: This patient presented with classical complex partial seizures originating in the right temporal lobe. No definite evidence of either subarachnoid or intracerebral hemorrhage was present over 35 years. With the use of CT and MRI scan, more of these lesions are being identified in an unruptured state in patients investigated for seizures and headaches.

Considerable controversy remains as to the appropriate therapy for the unruptured cerebral arteriovenous malformation (compare Aminoff, 1987 and Heros and Yong-Kwang, 1987). Long-term follow-ups - 12-20 years - does suggest a 25-39% risk of hemorrhage with a mortality from that hemorrhage of 10-14%. The risk of recurrent hemorrhage the first year is 6% with the subsequent annual risk for hemorrhage for both ruptured and unruptured 3% per year (see also Crawford et al, 1986, Brown et al 1988, Rigamont, et al 1988).

Surgical therapy involved excision after ligation or embolization of feeding vessels (Stein and Wolpert, 1986, Stein and Mohr, 1988, and Mohr, et al 1986).

CHAPTER 27: NON VASCULAR SYNDROMES : TRAUMA, TUMORS, INFECTIONS, TOXIC METABOLIC AND SYSTEMIC DISORDERS

I TRAUMA

Case 27-1 presents an example of an epidural hematoma seen in 1963 prior to modern neuroimaging.

Case 27-1: This twenty-two-year-old, white airman, during a winter storm, was involved in an auto accident at 11:30 p.m., in which he struck his head against the windshield. He also sustained minor abrasions of the shoulder, hands and chest. The patient apparently was dazed, perhaps unconscious, for a matter of seconds to minutes. He was taken by ambulance to the emergency room of the nearby army hospital where a brief evaluation indicated that the patient was alert, without definite neurological findings, and apparently without significant injuries. Skull X-rays did indicate a linear fracture over the right temporal area which did not, however, definitely cross the major groove of the middle meningeal artery. The patient was, therefore, admitted to the intensive care ward for head injury observation.

The patient was apparently alert upon his arrival on the ward. It should be noted, that the major attention of the physicians in the emergency room and of the nurses on the intensive care ward was given to four other patients from the same accident who sustained very severe and obvious injuries. However, by 5 a.m., the patient was reported by the nurses to be agitated and confused.

Neurological examination: (8 a.m.)

1. *Mental Status:* The patient was agitated and unable to cooperate. He was sitting up in bed, holding his head, moaning and hyperventilating to a marked degree. He answered only occasional questions and then with a yes or no.

2. *Cranial Nerves:* intact except

Fundi: The examination was negative but incomplete.

Pupils: There was a bilateral but sluggish response to light. A minimal asymmetry was present. The right pupil was perhaps slightly larger and slightly more sluggish than the left.

3. *Motor System:* All limbs were moved spontaneously. There was a variable increased resistance to passive motion, but this was apparently due to the patient's inability to cooperate.

4. *Reflexes:* Deep tendon reflexes were increased bilaterally. Plantar responses were bilaterally equivocal.

5. *Sensation:* Pain sensation appeared to be intact.

6. *Neck:* There was variable resistance to attempted flexion.

7. *Head:* The patient moaned when palpated over left or right temporal areas.

Neurological diagnosis : Possible evolving acute bilateral epidural or subdural hematoma

Subsequent course: The patient was to be evaluated by the civilian neurosurgical consultant, whose arrival was delayed by several other emergencies and a snowstorm. In the meantime, progression occurred.

Neurological examination (4 p.m.): The patient was now deeply comatose with little response to stimulation. The pupils were now bilaterally fixed and dilated. The four limbs were extended in a decerebrate posture with significant spasticity on passive motion. The degree of spasticity in the upper limbs could be modified by tonic neck maneuvers. The plantar responses were bilaterally extensor. Spontaneous respirations were now irregular and infrequent, and the patient required the assistance of a mechanical respirator.

Neurological diagnosis: Acute tentorial herniation with brain stem compression secondary to epidural hematoma.

Subsequent course: A general surgeon immediately performed definitive therapy. Bilateral burr holes were placed. An epidural hematoma over the right temporal-parietal area was evacuated and the

bleeding middle meningeal artery branch was coagulated and ligated with a significant rapid improvement in the patient's status. Follow-up examination approximately two months later indicated that the patient had returned to active duty but was experiencing some problems related to changes in recent memory and to changes in motivation and personality. No significant motor or sensory findings were present. Minor and inconsistent asymmetry of deep tendon reflexes was present.

Comment: This patient followed the usual pattern of a short lucid period followed by the rapid progression of confusion, agitation, coma and brain stem deterioration of function. As indicated by Plum and Posner (1980), the development of hyperventilation is often indicative of a midbrain-upper pontine stage of damage from an expanding supratentorial lesion. The early appearance of hyperventilation followed by bilaterally fixed dilated pupils and a decerebrate state may well indicate that the supratentorial lesion was producing a more central downward compression of the midbrain and less of a lateral uncal-type compression. In any case, it is evident that brain stem compromise was progressing rapidly. So rapidly, in fact, that therapy had to be undertaken immediately. In such a case, there was no longer time for the transfer of the patient to a specialized treatment center and no longer any time for specialized laboratory studies. Today, such a patient would have undergone CT scan studies at the time of emergency room evaluation or at the first sign of change in mental status. Similar cases of recovery of function from brain stem compression in patients with acute subdural or epidural hematomas have been reported by Brendler and Selverstone (1970).

The following case provides an example of chronic bilateral subdural hematomas

Case 27-2. (Patient of Dr. Alex Danylevich). This 83-year-old white female was transferred from her local hospital because of increasing confusion. Two months prior to admission, she had been involved in a motor vehicle accident sustaining fractures of her ribs and left clavicle. She also struck her head and had a scalp hematoma in the right frontal area. She was admitted to her local hospital at that time for several days. She was described as having post-traumatic anterograde and retrograde amnesia and obtundation which cleared over her hospital stay. She returned to her usual activities. Two months after the trauma she re-entered her local hospital with a three day history of increasing confusion and lethargy. When she became mute she was transferred to St. Vincent Hospital. Serum sodium at her local hospital had been low at 124 mEq/liter and CSF protein was reported at 62 mg%. EEG was reported as diffusely slow.

Neurological examination:

1. *Mental status:* She was relatively lethargic but could be aroused to an alert state. The patient was mute and did not follow commands even when relatively alert.
2. *Cranial nerves:* Pupils were 2 mm. and reactive. Sudden paroxysmal nystagmoid deviations of the eyes to the right occurred during the exam.
3. *Motor system:* Strength was intact. Tone was increased in the right leg.
4. *Reflexes:* Deep tendon stretch reflexes were symmetrical. Plantar responses were extensor bilaterally.
5. *Sensory system:* Pain responses were intact.

Clinical diagnosis: Chronic subdural hematomas, probably bilateral .

Laboratory data:

1. The CT scan (Fig. 27-3) demonstrated significant bilateral chronic subdural collections much denser on the left where the lateral ventricle was obscured and shifted to the right. The right lateral ventricle and sylvian fissure were enlarged. There was a question of additional recent rebleeding into the subdural collection on the left.
2. Serum sodium was low at 117 mEq/liter. Serum osmolality was 236. Urine sodium was 53 mEq/liter.

Hospital course: Serum sodium was corrected. Then, bilateral subdural hematomas were removed via burr holes on the right and a bone flap on the left where substantial chronic membrane and fluid were found. Neurological examination eight hours after conclusion of the procedure, indicated an alert patient who had no apparent language disorder and no weakness. Follow-up CT scan ,6 days after surgery revealed re-expansion of the cerebral hemispheres. Considerable cortical atrophy was

now evident. This was presumably long-standing predating the subdural hematomas. She was transferred back to her local hospital, 10 days after surgery. At that point she was alert; ambulating with assistance and was able to feed herself. She did develop transient right face and hand focal motor seizures which were treated with anti-convulsants.

Comment: If the history of trauma two months previously had not been present with a prior hospital admission related to the trauma, the confused obtunded mute state in this patient might easily have been attributed to a metabolic encephalopathy (low serum sodium) or to the cortical atrophy of a senile dementia of Alzheimer's type. Many patients with primary cerebral disease will develop a low serum sodium due to inappropriate secretion of anti-diuretic hormone with retention of water and dilution of serum sodium. The mute state in this patient in retrospect probably reflected the severe involvement of the dominant left cerebral hemisphere. The sudden eye movements to the right probably represented focal seizure activity originating in the left frontal eye fields, not far from the cortical area providing the focus for the post operative seizures.

In some patients without a definite history of trauma, the predominant findings may be those of a progressive bilateral frontal lobe involvement with confusion, bilateral grasp reflexes, and a frontal lobe apraxia of gait. In such patients, the nature of the pathological process involving the frontal lobes may be uncertain. The differential diagnostic list may include metastatic disease, frontal parasagittal meningioma or frontal glioma.

There are patients who are at increased risk for subdural hematomas: patients receiving anticoagulant medications, or patients with bleeding disorders, e.g., as in leukemia. The problem is more common in the elderly, in chronic alcoholics, and in patients with Parkinson's disease perhaps because such population groups are more prone to unsteadiness and falls. In the patient with cortical atrophy as in Alzheimer's disease, the bridging veins may be stretched and thus more prone to tear. In addition, the patient is unable to recall minor trauma and is already confused. In addition, because of the atrophy, a large amount of blood may accumulate in the subdural space without producing early symptoms of headache and other symptoms.

The problem also exists in the infant during the first year of life. The picture presented, however, differs significantly from that seen in the adult because in the infant, separation of the sutures may occur, allowing the intracranial cavity to expand. The onset is then often nonspecific and nonfocal: an enlargement of the head, a failure to thrive, a failure to gain weight, a failure to reach developmental landmarks. At times, generalized seizures, vomiting, and papilledema may be noted. The etiology often relates to presumed birth trauma.

A related problem may also be seen in infants following meningitis. This is the problem of subdural effusions usually occurring in relation to *Haemophilus influenzae* meningitis. The diagnosis of both subdural hematoma and subdural effusions may be made in the infant by CT or MRI scan replacing the earlier technique of subdural taps. The cerebrospinal fluid in these cases is often found to be abnormal with the presence of blood or xanthochromia and an elevated protein content.

II TUMORS

The following case history provides an example of the course of a low grade glial tumor.

Case 27-3: This 41 year old right handed white widow was admitted to the hospital because of increasing frequency of seizures. At age 30, eleven years prior to admission, the patient experienced her first generalized convulsive seizures. The neurological examination and the electroencephalogram were normal. Four years prior to admission, the patient had a change in the character of her seizures, she began to experience focal seizures involving the right arm and leg. These would begin with the sensation of a "chill" or stiffening of the right leg and a "numbness" (a tingling) which would then spread to the lower back. At the same time, weakness would occur in the right leg followed by repetitive clonic movements of the right arm. During this time, the patient would be unable to talk distinctly but would be aware of her surroundings. Although the episode continued for several minutes, there was no apparent loss of consciousness. Examination by Dr. John Hills at that time revealed a slowness of response but no definite neurological deficits. The EEG was again normal. Neurological evaluation three years later (one year prior to admission) was again unremarkable although focal seizures were still occurring every 2-4 weeks. Evaluation 2 months prior to admission, now indicated a more increase in deep tendon stretch reflexes in the

right lower extremity and an equivocal plantar response on the right side .Hospital admission finally occurred because the weakness experienced in the right leg during the seizure was becoming more severe.

Neurological examination

1. *Mental status*: The patient was anxious and tremulous with moderate psychomotor retardation and poor attention span. Digit span was limited to 5 digits forward and 4 in reverse .However orientation, memory ,delayed recall , calculations and language function were all intact.
2. *Cranial nerves*: All were intact with no papilledema.
3. *Motor system*: Strength, gait and cerebellar signs were all normal.
4. *Reflexes*: Deep tendon reflexes were slightly increased on the right side. The plantar response on the right was equivocally extensor.
5. *Sensory system*: Intact except for a minimal bilateral decrease in sensation at the toes.

Clinical diagnosis: Left parasagittal tumor most likely a meningioma, low grade glial tumor such as oligodendroglioma or low grade astrocytoma considered possible but very unlikely.

Laboratory data:

1. Chest and skull x rays ,radioactive brain scan(Hg 197) and left carotid arteriogram were all normal.
2. *EEG* was now mildly abnormal because of occasional focal sharp waves ,left parietal parasagittal area.
- 3.*Pneumoencephalogram* demonstrated a slight downward depression left lateral ventricle suggesting a possible left parasagittal mass. The CSF obtained was normal.

Subsequent course: Since the brain scan and arteriogram were normal, a meningioma was considered unlikely and a low grade glioma was considered the most likely diagnosis. The lack of calcification on the skull x rays was considered a point against the diagnosis of an oligodendroglioma and more in favor of a low grade astrocytoma. Since the patient was relatively free of neurological deficit and the dominant hemisphere was involved, neurosurgical intervention was deferred .Her anticonvulsant medications were readjusted. Frequent office evaluations indicated that significant progression was occurring with increasing weakness of the right leg, and an inability to form letters in handwriting. .Four months after hospital discharge ,the patient now had a right central facial weakness ,a mild right hemiparesis, and increased deep tendon stretch reflexes on the right and a right Babinski sign. Speech was dysarthric with a minor degree of misnaming or inability to name objects. A left carotid arteriogram now indicated a deep left posterior frontal mass lesion. There was also a suggestion of abnormal vascularity in the region of the pericallosal and callosal marginal branches of the anterior cerebral artery. Surgical exploration of the left frontal area indicated slight discoloration of and widening of gyri. Probe counting located an area of increased uptake of isotope (P32) at 16X normal in the mid and posterior frontal area. A partial frontal lobectomy was performed from the level of the sphenoid wing laterally and forward but sparing the speech areas. However tumor was still present at the posterior margin of the resection . Histologic examination of the tumor removed indicated a grade I- II astrocytoma. Following surgery ,the right sided weakness progressively improved, speech was unchanged. Following hospital discharge the patient ,received a 3 month course of supervoltage radiation (7,500 roentgens)directed to the left frontal parietal area. When last evaluated 18 months after surgery, there was a moderate disorientation for time , a nominal aphasia a slowness in following commands ,a perseveration of speech and performance, a right central facial weakness and a clumsiness in following commands.

Comment: The onset of seizures at age 30 ,always raises the question of a possible brain tumor. The initial seizures however were generalized convulsive seizures and the neurological examination and the EEG were normal, thus decreasing the risk of a tumor. When focal seizures appeared at age 36,the risk of a tumor was significantly increased but still ,the exam and the EEG remained normal .In retrospect ,the slowness of response might have suggested some frontal lobe involvement. By age 41, it was evident that a focal process was slowly evolving with some involvement of parasagittal motor cortex. Again the psychomotor retardation and the deficit in digit span at a time that delayed recall was normal (possibly consistent with an impairment of working memory) might have suggested some degree of. prefrontal involvement. Certainly, by the time of surgical intervention, 11 years after onset of symptoms, the pace of progression had accelerated. This might have indicated some alteration in the basic biological activity of the tumor.

Finally a note about diagnostic techniques . This patient was initially seen in 1956 and hospitalized in late 1967. At the time CT scan and MRI were not yet available. Today, an adult with onset of seizures at age 30 would have undergone an MRI or at least a CT scan with contrast. The diagnosis would have been made much earlier in time but the eventual treatment and results of treatment would probably not differ significantly from those obtained in 1967. The role of radiotherapy in low grade gliomas remains controversial. There is a role once transformation to a higher grade of malignancy has occurred.

MALIGNANT GLIOMAS

The following case demonstrates the apparent acute (possibly stroke like) onset and rapid progression of a very malignant glioblastoma multiforme.

Case 27-4 (patient of Dr. Tom Mullins): This 68 year old right handed white male was admitted to St Vincent Hospital with an apparent 4 to 5 day history of difficulty in doing calculations and in speaking, “he could think of the word ,but had difficulty getting it out”.

Neurological examination :

1. *Mental status and language function*: Speech was limited to short phrases with loss of connectors and sentence structure. Writing was impaired but, repetition, comprehension, naming and reading were intact.
2. *Cranial nerves*: Intact.
3. *Motor system*: Strength and gait were intact .However fine motor movements of the right hand were impaired .
4. *Reflexes*: Tone was increased on the right. The right patellar reflex was increased. Bilateral Babinski signs were present.
5. *Sensory system*: Intact.

Clinical diagnosis: Diagnosis was uncertain .The abrupt onset suggested a possible vascular event such as an embolus in the middle cerebral artery territory but the overall pattern including bilateral Babinski signs without significant hemiparesis was unusual. Thus other possibilities had to be considered including focal herpes simplex encephalitis, tumor or a small lobar hemorrhage.

Laboratory data :

1. EEG : Focal left hemisphere delta and theta slow wave activity was present.
2. CT scan(Fig.27-7):A. The non enhanced study demonstrated a low density mass in the mass in the left frontal-parietal parasagittal region with areas of hemorrhage. B. The contrast enhanced study demonstrated an irregular rim of enhancement.
3. Angiogram indicated an avascular mass in the left frontal-parietal area.

Subsequent course: Dr. Alex Danylevich performed a subtotal resection of this tumor which was found to contain blood clot and cystic fluid. The histology of the tumor was glioblastoma multiforme (Fig.27-5). The patient subsequently received 4000cGy whole brain radiation and an additional 2000cGy to the tumor site. Three months following surgery ,the patient developed increasing obtundation. CT scan revealed a large left frontal necrotic mass. Fever, hypocalcemia and hypernatremia developed and he expired one month later.

Comment: This patient presented with what appeared to be an abrupt onset of language problems raising the question of a cerebrovascular accident. In retrospect , it was evident on the CT scan and at surgery that the acute onset reflected the hemorrhage and necrosis which had occurred within the tumor. This was a rapidly growing ,extremely malignant tumor which apparently had outstripped its blood supply despite the neovascularity.

III INFECTIONS

FOCAL

Subdural empyema

The following case provides an example of subdural empyema complicating frontal sinusitis.

Case 27-5. This forty-eight year old, right-handed, white male was referred for evaluation because of headaches and papilledema. For 3 weeks prior to admission, the patient had severe bifrontal headaches which were constantly present and interfered with sleep. One week prior to admission, the patient developed a fever of 105° with a white blood count (WBC) of 25,000. X-rays indicated "sinusitis". The patient was hospitalized at his local community hospital. Confusion soon developed. Three days prior to transfer to a neurologic unit, the patient had a series of seizures characterized by turning of the head and eyes to the left. Lumbar puncture had indicated clear cerebrospinal fluid with pressure of 300 mm. and protein increased to 65 mg./100 ml. The patient had chronic right nasal discharge for ten years. Eight weeks prior to admission, the patient, while stooping down, struck his right frontal areas but was not - unconscious. A right periorbital ecchymoses developed, and the patient also had the onset of bilateral frontal headaches.

General physical examination: Temperature was elevated to 101°. There was right periorbital edema. Excoriation of right nasal mucosa was present.

Neurological examination:

1. **Mental status:** The patient was alert but irritable and slightly confused. He was poorly attentive and failed to persist in carrying out motor activities. He was oriented grossly for time, place and person. Calculations were poorly performed. Delayed recall was defective.
2. **Cranial Nerves:** All were intact with the exception of the fundi. Low-grade papilledema was present and venous pulsations were absent.
3. **Motor System:** Strength was intact, but there was a slight drift downward of the outstretched left arm.
4. **Reflexes:** Deep tendon reflexes were somewhat brisker at left arm and leg (3+) as compared to the right (2+). Plantar responses were flexor. A bilateral grasp reflex was present.
5. **Sensory system:** Intact
6. **Skull & Neck:** There were slight tenderness over the right periorbital area. Minimal nuchal rigidity (resistance to passive flexion of the neck) was present.

Clinical diagnosis: Right frontal subdural empyema or brain abscess.

Laboratory data:

1. The *WBC* was increased to 14,350 cells per cubic mm., and the sedimentation rate was increased to 110 mm. in one hour.
2. **Sinus X-rays:** Bilateral maxillary and frontal sinusitis was present with resorption of bone.
3. **Electroencephalogram:** Focal 4 to 7 cps slows wave activity was present in the right parietal area suggesting focal damage. Moreover, focal voltage suppression (reduction of voltage) was present in the right anterior frontal area suggesting a possible subdural collection.
4. **Right carotid arteriogram** showed an apparent slight shift of the anterior cerebral vessels to the left suggesting a right hemisphere space-occupying lesion.

Hospital Course: Following these studies a right frontal trephine (burr) hole was placed by Dr. Robert Yuan. When the dura was incised, 5 cc. of yellow purulent material escaped from the subdural space and additional purulent drainage was aspirated. Additional burr holes were placed in the right occipital area where a few drops of subdural pus were encountered. No pus was obtained from the left subdural area. Subsequent cultures demonstrated *Staphylococcus aureus* as the responsible organism. The dura and cortex otherwise appeared unremarkable although cerebral edema was present. The patient was subsequently treated with appropriate antibiotics. His temperature gradually subsided to normal and his mental

status cleared. Three weeks later, a bilateral frontal sinusotomy was performed by Dr. Thomas Klein with drainage of the sinus. Histological examination of a section of sinus mucosa removed demonstrated intense chronic inflammation. The patient continued to improve. When seen in followup examination four months after admission, papilledema had subsided, no neurological findings were present except for a slight reflex asymmetry (slightly increased on the left).

Comment: This patient presented a definite history of chronic nasal sinus infection with a recent exacerbation. The role of trauma in the exacerbation is uncertain. It is clear, however, that the sinusitis had produced involvement of the adjacent bone with subsequent spread to the adjacent frontal subdural space. The severe headache experienced by the patient reflected not only the process of infection involving the sinus and meninges but presumably also the increase in intracranial pressure. The early involvement of the right frontal area was suggested by the initial symptoms of confusion and by the occurrence of focal seizures characterized by turning of the head and eyes to the left. The findings of the electroencephalogram suggested a subdural collection of fluid or pus in the right frontal area.

These clinical and laboratory impressions were confirmed by the subsequent surgical observations. In the present case the arteriogram suggested only a non-specific space-occupying lesion in the right frontal area. The more specific finding in these cases would involve the displacement of distal branches of the anterior and middle cerebral artery from the inner table of the skull as in a subdural hematoma. Today the CT scan or the MRI/MRA is the study of choice for confirming the diagnosis of a subdural collection. Additional review of subdural empyemas will be found in Miller et al 1987. In the pre-antibiotic era, infections involving the nasal sinuses could produce thrombophlebitis of the cortical veins and superior sagittal sinus. With that complication, infarction of that area of motor cortex representing the leg could occur resulting in unilateral or bilateral leg weakness as well as focal motor seizures. Infection of the nose or face or of the ethmoid or sphenoid sinuses could produce thrombophlebitis of the cavernous sinus resulting in the syndrome discussed in the cranial nerve chapter: unilateral or bilateral involvement of the cranial nerves found in the lateral wall of the cavernous sinus (III, IV, VI and the ophthalmic division of V). The ophthalmic vein may be obstructed producing edema of the eyelid and face. Obstruction of the retinal vein produces papilledema. Infection of the middle ear or mastoid may produce involvement of the transverse or lateral sinus. If this extends to the jugular vein, increased intracranial pressure may also occur. However increased intracranial pressure may follow any involvement of the other venous sinuses. At the present time, dural venous sinus thrombosis is usually more indicative of dehydration and other systemic conditions in the infant and in the adult of immunological disorders or of conditions that produce a state of hypercoagulation such as polycythemia, carcinoma, pregnancy or birth control drugs. (refer to Daif et al, 1995 and DeVeber et al, 2001)

CHAPTER 30 MEMORY

A case of Wernicke-Korsakoff syndrome is presented in case 30-1.

Case 30-1. Patient of Doctor John Sullivan and Doctor John Hills): This 62-year-old, white, right-handed stonecutter had been a known heavy alcoholic spree drinker for many years. The patient would drink large quantities of wine for 6 to 8 weeks at a time. Two years previously, the patient had been admitted to the Boston City Hospital because of delirium tremens (tremor and visual hallucinations). Two months prior to admission shortly following the death of a brother-in-law, the patient began his most recent drinking spree. He unaccountably found himself in Florida, not knowing where he was and

why he was there. Apparently, he had drifted aimlessly for 5 weeks with no definite food intake for a month. The patient was brought back by his family and hospitalized at his local community hospital with diplopia, ataxia and marked impairment of memory. The patient had complaints of numbness of his fingertips and unsteadiness of gait. The patient after beginning treatment was shortly thereafter referred to the Neurology Service at the New England Medical Center.

General physical examination: No abnormalities were present except for an enlarged liver with the edge palpated approximately 2-1/2 finger breadths below the costal margin.

Neurological examination:

1. Mental status:

- a. The patient was markedly disoriented for time and place. At times, the patient thought that he was in New Jersey; at other times, he stated correctly that he was in Boston.
- b. The patient, with suggestion, would recall his apparent travels that day to various other locations within and outside Boston (he was actually in the hospital). Confabulation was also evident when it was suggested that he had recently seen various fictitious persons.
- c. Remote memory; The patient was unable to state his age. The patient was able to provide his birth date correctly. He could not give his address or telephone number. When quizzed as to the President of the United States, he selected on multiple choices the previous president. At times, the patient often indicated to visitors that his mother and father were still alive, though both parents had been dead for over 20 years.
- d. Insight; He appeared to have little insight for his disorientation in time. He had no insight as to his condition or for the reason for his hospitalization.
- e. The patient's digit span was normal at 7 forward and 6 in reverse.
- f. The patient could name various objects correctly when these were presented to him and yet he was unable to retain any memory of which objects had been presented to him five minutes previously. He was unable to retain any information concerning a story that he had been requested to learn.
- g. The patient was able to do 2 and 3 figure additions and multiplications without difficulty. He was able to do the initial subtractions in the serial 7 test but then lost track of the number to be subtracted.
- h. The patient was able to read and to write without difficulty. He showed no constructional apraxia and no left-right confusion.

2. *Cranial nerves:* There was horizontal diplopia on right lateral gaze. The minor degree of separation of images, however, did not allow precise identification of the muscle involved. A minor weakness of the right lateral rectus was suspected.⁶ Horizontal nystagmus was present on lateral gaze, bilaterally and vertical nystagmus on vertical gaze.

3. *Motor system:* Strength was intact except for a minor degree of weakness in the distal portions of the lower extremities evident on ankle dorsiflexion and toe dorsiflexion.

The patient walked on a narrow base with eyes open and showed no evidence of an ataxia of gait. On a narrow base with eyes closed, the patient had a positive Romberg test.

No cerebellar findings were present.

4. *Reflexes:* Deep tendon reflexes were normal at triceps and biceps, decreased at radial periosteal. And absent at patellar and Achilles even with reinforcement.

⁶ The minor nature of the diplopia undoubtedly reflected the improved nutritional status that had occurred during the previous 5 days of hospitalization at his community hospital. We presume that if the patient had been examined prior to hospitalization, more marked lateral rectus palsy probably would have been delineated.

Plantar responses were flexor bilaterally.

No grasp reflex was present.

5. Sensory System: Pain and touch were decreased in the lower extremities below the mid calf. Vibratory sensation was absent at the toes and decreased over the tibia to a marked degree and to a lesser degree over the knees. There was to a lesser extent, a decrease in the upper extremities at the fingertips and wrists.

Position sense was decreased at fingers and toes.

Clinical diagnosis: Wernicke' encephalopathy plus nutritional poly neuropathy

Laboratory data: Complete blood count, liver functions and renal functions, CSF, EEG, and X-rays of the skull and chest were all normal.

Subsequent course: The patient was treated with thiamine, 50 MGS daily. There was a significant improvement in extraocular functions. The patient had no diplopia after the day of admission. There was no significant change in his mental condition or peripheral neuropathy. Evaluation 3 months later, indicated persistent disorientation for time and place and severe selective deficits in memory (delayed recall was still grossly defective).

Comment: This patient presents a relatively typical history of the Wernicke-Korsakoff syndrome. He had been a heavy alcoholic spree drinker. The major symptomatology that was apparent to the patient's family and to his physician, related to his marked confusion, severe impairment of memory and confabulation. The patient himself had no significant complaints and little insight into his disease. In some cases, the severe memory disturbances may be present without any definite evidence of confabulation. Not only the retentive memory for new material was impaired but also the patient's distant memory was also significantly impaired. In such cases with severe impairment of memory the prognosis for a complete recovery of mental status is very poor. The diplopia and nystagmus, as expected, resolved significantly with treatment with thiamine. The ataxia of gait, which had been present early in the case, had apparently resolved by the time of transfer from his local hospital. A significant peripheral neuropathy, mainly distal sensory, was present related to multiple B vitamin nutritional deficiency.

In many cases, the state of confusion in Wernicke's encephalopathy is preceded by or accompanied by a period of delirium tremens indicating alcohol withdrawal. The use of intravenous glucose feedings without supplemental intravenous thiamine during such a withdrawal state may actually increase the requirements for thiamine, thus exacerbating the thiamine deficiency state. For this reason, all patients under treatment for alcohol withdrawal (or admitted to the hospital with a recent past history of alcoholism) should be treated with high dosage vitamin therapy as well, on the presumption that they are candidates for nutritional deficiency.

A case of transient global amnesia is presented in case 30-2 below.

Case 30-2: This 55-year-old, right-handed, white male, college professor, awoke at 3:00 a.m. on the morning of admission in an uneasy and restless state. He asked his wife what day it was but then did not recall what she had told him. He did not know the month, kept repeating himself and asking the same questions. His wife arranged for him to be seen early in the morning by his family physician who lived a short distance away. The patient, who was familiar with the route, was unable to find his way there. When he arrived at the doctor's office, he was unable to explain why he had come. The patient apparently had forgotten about the incidents, which had occurred earlier that morning. He had no recollection that he had a grandchild born three weeks before. He could remember no significant events from this 3-week period prior to the onset of his illness. The patient's more remote recall and other intellectual capacities remained intact. The patient drove into Boston later that day but became lost despite the usually familiar route.

The patient had a past history of gout with an elevated serum uric acid level.

Neurological examination: Findings were essentially limited to the mental status examination.

When examined in the early afternoon, the patient was beginning to regain some of his ability to retain new information. The patient was generally oriented to person and place. However, he was disoriented for the day and month but was oriented for the year. The patient's store of information was quite intact suggesting a highly intelligent person.

The patient had marked difficulty with delayed recall. He could recall none of the 4 objects after 5 minutes. He could not remember any of the three test phrases given to him when asked about these 5

minutes later. He did recall in a vague manner that a memory test had been given him. As regards recent memory, the patient was unable to remember his visit to his family physician earlier in the day. Digit retention, however, was relatively well preserved; 6 forward and 5 backward. The patient had no defects in calculation. There was no evidence of a constructional apraxia. Language function was entirely intact.

Clinical diagnosis: Probable transient global amnesia

Laboratory data:

1. Complete blood count, serology, blood urea nitrogen, total cholesterol, uric acid skull and chest X-rays, EEG and complete CSF were all within normal limits.
2. The *brain scan* demonstrated a small area of increased uptake of radioisotope (Hg197) in the left temporal region.

Subsequent course: Over the several hours following admission, the patient gradually regained his ability to retain new information and to recall the events of the preceding 3 weeks, the more remote events being recalled first. The memory for the events of the day prior to admission was regained last. This pattern is referred to as a shrinking retrograde amnesia. The specific events that occurred on the morning of admission were never recalled. The following morning delayed recall was four-out-of-four objects after 8 minutes. The patient's mental status and neurological examination were otherwise within normal limits. A repeat brain scan, 3 months after the episode demonstrated considerable improvement, and all brain scan findings had resolved at 5 months. No additional episodes occurred during the one-year after the acute episode.

Comment: The patient's main deficit was in learning new information (anterograde amnesia) with the old stored long-term memory information still intact. During the episode there was a retrograde amnesia that initially extended back for three weeks. As recovery occurred, this retrograde amnesia disappeared. These relatively recent past memories were intact but transiently not accessible. The labile stage of long-term memory has been estimated to be a matter of 20-180 minutes. This case suggests that there is not a sharp border between the labile more recent stage and the remote stage of long-term memory or perhaps of the ability to access those memories. The patient could not remember what happened during the episode. That is suggestive of mesial temporal lobe involvement, in this case left hippocampal region in dominant hemisphere. The ability to perform calculations and language functions was otherwise intact. This would suggest that lateral temporal areas were not involved. The electroencephalogram was normal and consistent with such a lack of involvement of the lateral aspects of the cerebral hemispheres. Occasionally, the EEG will demonstrate a minor focal involvement of the temporal lobe. More often, as in this case, the study is normal. CT scan and MRI when performed are usually unremarkable. SPECT scan might well indicate transient focal involvement as indicated above. The brain scan in this case did suggest a transient abnormality, which would be consistent with an area of ischemia/ infarction, which resolved over the succeeding months. Such an episode must be distinguished from episodes of amnesia, which may occur in relation to, and following a temporal lobe seizure.

The effects produced by electrical stimulation of the hippocampus may also occur as relatively selective ictal and postictal phenomena in a complex partial seizure originating in mesial temporal lobe structures as illustrated in case history 30-3 which follows. Focal temporal lobe seizure phenomena were followed by a period of impaired recent memory with an inability to record new memories.

Case 30-3: This 68-year-old, white male one year prior to valuation fell, striking his occiput and transiently losing consciousness. Except for a persistent defect in his sense of smell, the patient had no apparent neurological defects following this injury. Approximately six months later, the patient had the first of a series of recurrent episodes of amnesia. These episodes occurred most often on awakening. On some, but not all, occasions the episodes were preceded by a sensation of gastric upset, a strange odor and a sensation of familiarity (*déjà vu*). The episodes of total amnesia would last 30 to 60

minutes. There would then be an impairment of memory for approximately one to two days. The patient was said during the episode of total amnesia and during the subsequent episode, to behave in an otherwise normal and rational manner. For example, he would be able to converse with his wife and others. During the episodes, he was said to be unable to remember tasks, which his wife had asked him to do during that day. A significant impairment of retentive memory would be apparent to his wife and to others. His memory for more distant and remote events was also impaired to a variable but lesser degree. The patient would then regain memory progressively over the course of the next one to two days. Apparently, memory was not regained in any orderly pattern from recent to remote or vice versa. The patient at no time had any abnormal movements suggestive of a generalized convulsion.

No automatisms had been noted and to others the patient would appear fully conscious during the episodes.

Neurological examination:

1. *Mental Status*: The patient was oriented for time, place, and person. Delayed recall was intact. The patient could remember 4-out-of-5 objects in 5 minutes. Remote memory was intact. Digit span was slightly impaired at 6 numbers forward and 4 in reverse.

2. *Cranial Nerves*: All areas were intact with the exception of cranial nerve I where olfaction was decreased for the odor of coffee grounds, bilaterally.

3. *Motor system, reflexes and sensory system*: *Intact*.

Clinical diagnosis: 1) Complex partial seizures (most likely post traumatic) with episodes of amnesia as an ictal and or post ictal phenomena. 2) Post traumatic anosmia.

Laboratory data: 1. *Skull X-rays, routine EEG, radioactive brain scan, fasting blood sugar and glucose tolerance tests, pneumoencephalogram and spinal fluid examination were normal..*

2. *The EEG obtained after a period of sleep deprivation revealed occasional multifocal spikes during sleep in the right anterior temporal area and to a lesser degree the left frontal-anterior temporal area.*

Subsequent course: The patient was treated with anticonvulsant medication. The episodes continued to occur once per month but were now of shorter duration, lasting only 15 to 20 minutes. The impairment of memory was less marked and involved only the ability to learn new material without prolonged periods of retrograde amnesia. After 8 months no additional episodes occurred. When seen three years after initial evaluation his neurological examination was unremarkable except for the defect in olfaction suggesting that more serious progressive disorder was not present.

Comment: In this case the episodes experienced by the patient could have posed a diagnostic problem if the occasional warning symptoms of olfactory aura, déjà vu and epigastric sensation had not been present. Most of the episodes experienced by the patient were not preceded by these clear symptoms of temporal lobe seizure, but were instead simply episodes of amnesia. Though the actual temporal lobe seizures apparently lasted only a matter of 30 to 60 minutes, some degree of impairment of memory was present for one to two days following the episode.

The etiology of the seizures in this case must relate to the patient's preceding head trauma. The loss of olfactory sensation following the trauma suggested that this trauma was of sufficient nature to tear the nerve filaments passing through the cribriform plate to the olfactory bulb on the orbital surface of the frontal lobe. Such trauma does produce contusions of the orbital frontal cortex and epileptogenic foci may result. We may also assume that this trauma may have been sufficient to produce some minor contusion of the anterior poles, inferior and medial surfaces of the temporal lobes against the bony walls of the middle fossa with a resultant scar and epileptogenic focus. The fact that olfactory hallucinations and the experience of déjà vu preceded some of the amnesic episodes

would make the temporal origin more likely. The routine electroencephalogram is not reliable in the detection of seizure discharges in either the mesial temporal or the orbital frontal areas. The electroencephalogram showed significant areas of discharge in the temporal lobe only under conditions of sleep deprivation which acts to precipitate seizure discharges in individuals who have an underlying predisposition for seizure discharges. For additional discussion, see Gallassie, et al (1988), Hughlings-Jackson (1889), Tassinari, et al (1991).

The following case history presents an example of presenile dementia.

Case 30-4: This 64 year old right handed white male formerly an administrative assistant for the veteran's administration and newspaper distributor was initially evaluated for impairment of recent memory. Initially, the wife indicated this had been progressive over 4 years, but she was subsequently able to date this back to age 54 years, 10 years previously. A review of his record indicated that another neurologist of our department had seen him 4 years previously with similar memory complaints. The neurological examination at that time demonstrated no focal features, but his mental status examination indicated an inability to recall any of four objects. There were minor changes in time orientation: his date was off by one month and the day of the week was incorrectly stated. In the interim, the memory problems had progressed. In addition there were now personality changes. He no longer participated in those activities which had previously been of great interest. He was also having some problems in finding words. There were no problems in the activities of daily living and he was not getting lost in his familiar environments.

Family history: There was no history of neurological disease in his siblings or father. His mother had died at the relatively young age of 48 of cancer.

Neurological examination:

1. *Mental status:* The mini mental status exam indicated a total score of 19 out of 30. He had particular problems in time orientation. He was able to do the immediate recitation of three objects and of a test phrase but could remember none of these on a delayed recall test. He also had difficulty copying a test figure. The patient was often tangential in his answers and demonstrated inappropriate joking.

2. *Cranial nerves:* intact

3. *Motor system* was intact as regards strength, gait and cerebellar functions. However premotor /frontal lobe functions were abnormal. He had a release of the instinctive grasp reflex. He had difficulties performing the Luria three stage motor sequences demonstrated by the examiner (slap thigh with palmar surface, then with ulnar edge of hand and then with ulnar surface of closed fist.).

4. *Reflexes:* deep tendon stretch reflexes, and plantar responses were physiologic.

5. *Sensory system:* intact

Clinical diagnosis: Alzheimer's disease

Laboratory data:

1. All screening studies such as *complete blood count, sedimentation rate, B -12, folate, thyroid functions and serological test for syphilis* were normal.

2. *CT scan* demonstrated significant dilatation of the temporal horns. (This change in the size of the temporal horns suggested hippocampal atrophy.) In addition there was a general increase in lateral ventricular size. There was also blunting of the angles of the frontal horns.

3. *SPECT scan* was within normal limits except for a slight decrease in perfusion in the left parietal region.

Subsequent course: The patient was begun on treatment with 5mg per day of donepezil (Aricept) a centrally acting acetylcholinesterase inhibitor and high dosage of vitamin E (a possible antioxidant). . When re-evaluated at one month, his family reported improvement in memory; the mini mental status exam score was now 21 out of 30. At 10 weeks into treatment, the score had increased to 25 out of 30. There was particular improvement in the delayed recall section of the exam. There was however no change in personality. He still showed inappropriate jocularity when he could not answer a question and at times was tangential in his answers. Administration of the acetylcholinesterase inhibitor temporarily improved memory function for approximately 18 months. However by age 67, behavioral disturbance (agitation, aggression nocturnal wandering and sexual disinhibition) and urinary incontinence were becoming major problems. He could no longer be managed in his home and day care setting despite the

use of haloperidol. This resulted in his placement in a nursing home. At age 69, he was now described as relatively nonfluent, and very confused. He recognized his own name and occasionally recognized relatives but showed no other response to questions. He was usually restricted to a wheel chair, could walk with assistance. He was “stiff and afraid” when requested to walk.

Comment: This patient presents a typical example of the slowly progressive course of Alzheimer’s disease. Memory problems had begun insidiously at approximately age 54. Initially these problems in the older adult may be attributed to a benign age related process in which there is minor difficulty in accessing information such as names although the ability to incorporate new information is still intact (“wait a minute, the name or word will come to me eventually”). When evaluated by a neurologist at age 60, the major finding was a severe deficit in delayed recall suggesting a process at the level of the hippocampus. The patient failed to return for follow up at that time and when he did reappear at age 64, he was now beginning to show changes in personality and frontal release signs suggesting involvement of the prefrontal and premotor areas. The use of a cholinesterase inhibitor produced some improvement in memory for about 18 months but had little effect on the changes in personality and behavior. The use of this agent has been estimated to postpone nursing home placement by approximately 15 months. Eventually by age 69, fifteen years after disease onset, gait and other motor functions were seriously affected.

The rationale for the use of cholinesterase inhibitors is based on the demonstration by Drachman and Leavitt (1974) that administration of scopolamine, an anticholinergic drug that crosses the blood brain barrier, would produce a transient syndrome similar in many respects to memory and cognitive changes of Alzheimer’s disease. Subsequent studies demonstrated a marked loss of neurons in the basal forebrain nucleus of Meynert, a major source of cholinergic fibers to the cerebral cortex. (Whitehouse et al 1981 Rogers et al, 1985 editorial of Growden 1992). However, a simplistic cholinergic hypothesis is insufficient to explain all of the features of Alzheimer’s disease. Administration of acetylcholine esterase inhibitors in mild cases (mini mental status score of 10-25) has only a limited value as in the present case. Other neuronal systems are involved (noradrenergic synapses are also involved. hippocampal system is severely involved).

The following case 30-5 provides an example of general paresis producing severe changes in cognitive function and personality.

Case 30-5 : This 59-year-old right-handed white male, cleaning establishment owner, five years prior to evaluation, manifested a personality change - increased rigidity and irritability. He would become enraged over trivial matters many times per day. During the last 1.5 years, this process accelerated. He became more antisocial, unable to interact with employees and customers. His level of comprehension declined. He became more aggressive towards his wife and children. He often manifested frank paranoia and suspiciousness, accusing his wife of unreal, sexual infidelity. During the last 1.5 years, a significant gait disturbance had also developed, with impairment of balance. A slowing in speech and a tremor of hands had developed over the previous year.

The patient had been born in Poland. All significant infections were denied. He had received injections of “liver” and B12 after the war “for anemia” but had received no recent B12 injections.

Neurological examination:

1. *Mental status:* The patient was oriented for time, place and person.

Delayed recall was markedly impaired none of five in five minutes without assistance, one of five with assistance. Repetitions and naming of objects were intact. Distant (remote) memory was good. The patient could list all major world leaders during World War II and all assassination attempts.

The patient was often tangential in his responses and often initiated irrelevant conversations.

Serial 7 subtractions could not be done but the patient could reverse 12 months of the year.

Abstract reasoning for similarities was poor.

He often got up from the bed and looked outside the curtain, checking the activities of his roommate.

2. *Cranial nerves:* Pupils were small, 2 mm., and irregular but did respond to light.

Twitching and grimacing of face, eyelids and tongue occurred. He also had a lid lag.

3. *Motor system*: Strength was intact. Gait was wide-based, with a positive Romberg test. The patient was quite tremulous with occasional myoclonic jerks. He could not do rapid alternating movements.

4. *Reflexes*: Deep tendon reflexes were normal (2+) in the upper extremities, trace at patellar and absent at Achilles. Plantar responses were flexor, bilaterally. There was no release of the grasp reflex. Other frontal release signs were absent.

5. *Sensory system*: Pain, touch and position sense intact. Vibration was markedly decreased at toes, and ankle with minor preservation at knees.

Clinical diagnosis: Progressive dementia and personality change. Multiple entities to be considered including (1) the combination general paresis and tabes dorsalis, (2) B12 deficiency, (3) frontal lobe tumor, (4) frontal dementia and (5) Lewy body dementia

Laboratory data: The abnormal findings included:

1. *Vitamin B12 level* was borderline low at 209 picograms/ml., *Schilling test*, however, demonstrated normal absorption (25.4% excretion of radioactive B12 in urine).

2. Serum serological test for syphilis (RPR) was reactive with the more specific FTA markedly reactive.

3. *Cerebrospinal fluid*: 98 white cells were present - all lymphocytes. CSF protein was elevated to 116 mgs.% (normal <45 mgs.%). Sugar was low at 44 mgs.% with a simultaneous blood sugar of 90. Spinal fluid serological test for syphilis (VDRL) was positive.

4. *CT scan* showed mild frontal and temporal atrophy

Subsequent course: The patient was hospitalized for two weeks and received high dosage intravenous penicillin therapy, three million units every four hours for 10 days (18 million units per day).

When seen again 2 months later, the patient and his family reported that gait and coordination had significantly improved. Memory and personality had not improved. He still had episodes of agitation and irritability. Reflex and sensory findings were unchanged. The patient had been inconsistent in taking any medication such as haloperidol, aimed at altering his agitation.

He failed to return again for 18 months. Paranoid ideation had become more prominent. He could no longer manage his fiscal affairs. Orientation and delayed recall were intact. There was minor tremor of the hands and an unsteadiness of gait. Romberg was positive although position and vibratory sensation were intact. Serum serology was now negative. Lumbar puncture now indicated no significant cells, a normal protein.

Subsequently he did require hospitalization for renal failure secondary to enlarged prostate and a neurogenic bladder. Spinal fluid VDRL and serum RPR serological tests for syphilis, were both nonreactive. Serum FTA ABS - a much more specific and more sensitive test for previous syphilis was still 3+ reactive.

Telephone follow-up 11 years after the initial episode indicated that personality and cognitive changes had essentially leveled off, irritability and hostility were less. He had no urinary problems. He was unsteady in walking, but was still able to drive small distances and was living at home. Additional information approximately 20 years after the initial evaluation indicated that he spoke very little, he no longer demonstrated agitation. His mobility was more limited. Of interest, one pupil no longer responded to light but did respond to accommodation. CT scan demonstrated greater atrophy.

Comment: This patient had clinical manifestations predominantly related to general paresis. Both the history and the examination also provided evidence of tabes dorsalis. Penicillin therapy resulted in a non-active state, as regards serum serology and any cellular activity in the spinal fluid. However, the damage to cerebral cortex was not reversed and continued to provide a significant problem, as regards personality function. Thus, once cognitive function has been altered, due to damage to and loss of neurons, the changes in memory and personality may be persistent. Disturbances of frontal lobe and limbic system function once initiated may continue to evolve.

Moreover once the patient reaches the late 60's and the 70's, apparent progression of neurological changes in memory and other cognitive functions may occur related to the combined effects of the previous acquired lesions of general paresis and the effects of even mild Alzheimer's disease. A double hit has occurred.

The following case provides an example of a patient whose initial symptoms related primarily to a severe alteration in personality function and social interactions .Features of Parkinson" disease were apparent on her examination. Diagnosis was uncertain but diffuse Lewy body dementia should be considered.

Case 30-6: This 60-year old, right handed separated white housewife, residing in a nursing home, was referred for evaluation of problems in walking, progressive behavioral change and memory disturbance. Six years previously at age 54, a change in behavior was first noted by her family. She began to accumulate papers about the house. She would leave the shades down all day, and expressed fears that people would break into her house. As a result, she became isolated from her neighbors and friends. Shortly there after, she made repeated phone calls to the local police and it was apparent that she was confused. After investigation, the police had to break into the house and take her to an emergency room. In the emergency room she was described as confused and frightened. Paranoid ideation was prominent with considerable self-referral ideation. Thought process was described as tangential, with considerable perseveration. There was poor insight and judgment was impaired. She was confused as to time and place and she could recall two of three objects in 5 minutes. She had great difficulty with serial sevens, often losing track of the number to be subtracted. Judgment and insight were poor. She would read a book by rapidly turning the pages, but then had little recall of what she had read. With treatment with haloperidol, lability of mood and paranoia decreased. A CT Scan demonstrated "mild cortical atrophy". The patient was then transferred to a nursing home with a diagnosis of Alzheimer's Disease. In retrospect, a gait problem had also been present in January 1984, about the time that her symptoms had begun, and prior to the use of haloperidol.. The patient was walking flexed with small steps. These gait problems progressed so that she was unable to stand up from a chair and was unable to walk. She had become fearful of walking.

Family History - Indicated parents died at ages 70-80 years, without neurological disease. A sibling was age 79 without neurological disease.

Neurological examination:

1.*General:* A thin female appearing older than her stated age. She sat in a wheelchair with little facial expression and with little body movement. She was passive in the interview situation -allowing her husband to provide many answers.

2.*Mental Status:* She was oriented to the year but when requested to provide the month and day, she answered "it is the beginning of school time". As regards the location, she gave the name of the town where she formerly lived but could not name the town where the nursing home was located. She did name the nursing home and then said "its a jazzy place with more facilities, most of the people there are nice, some just sit around".

Asked to describe herself, she said, "I am nothing, I can't even take care of my child". She was, however, able to provide the name of her only daughter, now grown, and was able to indicate that the daughter had been born in 1945 in Philadelphia (all of which the husband verified as correct).

Asked to indicate her own birthplace and birth date, she indicated she herself had been born at home in Fitchburg in 1925 and then added, "I imagine everything has been tossed out there". When I asked "what had been tossed out?", she provided a tangential answer, "I do not know you" and then rambled on to a conversation topic about her husband's trip to Turkey on a "Fulbright" - some time in 1960 or 1970.

Delayed recall even with multiple choice assistance was zero out of five in five minutes. For serial seven subtractions, 100 - 7 "might equal 86 or might equal 55". She could name 3 out of 5 objects, could do repetitions, could write her name but not her address and refused to draw a house (? unwilling, ? unable).

3. *Cranial Nerves:* Intact except for a tremor of the closed eyelids and a positive glabellar sign. There was a lack of facial expression.

4. *Motor System*: Strength was difficult to assess, but appeared intact when maximal effort was made. Significant akinesia and bradykinesia were present. There was cogwheel rigidity of minor degree at wrist and elbow. There was variable resistance at hip and knee, which had primarily the character of frontal lobe type "Gegenhalten".
The patient had to be assisted to the standing position from her wheelchair. In the standing position, initially, her feet appeared to be stuck to the floor, as in a magnetic foot syndrome. Eventually, she was able to take small shuffling steps, as assistance was provided by holding her outstretched hands lightly. If unsupported, she tended to fall backwards - whether standing or walking.
 5. *Reflexes*: Deep tendon reflexes were physiologic at 2+ except for Achilles - 1+. Plantar responses were equivocal. There was marked release of the grasp reflex.
 5. *Sensory system*: Pain and vibration were intact. Position sense could not be tested.
- Clinical diagnosis:** Lewy body dementia , or a variant of frontal dementia.

Laboratory data:

1. *Metabolic surveys* were not remarkable in terms of electrolytes, BUN, creatinine, glucose, hepatic functions, vitamin B12, folate levels and thyroid functions.
2. Routine serum serological test and FTA absorption for syphilis were negative.
3. *Sedimentation rate* was moderately increased to 53 mm/hr. *Alkaline phosphatase* was elevated to 272 and bone scan suggested possible Paget's Disease.
4. *EEG* demonstrated a slow dominant awake activity of 6-7 Hz (compared to normal alpha rhythm of 8-13 Hz). In addition, rhythmic bilateral delta slow wave were present, most prominent in the frontal recording areas.
5. *CT Scan*, demonstrated marked cortical atrophy with enlargement of sulci, ventricular system and cisternal spaces.

Subsequent course:

The patient continue a slowly progressive course to the present time. According to her primary physician, she is essentially restricted to bed. She remains, from a medical standpoint, relatively clear of other medical problems and complications - at age 67, 13 years after onset of the disease.

Comment: The diagnosis in this case is uncertain . The patient at age 54 had the onset of a significant change in behavior which resulted in major problems in interpersonal relationships. Initially, she had been able to live by herself in her small seaside community. Eventually, however, the frequent night calls to friend, neighbors, and the police, resulted in her coming to medical attention. Even at that point, the patient's separated husband, who visited her frequently and supported her, appeared unaware of the patient's confusion and memory deficit. The husband had considerable difficulty appreciating the degree of disability. Such a pattern is not unusual.

In contrast to the previous case histories of this chapter, the memory problems were far beyond the selective involvement of recent memory seen in Wernicke's or hippocampal lesions. Moreover, a more diffuse involvement of other cognitive functions was present. As the disease progresses, motor aspects become prominent, indicating the effects of involvement of frontal and premotor areas. Mild "Parkinsonian" features may appear, due to either the medications employed (neuroleptic agents such as pheno thiazides, haloperidol, etc.) or to alterations in the frontal premotor basal, nuclei circuits or to loss of neurons, at the level of S. nigra or basal nuclei. Note however that the gait problems occurred prior to the use of haloperidol. The CT scan did not demonstrate the focal atrophy seen in frontotemporal dementia .Therefore the most likely diagnosis might be diffuse Lewy body dementia since personality changes were most prominent at onset, and Parkinsonian features developed early in the disease course. Contrast this case to the Alzheimer disease patient of case 30-4 in which the initial problems were restricted to changes in memory.

When seen at age 60 this patient was clearly late in her disease course. As indicated, remedial causes of the syndrome of progressive dementia must be ruled out. The effects of medication must be considered. Moreover, however, any masking depression should be treated. At this point in time, no specific therapy to reverse the progressive course of the disease is known.

Case 30-7: This 74-year-old right-handed widow presented to the emergency room at St Vincent hospital on 2-19-02 with an 8-10 week history of worsening memory problems. In December 2001, accompanied by her boyfriend she made her annual trip to Florida. Although she had been in her usual state of independent living prior to her departure, she was found to have serious problems with

memory on arrival. She was unaware as to where she was. In a telephone conversation with her daughter, “she was talking nonsense”. During the next 2 months, memory and word finding continued to deteriorate. She was taken to the emergency room of the local hospital in Florida where a CT scan without contrast on 02/07/02 demonstrated mild cortical atrophy but no acute process. Her son drove to Florida and found that her memory was poor and her conversation did not make sense. “My husband is in the service: my mother died last year.” However she could play cards with her grand daughter. Her gait was slow and stooped. She had urinary incontinence on her way to the bathroom.

She had no history of alcoholism and took various vitamins and herbs.

Family history: her brother had died of a brain tumor of unknown type.

Neurologic examination: The positive findings were the following:

1. *Mental status:* The patient was awake and alert. Overall Mini-Mental Status Score was 19/30. The major problems were in orientation and in delayed recall. She was able to indicate that she was in a hospital in Massachusetts. And the date was February. She registered 3 objects but could recall any in 3 minutes. She was however able to read, name objects, follow instructions, spell “world” backwards and copy a figure. She was unable to draw a clock with the hands set at 11:10.

2. *Cranial nerves:* intact

3. *Motor system:* Although strength and tone were normal, her gait was broad-based and shuffling.

4. *Reflexes:* Patellar and Achilles reflexes were absent but plantar responses were flexor.

5. *Sensory system:* Intact.

Clinical diagnosis: 1) Subacute dementia: etiology uncertain possibly of Alzheimer’s or Lewy body type. Various entities such as chronic subdurals, tumor etc to be ruled out 2) Peripheral neuropathy, most likely etiology at this age diabetes mellitus.

Laboratory data:

1. *Basic CBC and chemistries:* Normal except for an elevated fasting glucose.

2. *CT scan (Fig 30-10):* An enhancing 2.75 cm tumor with a necrotic center was present in the thalamus at the level of the upper third ventricle. There was bilateral involvement of the anterior and medial thalamus but with no involvement of the posterior thalamus or hypothalamus. The study suggested a lymphoma or glioblastoma

Subsequent course *Stereotaxic biopsy of the right thalamus:* Frozen section raised the question of a lymphoma or glioblastoma but special immunological stains were consistent with a glioblastoma. Necrosis and endothelial hyperplasia were present. The patient was treated with dexamethasone and radiotherapy with improvement in gait.

Comment: This patient presents an unusual cause of a progressive alteration in memory. As indicated earlier in this chapter those patients with Wernicke’s encephalopathy who progress to the Korsakoff syndrome had persistent pathology in the medial and anterior thalamus with sparing of the posterior thalamus. In this case the pathology was a rapidly progressive glioblastoma multiforme. As discussed above, an occasional patients, glioblastomas may also produce dementia and a change in personality by infiltrating the prefrontal areas and corpus callosum. Occasionally a patient with a more diffuse neoplasm gliomatosis cerebri may also present with a similar syndrome of dementia which may mimic Alzheimer’s disease. These are however rare causes compared to the more frequent degenerative disorders.